




- **Reasons Adults Seek Orthodontic Treatment**

Reasons Adults Seek Orthodontic Treatment Overcoming Hesitations About Braces Later in Life Clear Aligners for Subtle Tooth Movement Comparing Ceramic Brackets With Other Invisible Options Balancing Cosmetic Goals and Functional Needs Social Changes That Encourage Adult Orthodontics Handling Orthodontic Care Alongside Busy Schedules Managing Discomfort and Adjusting to Lifestyle Shifts Case Studies Highlighting Adult Smile Transformations Psychological Benefits of Aligned Teeth in Adulthood Minimizing Visibility of Orthodontic Appliances Key Questions Adults Often Ask About Treatment

- **How Orthodontics Connects With Periodontal Health**

How Orthodontics Connects With Periodontal Health Coordinating Orthodontic Work With Restorative Dentistry The Role of Oral Surgery in Complex Alignment Cases Importance of Joint Consultation for Comprehensive Outcomes Leveraging Data Sharing Between Dental Specialties Collaborative Approaches to Pediatric Growth Management Integrating Prosthodontics for Full Mouth Rehabilitation Teamwork for Managing Tongue Thrust and Speech Issues Streamlining Communication Among Healthcare Providers Shared Planning for Improved Patient Experiences Post Surgical Follow Ups With Multiple Specialists Building a Unified Strategy for Long Term Stability

- **About Us**



Case Studies Highlighting Adult Smile Transformations

****Desire for Improved Aesthetics**:** Many adults seek orthodontic treatment to enhance the appearance of their smile, addressing concerns such as crooked teeth, gaps, or overbites that may have persisted from childhood or developed due to various life factors.

****Desire for Improved Aesthetics**:** Many adults seek orthodontic treatment to enhance the appearance of their smile, addressing concerns such as crooked teeth, gaps, or overbites that may have persisted from childhood or developed due to various life factors.

Certainly, let's delve into a heartening case study that beautifully illustrates how early orthodontic intervention can lay the groundwork for significant transformations, both aesthetically and functionally, as one transitions from childhood to confident adulthood.

Case Study: Emily's Journey to Confidence

Emily's story is one of transformation—a testament to the power of timely orthodontic care in shaping not just smiles, but lives. Orthodontists specialize in correcting dental irregularities in kids **Youth orthodontic correction** pediatrics. Born with a combination of crossbite and crowding, Emily's early dental challenges were evident even in her toddler years. Her parents, noticing her difficulty in chewing properly and her hesitation to smile widely, sought the counsel of an orthodontist when she was just seven years old. This decision would prove pivotal in setting Emily on a path toward not

just corrected teeth alignment but also enhanced self-esteem and functionality.

At this young age, Emily began what we refer to as Phase One treatment, aimed at addressing specific developmental issues before all permanent teeth had erupted. The treatment plan involved the use of a palatal expander to widen her upper jaw, correcting the crossbite that was impacting her bite and speech. Simultaneously, some selective tooth extraction was considered to create space for proper alignment of incoming permanent teeth—a procedure often referred to as "creating room." These interventions were carefully designed not only to address immediate functional concerns but also to set the stage for a harmonious bite and facial aesthetics as she grew.

The effects of this early intervention were profound. By the time Emily reached her teenage years, she had already experienced significant improvements in her bite function—chewing became easier, speaking clearer, and there was a noticeable enhancement in her facial symmetry that bolstered her confidence during those formative years. More importantly, having addressed the foundational issues early on meant that when it came time for Phase Two treatment—typically involving braces or clear aligners—to fine-tune her smile and achieve optimal aesthetic outcomes; the journey was smoother and often shorter than it might have been otherwise.

In Emily's case, by adolescence, she required only a relatively short period with braces to perfect her smile alignment and address any minor residual issues. The result? A radiant smile that reflected both health and beauty—straight teeth aligned beautifully with her facial features, contributing immensely to her newfound confidence. As she transitioned into adulthood, Emily marveled at how this early investment in her dental health had ripple effects far beyond mere aesthetics; it influenced how she interacted with the world around her—more socially engaged, professionally assertive, and unapologetically herself.

Emily's journey exemplifies how early orthodontic intervention can act as a catalyst for broader life changes. It underscores the value of proactive care in not just correcting dental anomalies but also fostering personal growth and self-assuredness. For many like Emily, such interventions are not merely about achieving a perfect smile; they're about unlocking potential—a confident start that carries through into adulthood.

****Boosting Self-Confidence**:**
Orthodontic treatment can significantly improve an adult's self-esteem and confidence by correcting dental imperfections, leading to a more positive self-image and better social interactions.

—

- ****Desire for Improved Aesthetics****: Many adults seek orthodontic treatment to enhance the appearance of their smile, addressing concerns such as crooked teeth, gaps, or overbites that may have persisted from childhood or developed due to various life factors.
- ****Boosting Self-Confidence****: Orthodontic treatment can significantly improve an adult's self-esteem and confidence by correcting dental imperfections, leading to a more positive self-image and better social interactions.
- ****Enhancing Oral Health****: Proper alignment of teeth through orthodontic treatment can improve oral hygiene by making it easier to clean teeth effectively, thereby reducing the risk of cavities and gum disease that may have been challenging to manage in misaligned dentitions.
- ****Addressing Chronic Dental Issues****: Adults may seek orthodontics to resolve long-standing dental problems such as bite issues (overbites, underbites, crossbites) that can lead to jaw pain, headaches, and digestive difficulties if left untreated.
- ****Correcting Speech Impediments****: Misaligned teeth or jaw structures can contribute to speech difficulties; orthodontic treatment can correct these issues, improving articulation and overall communication skills.
- ****Preventive Measures Against Tooth Wear****: Properly aligned teeth are less prone to excessive wear and tear; adults may pursue orthodontic treatment to prevent premature tooth degradation and associated costs of restorative dentistry.
- ****Facilitating Better Chewing Efficiency****: Orthodontic treatment can improve bite function and alignment, allowing for more efficient chewing which is crucial for digestion and overall nutritional health in adulthood.

The journey of a smile, especially one transformed through the lens of early orthodontics, is a testament to how foundational interventions can shape long-term dental health and aesthetics. The role of early orthodontic treatment in influencing adult dental outcomes is not just a theoretical concept but a reality echoed in numerous case studies that vividly illustrate the profound impact of timely intervention. This essay delves into the significance of these early steps, highlighting how they lay the groundwork for smoother

transitions into adulthood with healthier, more confident smiles.

The Foundation Laid in Childhood

Orthodontic issues often present themselves during childhood, a critical period when the jaw and teeth are still developing. Early diagnosis allows orthodontists to address problems such as overcrowding, misalignment, and improper bites before they become more complicated. The American Association of Orthodontists recommends that children have their first orthodontic check-up no later than age seven. This timing is crucial because it allows for the monitoring of growth patterns and development, enabling professionals to intervene at the optimal moment when bones are still malleable and treatments can be more effective.

Evidence from Case Studies

Take, for instance, the case of Sarah, whose story encapsulates the transformative power of early orthodontic care. Diagnosed with severe overcrowding and a crossbite at eight years old, Sarah began her treatment journey with a palatal expander and braces tailored to guide her permanent teeth into proper alignment. By addressing these issues during her formative years, not only were future complications mitigated—such as potential jaw surgery or tooth extraction—but also laid the groundwork for an aligned bite and esthetically pleasing smile by adulthood. Years later, Sarah's follow-up revealed not just straight teeth but also improved facial symmetry and enhanced self-esteem—a direct outcome of foundational work initiated in childhood.

Another compelling case involves Michael, who faced significant skeletal discrepancies requiring comprehensive treatment that went beyond mere braces. Early intervention allowed his orthodontist to employ growth-modifying appliances that guided his jaw development during adolescence. The result was a harmonious relationship between his upper and lower jaws by adulthood, avoiding more invasive surgical options that might have been necessary had treatment been delayed until later in life. Michael's story illustrates how strategic early management preserves natural tooth structure and minimizes long-term dental health risks while achieving excellent esthetic outcomes.

Long-Term Benefits Beyond Aesthetics

The benefits extend far beyond mere cosmetic improvements; early orthodontic care contributes significantly to long-term oral health. Properly aligned teeth reduce the risk of gum disease by ensuring easier cleaning habits and decreasing areas where plaque can accumulate—a critical factor in maintaining oral health throughout one's life. Moreover, correcting bite issues early on mitigates risks associated with temporomandibular joint (TMJ) disorders and excessive wear on tooth enamel due to improper force distribution during biting and chewing.


Conclusion: An Investment in Future Wellbeing

The cases highlighted underscore an undeniable truth: investing in early orthodontic care is an investment in one's long-term dental health and appearance. By addressing issues before they escalate into more serious conditions requiring extensive—often costly—interventions later in life, individuals like Sarah and Michael exemplify what can be achieved through proactive care initiated during childhood or adolescence. These stories resonate deeply within the dental community as powerful testimonials advocating for routine pediatric orthodontic evaluations—not

More about us:

Social Media:

Facebook About Us:



****Enhancing Oral Health**:**

Proper alignment of teeth through orthodontic treatment can improve oral hygiene by making it easier to clean teeth effectively, thereby reducing the risk of cavities and gum disease that may have been challenging to manage in misaligned dentitions.

Maintaining the radiant smiles achieved through orthodontic treatments is a journey that many adults embark on, filled with unique challenges that can test the resilience of both teeth and gum tissues over time. The transformative power of orthodontics, reshaping not just the alignment but also the confidence of individuals, often comes with a set of ongoing responsibilities to ensure these results endure for decades. Among these challenges, tooth wear, gum recession, and relapse stand out as common adversaries. Let's delve into these issues through illustrative case studies that highlight effective strategies for sustaining those beautiful smiles.

Case Study 1: The Battle Against Tooth Wear

Meet Sarah, a vibrant 45-year-old who had her braces removed at 20. Initially thrilled with her straight smile, she began noticing significant tooth wear after two decades. The culprit? Her habitual grinding of teeth during stress—a condition known as bruxism—and her tendency to gnaw on pen caps and ice cubes. Recognizing the need for intervention, Sarah turned to a customized night guard to protect her teeth during sleep and consciously altered her habits. Moreover, incorporating silica-rich foods into her diet helped remineralize her enamel. Regular dental check-ups allowed for early detection and treatment of any developing wear patterns, ensuring Sarah's smile remained bright and healthy well into her fifties.

Case Study 2: Combating Gum Recession with Proactive Care

John's story is one of vigilance against gum recession, which he faced ten years post-orthodontic treatment. Despite meticulous brushing and flossing, John noticed his gums beginning to pull away from his teeth slightly. Understanding that gum health is pivotal in preserving the integrity of orthodontic work, John ramped up his oral hygiene routine by

using a soft-bristled toothbrush and floss threaders to reach beneath his gums without causing damage. He also adopted an antibacterial mouthwash regimen advised by his periodontist. Engaging in regular professional cleanings and demonstrating diligence in monitoring gum health allowed John to maintain a full smile free from the more severe consequences of recession over time.

Case Study 3: Relapse Prevention Through Commitment

Lisa's journey illustrates the perennial challenge of relapse after orthodontic treatment. Having enjoyed straightened teeth since her teenage years, Lisa found herself facing a slight shift back toward crowding in her thirties due to jaw changes associated with aging and bone resorption. Armed with clear aligners recommended by her orthodontist as an effective tool for maintenance rather than just correction, Lisa committed to wearing them part-time as prescribed—an approach that subtly guided her teeth back into ideal alignment without the bulkiness of traditional braces. This proactive engagement with aligner technology helped Lisa prevent relapse effectively while allowing for flexibility in her lifestyle choices regarding visibility during social events or professional settings.

Through these case studies, we see that maintaining the results of childhood orthodontic treatments requires an ongoing commitment to oral health practices tailored to individual needs. To combat tooth wear effectively, it's crucial to address habits like bruxism while employing protective measures such as night guards and dietary adjustments rich in minerals essential for enamel strength. For gum recession prevention, consistent oral hygiene practices combined with professional periodontal care form the cornerstone strategy alongside mindful brushing techniques that protect delicate gum tissue. Lastly, embracing modern tools like clear aligners for relapse prevention unders

****Addressing Chronic Dental Issues**:** Adults may seek orthodontics to resolve long-standing dental problems such as bite issues (overbites, underbites, crossbites) that can lead to jaw pain, headaches, and digestive difficulties if left untreated.

Certainly, the journey of smile transformations in adults has evolved dramatically over the years, significantly thanks to the integration of advanced technologies that not only enhance outcomes but also personalize treatment plans to meet the unique needs of

each individual. In recent times, clear aligners and digital imaging have emerged as cornerstone innovations, revolutionizing how orthodontists approach adult smile makeovers, often building upon foundational work initiated during childhood or adolescence.

Let's delve into how these technologies interweave with earlier orthodontic treatments to achieve remarkable results in adult patients.

The Role of Clear Aligners

Clear aligners, like Invisalign, have become a beacon for adults seeking discreet yet effective orthodontic treatment. Unlike traditional metal braces, which can be conspicuous and sometimes uncomfortable, clear aligners offer a nearly invisible solution that appeals immensely to professionals and individuals conscious about their appearance. These aligners are tailored through advanced 3D imaging technology, creating a series of custom-made trays that gradually shift teeth into desired positions without the need for wires or brackets.

Consider a case where an individual had undergone braces in their teenage years but experienced relapse post-treatment due to factors like tooth wear or gum changes with age. Years later, clear aligners provided an elegant solution. By leveraging digital scans and models derived from initial childhood treatments alongside current oral conditions, orthodontists could precisely map out a new trajectory for tooth alignment. The patient enjoyed a smooth transition back to straighter teeth without the stigma or discomfort associated with traditional braces—a testament to how earlier work can seamlessly integrate with cutting-edge technology for optimal outcomes.

Digital Imaging: A Game Changer

Digital imaging stands at the forefront of this transformation, providing unparalleled precision in diagnosis and treatment planning. Advanced systems like Cone Beam Computed Tomography (CBCT) offer three-dimensional views of dental structures and surrounding bone anatomy, allowing orthodontists to visualize complex cases in detail never before possible. This capability is crucial when considering adults who may have underlying issues from past treatments or developmental anomalies that require nuanced understanding and correction.

For instance, imagine an adult who had partial orthodontic treatment as a teenager but always felt self-conscious about a slightly crooked front tooth or an uneven bite that wasn't fully addressed at the time. With digital imaging technology, their current orthodontist can overlay old X-rays with new 3D scans to assess growth patterns, bone density, and exact tooth positioning in relation to existing dental work from years prior. This comprehensive view guides the creation of a highly personalized treatment plan using clear aligners or other modern techniques tailored specifically to address both historical issues and current aesthetic goals. The result? A harmonious smile transformation that respects and builds on past efforts rather than starting from scratch.

Building Upon Foundations

The synergy between clear aligners and digital imaging exemplifies how modern orthodontics doesn't just fix immediate concerns; it thoughtfully integrates previous interventions into future solutions. This approach allows for more predictable outcomes while minimizing unnecessary procedures—a win-win for patient comfort and satisfaction. Adults benefiting from these technologies often experience smoother transitions through

their treatment phases because every step is informed by both historical data and cutting-edge diagnostics.

This evolution isn't merely about aesthetics; it's about enhancing overall oral health and function while addressing psychological aspects tied to smiling confidence—factors particularly significant for adults

****Correcting Speech**

Impediments:** Misaligned teeth or jaw structures can contribute to speech difficulties; orthodontic treatment can correct these issues, improving articulation

and overall communication skills.

The transformative journey of a smile, especially in adulthood, isn't merely about straightening teeth or perfecting dental alignment; it's a profound psychosocial metamorphosis that touches the very core of an individual's self-perception and social interactions. When we delve into the **Psychosocial Impact of Smile Transformations**, particularly through the lens of orthodontic treatments that often have their roots in earlier life experiences, we uncover a tapestry woven with threads of psychological benefit, enhanced self-esteem, and richer social engagements. This exploration is enriched by real-life case studies that illuminate these often-intangible yet deeply significant changes.

Let's consider Jane's story, a 35-year-old graphic designer whose childhood was marred by bullying due to her crooked teeth. The emotional scars lingered well into adulthood, affecting her confidence and her willingness to engage socially. After years of contemplation and encouragement from friends who noticed her discomfort, Jane decided to embark on an orthodontic journey. The transformation wasn't just physical; it was a rebirth of her self-image. As her teeth aligned and her smile brightened, Jane reported a remarkable shift in how she perceived herself. She began to feel more approachable and confident in both professional and personal settings. Her case exemplifies how orthodontic interventions can serve as a catalyst for improved self-esteem, allowing individuals to shed years of insecurities and step into their lives with renewed vigor.

Similarly, Mark's experience illustrates how smile transformations can reshape social interactions fundamentally. A successful businessman in his late thirties, Mark had always felt his misaligned teeth were barriers in both networking events and casual meetings alike. His decision to undergo Invisalign treatment was largely driven by a desire to connect more authentically with others without the subconscious anxiety of his smile being a point of distraction or judgment. Post-treatment, Mark noticed not only compliments on his new smile but also an ease in forming connections—whether it was sealing business deals or simply enjoying conversations at social gatherings without the shadow of self-consciousness looming over him. His story underscores how orthodontic improvements can act as an ice-breaker, facilitating smoother social interactions and deeper interpersonal connections.

These narratives echo broader psychological findings suggesting that facial aesthetics significantly impact one's self-concept and social behavior. When adults undertake orthodontic treatments initiated or influenced by earlier interventions—perhaps inspired by childhood experiences or long-held desires—the outcomes are multifaceted. Beyond physical changes lie deeper psychological shifts: increased confidence, reduced social anxiety, and an overall enhancement in life satisfaction. Studies have shown that individuals who undergo such transformations often report higher levels of happiness and better mental health outcomes as they navigate their personal and professional landscapes with newfound assurance.

Moreover, these transformations don't occur in isolation; they ripple through relationships and communities. Friends notice the change first—in the way someone engages more freely in conversations or smiles openly without reserve—and this recognition fosters deeper bonds. Colleagues may perceive them as more approachable leaders or team members who contribute with greater openness and enthusiasm. In essence, the psychosocial impact extends beyond individual psychology to influence interpersonal dynamics within broader social contexts positively.

In conclusion, exploring the psychosocial impact through case studies like Jane's and Mark's reveals a compelling narrative: adult orthodontic treatments initiate not just dental corrections but profound psychological shifts leading to enhanced

****Preventive Measures**

Against Tooth Wear:**

Properly aligned teeth are less prone to excessive wear and tear; adults may pursue orthodontic treatment to prevent premature tooth degradation and associated

costs of restorative dentistry.

Customizing treatment plans for adults who have a history of childhood orthodontic interventions presents a unique tapestry of considerations, intricately woven from the threads of past treatments, current dental health, and personal aesthetic desires. This approach is pivotal in achieving not just functional improvements but also enhancing the overall quality of life through optimized oral aesthetics. To illustrate the nuanced journey toward these transformative outcomes, let's delve into several case studies that highlight personalized strategies leading to exceptional results.

Case Study 1: The Patient with Previous Fixed Appliance Treatment

Background: A 35-year-old professional, let's call her Sarah, had undergone traditional metal braces during her teenage years to correct a significant overbite. While effective at the time, over the years, subtle shifts in her jaw alignment and tooth positioning became apparent, impacting both function and aesthetics.

Considerations & Approach: Recognizing that Sarah's previous orthodontic work laid a foundational framework but required refinement, the treatment plan incorporated digital imaging to analyze current tooth positions and jaw relations accurately. Given her professional lifestyle and desire for discreet solutions, clear aligner therapy was recommended alongside minor adjustments to existing restorations to ensure harmony with her newly aligned teeth. This personalized strategy aimed at refining rather than completely overturning her previous treatment outcomes showcased respect for past

interventions while focusing on current needs.

Outcome: After about six months of customized aligner therapy complemented by periodic adjustments, Sarah achieved a balanced smile that enhanced her confidence significantly without disrupting her busy schedule or compromising the integrity of earlier treatments.

Case Study 2: The Adult with Early Orthodontic Intervention Challenges

Background: Meet David, a 42-year-old entrepreneur whose childhood orthodontic treatment involved a combination of expanders and braces to address crossbites and crowding. Despite initial success, he experienced some relapse due to adolescence-induced growth patterns not fully accounted for at the time. Now an adult seeking a more permanent solution, David faced challenges in achieving stability post-treatment due to bone density variations from his younger years.

Considerations & Approach: Here, an interdisciplinary approach was critical; involving periodontists for bone grafting where necessary and utilizing advanced implant-supported options for stability became key considerations alongside traditional orthodontics. Personalized digital planning allowed for precise simulations of tooth movement considering David's unique bone structure and healing capacity—a far cry from one-size-fits-all methods often seen in younger patients.

Outcome: Through this tailored approach combining modern technology with expert interdisciplinary care, David not only achieved a stable and aesthetic outcome but also appreciated how his earlier interventions were reimagined for lasting results rather than

mere correction.

Case Study 3: Navigating Complexities Post Childhood Orthodontics

Background: Consider Emma, now 37 years old, who had undergone comprehensive orthodontic treatment as a child but later experienced gum recession and uneven tooth wear due to long-term habits like bruxism (teeth grinding) exacerbated by poorly fitting restorations post-orthodontics. Her goal was not just cosmetic improvement but addressing functional issues affecting her bite and comfort while eating and speaking.

Considerations & Approach: For Emma's scenario, customization meant integrating periodontal therapy with orthodontic adjustments tailored to address both her bite mechanics and aesthetic concerns simultaneously. Utilizing minimally invasive techniques like Invisalign® allowed for flexibility

****Facilitating Better Chewing Efficiency** Orthodontic**

treatment can improve bite function and alignment, allowing for more efficient chewing which is crucial for digestion and overall nutritional health in adulthood.

When diving into the realm of adult smile transformations, particularly focusing on those who have a history of childhood orthodontic treatment, we find a treasure trove of insights that can profoundly influence clinical practice. These insights, gleaned from various case studies, highlight not just the technical aspects of orthodontic interventions but also the intricate interplay between psychological, social, and physiological factors that contribute to lasting transformations. Let's unpack these key takeaways to distill best practices for clinicians aiming to guide patients through successful smiles that last a lifetime.

1. Holistic Patient Assessment: Beyond Teeth Alignment

Firstly, one compelling lesson from these case studies is the paramount importance of holistic patient assessment. It's no longer sufficient to focus solely on tooth alignment and occlusion; clinicians must adopt a comprehensive approach that considers the entire oral health picture, including periodontal health, jaw function, and even facial aesthetics. Past orthodontic treatments might have addressed alignment but neglected other critical elements that evolve with age, such as gum recession or changes in jaw structure due to growth or trauma. Understanding this broader context enables more tailored and sustainable treatment plans.

2. Psychosocial Considerations: The Emotional Journey

Another significant insight revolves around the psychosocial dimensions of orthodontic treatment in adults. Unlike children who often undergo orthodontics primarily for functional reasons, adults are frequently seeking improvements for aesthetic and confidence-enhancing purposes. Case studies reveal that addressing the emotional narrative behind each patient's desire for transformation is crucial. Clinicians should foster an empathetic environment where patients feel heard and understood in their aspirations and concerns about their smile's impact on their self-image and social interactions. This empathetic connection can significantly enhance treatment adherence and satisfaction outcomes.

3. Customized Treatment Plans: One Size Does Not Fit All

The case studies underscore the necessity of customized treatment plans—tailored not just to correct current dental issues but also anticipating long-term stability and comfort.

Adult patients often come with complex histories, including previous treatments whose effects may have diminished over time or introduced new challenges like tooth wear or bone density changes. By integrating advanced technologies like 3D imaging with personalized approaches considering lifestyle factors (such as diet and oral hygiene habits), clinicians can devise strategies that are both effective immediately and sustainable over decades.

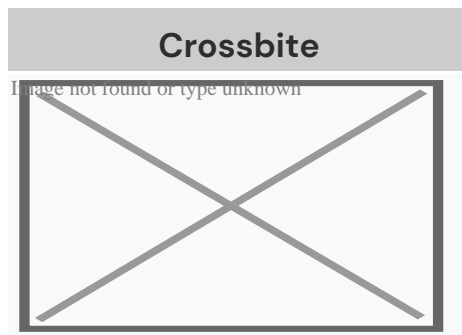
4. Interdisciplinary Collaboration: A Team Approach

Moreover, there's a clear takeaway regarding the advantages of interdisciplinary collaboration in achieving comprehensive results. Cases often involve not just orthodontists but also periodontists, prosthodontists, and cosmetic dentists working in concert to address multifaceted needs—be it gum contouring post-orthodontics or integrating dental implants for missing teeth within a harmonious smile framework. Such teamwork ensures every aspect of a patient's oral health is meticulously considered for optimal outcomes.

5. Long-term Maintenance: Empowering Patients for Lifelong Care

Lastly—and perhaps most importantly—these case studies illuminate the critical importance of educating patients about long-term maintenance strategies post-treatment completion. Adults who've invested time and effort into achieving their dream smiles deserve guidance on how to sustain them—a blend of regular check-ups, personalized oral hygiene regimens tailored to their specific needs post-treatment adjustments (like retainers), and understanding potential future considerations such as aging-related changes in dental structure or function. This proactive approach empowers patients

About crossbite




Unilateral posterior crossbite

Specialty Orthodontics

In dentistry, **crossbite** is a form of malocclusion where a tooth (or teeth) has a more buccal or lingual position (that is, the tooth is either closer to the cheek or to the tongue) than its corresponding antagonist tooth in the upper or lower dental arch. In other words, crossbite is a lateral misalignment of the dental arches.^{[1][2]}

Anterior crossbite

[edit]



Class 1 with anterior crossbite

An anterior crossbite can be referred as negative overjet, and is typical of class III skeletal relations (prognathism).

Primary/mixed dentitions

[edit]

An anterior crossbite in a child with baby teeth or mixed dentition may happen due to either dental misalignment or skeletal misalignment. Dental causes may be due to displacement of one or two teeth, where skeletal causes involve either mandibular hyperplasia, maxillary hypoplasia or combination of both.

Dental crossbite

[edit]

An anterior crossbite due to dental component involves displacement of either maxillary central or lateral incisors lingual to their original erupting positions. This may happen due to delayed eruption of the primary teeth leading to permanent teeth moving lingual to their primary predecessors. This will lead to anterior crossbite where upon biting, upper teeth are behind the lower front teeth and may involve few or all frontal incisors. In this type of crossbite, the maxillary and mandibular proportions are normal to each other and to the cranial base. Another reason that may lead to a dental crossbite is crowding in the maxillary arch. Permanent teeth will tend to erupt lingual to the primary teeth in presence of crowding. Side-effects caused by dental crossbite can be increased recession on the buccal of lower incisors and higher chance of inflammation in the same area. Another term for an anterior crossbite due to dental interferences is *Pseudo Class III Crossbite or Malocclusion*.

Single tooth crossbite

[edit]

Single tooth crossbites can occur due to uneruption of a primary teeth in a timely manner which causes permanent tooth to erupt in a different eruption pattern which is lingual to the primary tooth.^[3] Single tooth crossbites are often fixed by using a

finger-spring based appliances.^{[4][5]} This type of spring can be attached to a removable appliance which is used by patient every day to correct the tooth position.

Skeletal crossbite

[edit]

An anterior crossbite due to skeletal reasons will involve a deficient maxilla and a more hyperplastic or overgrown mandible. People with this type of crossbite will have dental compensation which involves proclined maxillary incisors and retroclined mandibular incisors. A proper diagnosis can be made by having a person bite into their centric relation will show mandibular incisors ahead of the maxillary incisors, which will show the skeletal discrepancy between the two jaws^[6]

Posterior crossbite

[edit]

Bjork defined posterior crossbite as a malocclusion where the buccal cusps of canine, premolar and molar of upper teeth occlude lingually to the buccal cusps of canine, premolar and molar of lower teeth.^[7] Posterior crossbite is often correlated to a narrow maxilla and upper dental arch. A posterior crossbite can be unilateral, bilateral, single-tooth or entire segment crossbite. Posterior crossbite has been reported to occur between 7–23% of the population.^{[8][9]} The most common type of posterior crossbite to occur is the unilateral crossbite which occurs in 80% to 97% of the posterior crossbite cases.^{[10][3]} Posterior crossbites also occur most commonly in primary and mixed dentition. This type of crossbite usually presents with a *functional shift of the mandible towards the side of the crossbite*. Posterior crossbite can occur due to either skeletal, dental or functional abnormalities. One of the common reasons for development of posterior crossbite is the size difference between maxilla and mandible, where maxilla is smaller than mandible^[11] Posterior

crossbite can result due to

- Upper Airway Obstruction where people with "adenoid faces" who have trouble breathing through their nose. They have an open bite malocclusion and present with development of posterior crossbite.^[12]
- Prolong digit or suckling habits which can lead to constriction of maxilla posteriorly^[13]
- Prolong pacifier use (beyond age 4)^[13]

Connections with TMD

[edit]

Unilateral posterior crossbite

[edit]

Unilateral crossbite involves one side of the arch. The most common cause of unilateral crossbite is a narrow maxillary dental arch. This can happen due to habits such as digit sucking, prolonged use of pacifier or upper airway obstruction. Due to the discrepancy between the maxillary and mandibular arch, neuromuscular guidance of the mandible causes mandible to shift towards the side of the crossbite.^[14] This is also known as Functional mandibular shift. This shift can become structural if left untreated for a long time during growth, leading to skeletal asymmetries. Unilateral crossbites can present with following features in a child

- Lower midline deviation^[15] to the crossbite side
- Class 2 Subdivision relationships
- Temporomandibular disorders^[16]

Treatment

[edit]

A child with posterior crossbite should be treated immediately if the child shifts their mandible on closing, which is often seen in a unilateral crossbite as mentioned above. The best age to treat a child with crossbite is in their mixed dentition when their palatal sutures have not fused to each other. Palatal expansion allows more space in an arch to relieve crowding and correct posterior crossbite. The correction can include any type of palatal expanders that will expand the palate which resolves the narrow constriction of the maxilla.^[9] There are several therapies that can be used to correct a posterior crossbite: braces, 'Z' spring or cantilever spring, quad helix, removable plates, clear aligner therapy, or a Delaire mask. The correct therapy should be decided by the orthodontist depending on the type and severity of the crossbite.

One of the keys in diagnosing the anterior crossbite due to skeletal vs dental causes is diagnosing a CR–CO shift in a patient. An adolescent presenting with anterior crossbite may be positioning their mandible forward into centric occlusion (CO) due to the dental interferences. Thus finding their occlusion in centric relation (CR) is key in diagnosis. For anterior crossbite, if their CO matches their CR then the patient truly has a skeletal component to their crossbite. If the CR shows a less severe class 3 malocclusion or teeth not in anterior crossbite, this may mean that their anterior crossbite results due to dental interferences.^[17]

Goal to treat unilateral crossbites should definitely include removal of occlusal interferences and elimination of the functional shift. Treating posterior crossbites early may help prevent the occurrence of Temporomandibular joint pathology^[18]

Unilateral crossbites can also be diagnosed and treated properly by using a Deprogramming splint. This splint has flat occlusal surface which causes the muscles to deprogram themselves and establish new sensory engrams. When the splint is removed, a proper centric relation bite can be diagnosed from the bite^[19]

Self-correction

[edit]

Literature states that very few crossbites tend to self-correct which often justify the treatment approach of correcting these bites as early as possible^[9] Only 0–9% of crossbites self-correct. Lindner et al. reported that 50% of crossbites were corrected in 76 four-year-old children.^[20]

See also

[edit]

- List of palatal expanders
- Palatal expansion
- Malocclusion

References

[edit]

1. [^] "Elsevier: Proffit: Contemporary Orthodontics · Welcome". *www.contemporaryorthodontics.com*. Retrieved 2016-12-11.
2. [^] Borzabadi-Farahani A, Borzabadi-Farahani A, Eslamipour F (October 2009). "Malocclusion and occlusal traits in an urban Iranian population. An epidemiological study of 11- to 14-year-old children". *European Journal of Orthodontics*. **31** (5): 477–84. doi:10.1093/ejo/cjp031. PMID 19477970.
3. [^] **a b** Kutin, George; Hawes, Roland R. (1969-11-01). "Posterior cross-bites in the deciduous and mixed dentitions". *American Journal of Orthodontics*. **56** (5): 491–504. doi:10.1016/0002-9416(69)90210-3. PMID 5261162.
4. [^] Zietsman, S. T.; Visagé, W.; Coetzee, W. J. (2000-11-01). "Palatal finger springs in removable orthodontic appliances--an in vitro study". *South African Dental Journal*. **55** (11): 621–627. ISSN 1029-4864. PMID 12608226.
5. [^] Ulusoy, Ayca Tuba; Bodrumlu, Ebru Hazar (2013-01-01). "Management of anterior dental crossbite with removable appliances". *Contemporary Clinical Dentistry*. **4** (2): 223–226. doi:10.4103/0976-237X.114855. ISSN 0976-237X. PMC 3757887. PMID 24015014.
6. [^] Al-Hummayani, Fadia M. (2017-03-05). "Pseudo Class III malocclusion". *Saudi Medical Journal*. **37** (4): 450–456. doi:10.15537/smj.2016.4.13685. ISSN 0379-5284. PMC 4852025. PMID 27052290.

7. ^ Bjoerk, A.; Krebs, A.; Solow, B. (1964-02-01). "A Method for Epidemiological Registration of Malocclusion". *Acta Odontologica Scandinavica*. **22**: 27–41. doi:10.3109/00016356408993963. ISSN 0001-6357. PMID 14158468.
8. ^ Moyers, Robert E. (1988-01-01). *Handbook of orthodontics*. Year Book Medical Publishers. ISBN 9780815160038.
9. ^ **a b c** Thilander, Birgit; Lennartsson, Bertil (2002-09-01). "A study of children with unilateral posterior crossbite, treated and untreated, in the deciduous dentition--occlusal and skeletal characteristics of significance in predicting the long-term outcome". *Journal of Orofacial Orthopedics*. **63** (5): 371–383. doi:10.1007/s00056-002-0210-6. ISSN 1434-5293. PMID 12297966. S2CID 21857769.
10. ^ Thilander, Birgit; Wahlund, Sonja; Lennartsson, Bertil (1984-01-01). "The effect of early interceptive treatment in children with posterior cross-bite". *The European Journal of Orthodontics*. **6** (1): 25–34. doi:10.1093/ejo/6.1.25. ISSN 0141-5387. PMID 6583062.
11. ^ Allen, David; Rebellato, Joe; Sheats, Rose; Ceron, Ana M. (2003-10-01). "Skeletal and dental contributions to posterior crossbites". *The Angle Orthodontist*. **73** (5): 515–524. ISSN 0003-3219. PMID 14580018.
12. ^ Bresolin, D.; Shapiro, P. A.; Shapiro, G. G.; Chapko, M. K.; Dassel, S. (1983-04-01). "Mouth breathing in allergic children: its relationship to dentofacial development". *American Journal of Orthodontics*. **83** (4): 334–340. doi:10.1016/0002-9416(83)90229-4. ISSN 0002-9416. PMID 6573147.
13. ^ **a b** Ogaard, B.; Larsson, E.; Lindsten, R. (1994-08-01). "The effect of sucking habits, cohort, sex, intercanine arch widths, and breast or bottle feeding on posterior crossbite in Norwegian and Swedish 3-year-old children". *American Journal of Orthodontics and Dentofacial Orthopedics*. **106** (2): 161–166. doi:10.1016/S0889-5406(94)70034-6. ISSN 0889-5406. PMID 8059752.
14. ^ Piancino, Maria Grazia; Kyrkanides, Stephanos (2016-04-18). *Understanding Masticatory Function in Unilateral Crossbites*. John Wiley & Sons. ISBN 9781118971871.
15. ^ Brin, Ilana; Ben-Bassat, Yocheved; Blustein, Yoel; Ehrlich, Jacob; Hochman, Nira; Marmary, Yitzhak; Yaffe, Avinoam (1996-02-01). "Skeletal and functional effects of treatment for unilateral posterior crossbite". *American Journal of Orthodontics and Dentofacial Orthopedics*. **109** (2): 173–179. doi:10.1016/S0889-5406(96)70178-6. PMID 8638566.
16. ^ Pullinger, A. G.; Seligman, D. A.; Gornbein, J. A. (1993-06-01). "A multiple logistic regression analysis of the risk and relative odds of temporomandibular disorders as a function of common occlusal features". *Journal of Dental Research*. **72** (6): 968–979. doi:10.1177/00220345930720061301. ISSN 0022-0345. PMID 8496480. S2CID 25351006.

17. ^ COSTEA, CARMEN MARIA; BADEA, MÎNDRA EUGENIA; VASILACHE, SORIN; MESAROĂfâ€!Ã…Â¾, MICHAELA (2016-01-01). "Effects of CO-CR discrepancy in daily orthodontic treatment planning". *Clujul Medical*. **89** (2): 279–286. doi:10.15386/cjmed-538. ISSN 1222-2119. PMC 4849388. PMID 27152081.
18. ^ Kennedy, David B.; Osepchook, Matthew (2005-09-01). "Unilateral posterior crossbite with mandibular shift: a review". *Journal (Canadian Dental Association)*. **71** (8): 569–573. ISSN 1488-2159. PMID 16202196.
19. ^ Nielsen, H. J.; Bakke, M.; Blixencrone-Møller, T. (1991-12-01). "[Functional and orthodontic treatment of a patient with an open bite craniomandibular disorder]". *Tandlaegebladet*. **95** (18): 877–881. ISSN 0039-9353. PMID 1817382.
20. ^ Lindner, A. (1989-10-01). "Longitudinal study on the effect of early interceptive treatment in 4-year-old children with unilateral cross-bite". *Scandinavian Journal of Dental Research*. **97** (5): 432–438. doi:10.1111/j.1600-0722.1989.tb01457.x. ISSN 0029-845X. PMID 2617141.

External links

[edit]

Classification

- ICD-10: K07.2 D
- ICD-9-CM:
524.27

- v
- t
- e

Orthodontics

Diagnosis

- Bolton analysis
- Cephalometric analysis
- Cephalometry
- Dentition analysis
- Failure of eruption of teeth
- Little's Irregularity Index
- Malocclusion
- Scissor bite
- Standard anatomical position
- Tooth ankylosis
- Tongue thrust
- Overbite
- Overjet
- Open bite
- Crossbite
- Dental crowding
- Dental spacing

Conditions

- Bimaxillary Protrusion
- Prognathism
- Retrognathism
- Maxillary hypoplasia
- Condylar hyperplasia
- Overeruption
- Mouth breathing
- Temporomandibular dysfunction

- ACCO appliance
- Archwire
- Activator appliance
- Braces
- Damon system
- Elastics
- Frankel appliance
- Invisalign
- Lingual arch
- Lip bumper
- Herbst Appliance
- List of orthodontic functional appliances

Appliances

- List of palatal expanders
- Lingual braces
- Headgear
- Orthodontic technology
- Orthodontic spacer
- Palatal lift prosthesis
- Palatal expander
- Quad helix
- Retainer
- SureSmile
- Self-ligating braces
- Splint activator
- Twin Block Appliance

Procedures

- Anchorage (orthodontics)
- Cantilever mechanics
- Fiberotomy
- Interproximal reduction
- Intrusion (orthodontics)
- Molar distalization
- SARPE
- Serial extraction
- Beta-titanium
- Nickel titanium
- Stainless steel

Materials

- TiMolium
- Elgiloy
- Ceramic
- Composite
- Dental elastics

- Edward Angle
- Spencer Atkinson
- Clifford Ballard
- Raymond Begg
- Hans Peter Bimler
- Samir Bishara
- Arne Björk
- Charles B. Bolton
- Holly Broadbent Sr.
- Allan G. Brodie
- Charles J. Burstone
- Peter Buschang
- Calvin Case
- Harold Chapman (Orthodontist)
- David Di Biase
- Jean Delaire
- Terry Dischinger
- William B. Downs
- John Nutting Farrar
- Rolf Frankel
- Sheldon Friel
- Thomas M. Graber
- Charles A. Hawley
- Reed Holdaway
- John Hooper (Orthodontist)
- Joseph Jarabak
- Harold Kesling
- Albert Ketcham
- Juri Kurol
- Craven Kurz
- Benno Lischer
- James A. McNamara
- Birte Melsen
- Robert Moyers
- Hayao Nono

**Notable
contributors**

	<ul style="list-style-type: none"> ○ American Association of Orthodontists ○ American Board of Orthodontics ○ British Orthodontic Society
Organizations	<ul style="list-style-type: none"> ○ Canadian Association of Orthodontists ○ Indian Orthodontic Society ○ Italian Academy of Orthodontic Technology ○ Society for Orthodontic Dental Technology (Germany) ○ American Journal of Orthodontics and Dentofacial Orthopedics
Journals	<ul style="list-style-type: none"> ○ The Angle Orthodontist ○ Journal of Orthodontics
Institution	<ul style="list-style-type: none"> ○ Angle School of Orthodontia

- v
- t
- e

Dental disease involving the jaw

	<ul style="list-style-type: none"> ○ Jaw abnormality ○ malocclusion ○ Orthodontics ○ Gnathitis
General	
Size	<ul style="list-style-type: none"> ○ Micrognathism ○ Maxillary hypoplasia ○ Cherubism
Maxilla and Mandible	<ul style="list-style-type: none"> ○ Congenital epulis ○ Torus mandibularis ○ Torus palatinus

Other

- Jaw and base of cranium
 - Prognathism
 - Retrognathism
- Dental arch
 - Crossbite
 - Overbite
- Temporomandibular joint disorder

Authority control databases: **National**  **Germany**
Edit this at Wikidata

About dental caries

Redirect to:

- Tooth decay
- **From a page move:** This is a redirect from a page that has been moved (renamed). This page was kept as a redirect to avoid breaking links, both internal and external, that may have been made to the old page name.

About dental caries

Redirect to:

- Tooth decay
- **From a page move:** This is a redirect from a page that has been moved (renamed). This page was kept as a redirect to avoid breaking links, both internal and external, that may have been made to the old page name.

Check our other pages :

- [Minimizing Visibility of Orthodontic Appliances](#)

- **Importance of Joint Consultation for Comprehensive Outcomes**
- **Leveraging Data Sharing Between Dental Specialties**

IQDENT – Ortodontska Klinika

Phone : +385953817015

City : Zagreb

State : Hrvatska

Zip : 10000

Address : IQDENT – Ortodontska Klinika

Company Website : <https://iqdent.hr/>

USEFUL LINKS

[Orthodontic treatment can help improve your child's smile](#)

[Orthodontic treatment for children](#)

[Sitemap](#)

[Privacy Policy](#)

[About Us](#)

Follow us