



- **Reasons Adults Seek Orthodontic Treatment**

Reasons Adults Seek Orthodontic Treatment Overcoming Hesitations About Braces Later in Life Clear Aligners for Subtle Tooth Movement Comparing Ceramic Brackets With Other Invisible Options Balancing Cosmetic Goals and Functional Needs Social Changes That Encourage Adult Orthodontics Handling Orthodontic Care Alongside Busy Schedules Managing Discomfort and Adjusting to Lifestyle Shifts Case Studies Highlighting Adult Smile Transformations Psychological Benefits of Aligned Teeth in Adulthood Minimizing Visibility of Orthodontic Appliances Key Questions Adults Often Ask About Treatment

- **How Orthodontics Connects With Periodontal Health**

How Orthodontics Connects With Periodontal Health Coordinating Orthodontic Work With Restorative Dentistry The Role of Oral Surgery in Complex Alignment Cases Importance of Joint Consultation for Comprehensive Outcomes Leveraging Data Sharing Between Dental Specialties Collaborative Approaches to Pediatric Growth Management Integrating Prosthodontics for Full Mouth Rehabilitation Teamwork for Managing Tongue Thrust and Speech Issues Streamlining Communication Among Healthcare Providers Shared Planning for Improved Patient Experiences Post Surgical Follow Ups With Multiple Specialists Building a Unified Strategy for Long Term Stability

- **About Us**



Comparing Ceramic Brackets With Other Invisible Options

****Desire for Improved Aesthetics**:** Many adults seek orthodontic treatment to enhance the appearance of their smile, addressing concerns such as crooked teeth, gaps, or overbites that may have persisted from childhood or developed due to various life factors.

****Desire for Improved Aesthetics**:** Many adults seek orthodontic treatment to enhance the appearance of their smile, addressing concerns such as crooked teeth, gaps, or overbites that may have persisted from childhood or developed due to various life factors.

When we delve into the world of orthodontic treatments, the quest for both functionality and aesthetics becomes paramount, especially for those who are conscious about their appearance during treatment. Among the various options available, ceramic brackets have carved out a niche for themselves, offering a unique blend of performance and subtlety that appeals to many. To truly appreciate these brackets, let's explore their composition, appearance, performance, and particularly highlight how their semi-transparent nature sets them apart from traditional metal braces and other invisible alternatives.

Composition and Appearance:

Ceramic brackets are primarily composed of high-quality ceramic materials that are meticulously designed to withstand the rigors of daily oral functions—chewing, speaking,

and brushing—while maintaining their aesthetic appeal. Unlike their metal counterparts, which are typically made from stainless steel or titanium alloys, ceramic brackets boast a more natural look due to their ability to mimic tooth color. This is achieved through precise engineering and sometimes by adding subtle shades or coatings that help them blend seamlessly with the surrounding teeth. Clear aligners are an option for some kids needing orthodontic care **Early orthodontic intervention** medicine.

The semi-transparent nature of ceramic brackets is one of their most celebrated features. This transparency allows light to pass through them to some extent, giving them an almost ethereal quality that traditional metal braces lack. When attached to teeth, they don't starkly contrast with the enamel; instead, they offer a more harmonious visual integration. This aesthetic advantage is particularly significant for adults and teenagers who might feel self-conscious about visible braces on their smiles. Imagine wearing something that corrects your bite yet allows your smile to shine through almost unobstructed—that's the beauty of ceramic brackets.

Performance:

Despite their appealing aesthetic qualities, it's crucial not to overlook the performance aspect of ceramic brackets. They are crafted to be robust yet gentle on teeth and gums. Ceramic's biocompatibility ensures minimal irritation compared to some metals used in traditional braces. Moreover, advancements in orthodontic technology have led to improvements in the bond strength of ceramic brackets to tooth enamel, ensuring reliable holding power throughout treatment durations which can range from several months to over a year depending on individual needs.

However, there are nuances in performance worth noting. While ceramic brackets excel in aesthetics and comfort against metal alternatives, they sometimes require a bit more

care regarding food choices—hard or sticky foods can potentially damage them more easily than metal ones due to their slightly more delicate structure despite being strong overall. Additionally, while progress has been made in reducing friction (which affects how quickly braces can move teeth), some users might find that ceramic braces could be marginally less efficient than newer invisible aligner options like Invisalign in certain complex cases requiring significant tooth movement or alignment adjustments. Yet for many common orthodontic issues—overcrowding, mild misalignments—they perform admirably well and often provide results comparable to metal braces but with enhanced discretion.

Comparing Ceramic Brackets With Other Invisible Options:

When discussing "invisible" orthodontic options beyond ceramic brackets, one prominent competitor is clear aligners such as Invisalign or ClearCorrect. These systems utilize custom-made plastic trays that fit snugly over your teeth without any metallic components at all—these are arguably even more invisible than ceramic brackets since they're removable for eating and cleaning. However, aligners rely heavily on patient compliance for effectiveness; they must be worn consistently (around

****Boosting Self-Confidence**:**
Orthodontic treatment can
significantly improve an

adult's self-esteem and confidence by correcting dental imperfections, leading to a more positive self-image and better social interactions.

- ****Desire for Improved Aesthetics****: Many adults seek orthodontic treatment to enhance the appearance of their smile, addressing concerns such as crooked teeth, gaps, or overbites that may have persisted from childhood or developed due to various life factors.
- ****Boosting Self-Confidence****: Orthodontic treatment can significantly improve an adult's self-esteem and confidence by correcting dental imperfections, leading to a more positive self-image and better social interactions.
- ****Enhancing Oral Health****: Proper alignment of teeth through orthodontic treatment can improve oral hygiene by making it easier to clean teeth effectively, thereby reducing the risk of cavities and gum disease that may have been challenging to manage in misaligned dentitions.

- ****Addressing Chronic Dental Issues****: Adults may seek orthodontics to resolve long-standing dental problems such as bite issues (overbites, underbites, crossbites) that can lead to jaw pain, headaches, and digestive difficulties if left untreated.
- ****Correcting Speech Impediments****: Misaligned teeth or jaw structures can contribute to speech difficulties; orthodontic treatment can correct these issues, improving articulation and overall communication skills.
- ****Preventive Measures Against Tooth Wear****: Properly aligned teeth are less prone to excessive wear and tear; adults may pursue orthodontic treatment to prevent premature tooth degradation and associated costs of restorative dentistry.
- ****Facilitating Better Chewing Efficiency****: Orthodontic treatment can improve bite function and alignment, allowing for more efficient chewing which is crucial for digestion and overall nutritional health in adulthood.

When it comes to orthodontic treatments, particularly for children and teenagers, the choice between different options can significantly influence both the aesthetic and comfort aspects of undergoing treatment. Among the variety of solutions available, clear aligners, like Invisalign, and ceramic brackets stand out as two popular choices. Let's delve into a comparative analysis focusing on visibility, comfort, treatment effectiveness, and suitability for various orthodontic issues in children, painting a picture of how these two options stack up against each other.

Visibility: One of the most immediate differences between clear aligners and ceramic brackets lies in their visibility. Clear aligners are virtually invisible when worn; they're made from transparent plastic material that fits snugly over your teeth without drawing attention to the fact that you're wearing them. This makes them a favorite among those

who want to maintain a more natural look during treatment. On the other hand, ceramic brackets are significantly more visible than their metal counterparts due to their tooth-colored design. Though less conspicuous than traditional metal braces, they still stand out more than clear aligners do. For kids concerned about appearance during school years or social events, this visibility factor can be quite pivotal.

Comfort: When considering comfort, both clear aligners and ceramic brackets have distinct advantages and potential downsides. Clear aligners are often praised for their comfort because they don't have sharp edges or bulky components that can irritate gums or cheeks—something common with metal braces. They're also removable, allowing for easier cleaning and the ability to enjoy foods without restriction (within reason). Ceramic brackets offer a compromise here; while generally smoother than metal braces and thus less irritating to soft tissues, they can still cause some discomfort initially as teeth adjust to the pressure applied for movement. Additionally, although ceramic brackets are tooth-colored, they might occasionally harbor plaque more easily due to their slightly rougher surface compared to smooth metal or transparent aligners, which could affect oral hygiene comfort over time.

Treatment Effectiveness: Both clear aligners and ceramic brackets are effective at treating a broad spectrum of orthodontic issues—from mild crowding to complex bites—but their effectiveness can vary based on specific cases. Clear aligners excel in situations where tooth movement is primarily about alignment rather than complex structural changes needed by teeth with deep roots or significant misalignments. They work through a series of custom-made trays that gradually shift teeth into place without direct bonding to individual teeth. Ceramic brackets offer versatility in addressing more complex cases as well but require attachment directly to each tooth with bonds that can be less flexible than aligner technology in certain maneuvers. However, advancements in orthodontic techniques mean that ceramic brackets are increasingly used effectively across diverse cases thanks to smaller sizes and improved bonding agents enhancing hold and precision.

Suitability for Various Orthodontic Issues in Children: When it comes to suitability for children specifically, both options have merits but differ slightly in approach and consideration factors. Clear aligners might be preferable for pre-teens concerned about aesthetics or those requiring minimal adjustments since they allow for easier maintenance of oral hygiene—a crucial aspect during growth years when oral health is paramount. However, younger children might find removable aligners challenging given adherence required for effective treatment (typically wearing them 22 hours daily). Ceramic brackets could be favored in cases where extensive adjustments are necessary early on because once bonded, they provide consistent force application ideal

****Enhancing Oral Health**:**

Proper alignment of teeth through orthodontic treatment can improve oral hygiene by making it easier to clean teeth effectively, thereby reducing the risk of

cavities and gum disease that may have been challenging to manage in misaligned dentitions.

When considering orthodontic treatments, the quest for aesthetics and discretion has led to significant advancements, with lingual braces emerging as a sophisticated option that aligns closely with the modern individual's desire for invisible solutions. To truly appreciate the nuances of lingual braces, it's beneficial to contrast them with more conventional options like ceramic brackets, delving into their unique characteristics, advantages, and potential drawbacks.

Lingual Braces: The Hidden Aligner of Teeth

Lingual braces are essentially traditional metal braces but with a clever twist—they're placed on the tongue side of your teeth. This unique positioning makes them virtually invisible from the front, offering a compelling solution for those who prioritize discretion while undergoing orthodontic treatment. The customization involved in fitting lingual braces is meticulous; each bracket and wire are tailored to fit the specific contours of your teeth from this less visible side. This precision not only enhances their invisibility but also ensures effective movement of teeth toward desired alignment and occlusion.

Pros of Lingual Braces

One of the most appealing aspects of lingual braces is their aesthetic advantage. For individuals concerned about the visibility of braces—whether at work, school, or social gatherings—these hidden braces offer peace of mind and confidence. Beyond aesthetics, they function similarly to traditional brackets, capable of addressing a wide range of dental issues including overcrowding, spacing, and complex malocclusions. Additionally, because they're custom-fitted to each patient's mouth, they can be highly effective in achieving precise results.

However, alongside these benefits come certain considerations that potential patients should weigh carefully.

Cons: Speech Difficulties and Cost

Speech interference is perhaps one of the most notable challenges associated with lingual braces. Because they sit on the tongue side of teeth, adjusting to speaking can initially be difficult for many wearers. Sounds such as "s," "z," "t," and "d" might take some practice to articulate clearly again post-installation. While many adapt over time—often within a few weeks—this adjustment period can be frustrating for some patients.

Moreover, cost stands as another significant factor distinguishing lingual braces from other options like ceramic brackets. Due to their complexity in fabrication and installation—a process requiring specialized training and equipment—they tend to be more expensive than both traditional metal and ceramic brackets. This higher cost reflects not only the materials used but also the expertise needed to ensure proper fit and effective treatment outcomes.

Ceramic Brackets: A Comparative Glance

In stark contrast stand ceramic brackets—a popular alternative that strikes a balance between visibility and functionality. These brackets are made from tooth-colored materials that significantly reduce their visibility compared to metal ones but are placed on the front surface of teeth like traditional braces. Ceramic brackets offer a compromise for those seeking less obvious treatment without resorting to entirely invisible options like lingual braces. They generally cause fewer speech difficulties than lingual braces due to their placement but may still attract some notice due to their color contrast against darker teeth or food stains—which can be mitigated by choosing clear or tooth-colored ceramics aligned with one's natural tooth shade as closely as possible.

Ceramic brackets usually come at a lower price point than lingual ones but are still more costly than traditional metal braces due to material costs and craft

****Addressing Chronic Dental Issues**:** Adults may seek orthodontics to resolve long-standing dental problems such as bite issues (overbites,

underbites, crossbites) that can lead to jaw pain, headaches, and digestive difficulties if left untreated.

When we dive into the world of orthodontic treatments, particularly focusing on the nuances of treatment duration and effectiveness between ceramic brackets and other invisible options, it's essential to unpack a variety of factors that influence pediatric patients' outcomes. This exploration not only sheds light on the technical aspects but also considers the broader implications for young patients navigating their orthodontic journeys.

Firstly, let's touch upon **ceramic brackets** themselves. Often hailed as a more aesthetically pleasing option compared to traditional metal brackets, ceramic brackets are made from tooth-colored materials, making them less noticeable on a child's smile. In terms of **treatment duration**, studies suggest that ceramic brackets can be comparable to metal brackets in terms of overall time required to achieve desired results. However, the efficiency can vary based on several factors including the severity of the case and oral habits of the patient. Some pediatric patients might experience slightly longer treatment times with ceramic brackets due to their design, which can sometimes be more delicate than metal counterparts, potentially leading to more adjustments over time.

On the effectiveness front, ceramic brackets have shown promising results, often providing satisfactory alignment with fewer aesthetic concerns for young patients who might be self-conscious about their appearance during treatment. Yet, it's crucial to acknowledge that effectiveness isn't solely dictated by the bracket material but also by how well they are utilized in conjunction with other orthodontic appliances and patient compliance with care instructions—such as maintaining oral hygiene and adhering to dietary restrictions.

When comparing ceramic brackets with other invisible options like **clear aligners (e.g., Invisalign)**, several key distinctions arise. Clear aligners represent a significant leap in aesthetic orthodontics; they are virtually invisible and removable, offering convenience for young patients who might find traditional braces cumbersome during meals or social activities. In terms of **treatment duration**, clear aligners can sometimes offer a quicker path to results for certain types of malocclusions due to their customizable nature and ability to apply precise forces directly where needed without interference from fixed appliances. However, not all cases are suitable for aligner therapy; complex malocclusions might still necessitate traditional braces including ceramic ones for optimal outcomes.

Effectiveness-wise, clear aligners boast high success rates when used appropriately but require meticulous adherence from patients—they need to wear them for at least 20–22 hours daily for effective movement of teeth. Pediatric patients may face challenges here if they tend towards forgetfulness or resistance to wearing appliances consistently. Moreover, since aligners are removable, maintaining proper oral hygiene can be easier compared to fixed braces but also depends heavily on patient discipline and parental support during younger ages.

Considering various influencing factors such as oral habits (thumb-sucking or tongue-thrusting), severity of dental crowding or misalignment, and individual compliance levels paints a comprehensive picture of how both ceramic brackets and invisible options

perform in pediatric populations. It becomes evident that while ceramic brackets offer a balance between aesthetics and traditional efficacy without requiring removal for eating or cleaning (unlike aligners), clear aligners shine in scenarios demanding discretion and flexibility—though at the cost of potential decreased efficacy if not used correctly according to prescribed guidelines.

In conclusion, choosing between ceramic brackets and other invisible treatment options hinges on an intricate interplay of clinical needs specific to each pediatric patient alongside lifestyle considerations unique to families navigating orthodontic care together.

****Correcting Speech**

Impediments:** Misaligned

teeth or jaw structures can

contribute to speech

difficulties; orthodontic

treatment can correct these

issues, improving articulation and overall communication skills.

When it comes to orthodontic treatment, parents often find themselves at a crossroads, weighing the options available for their children's dental alignment needs. Among these choices, ceramic brackets stand out as a popular option, especially when juxtaposed with other "invisible" alternatives like clear aligners and lingual brackets. Let's unpack the financial implications of choosing ceramic brackets against these alternatives, dissecting initial costs, additional expenses that might arise, and how insurance coverage can vary, painting a clearer picture for parents making this crucial decision.

Initial Costs: A Closer Look

Ceramic brackets are often perceived as a middle-ground option between traditional metal braces and the fully invisible aligner systems. Initially, ceramic brackets tend to be more expensive than metal braces due to their aesthetic appeal and the materials used—ceramic offers a tooth-colored option that blends with teeth, which many find desirable. However, they generally fall in line with or slightly above the cost of traditional metal braces when considering the overall treatment duration and frequency of adjustments required.

In contrast, clear aligners like Invisalign are often positioned as premium products due to their convenience and invisibility. While they can be priced higher initially compared to ceramic brackets (especially for complex cases requiring multiple sets of aligners), some parents might view them as an investment in their child's comfort and lifestyle during treatment—no wires to tighten or food restrictions that come with traditional braces. However, it's worth noting that clear aligners may require more frequent purchases as treatment progresses, potentially leading to cumulative costs rivaling those of ceramic or metal braces over time.

Potential Additional Expenses: Beyond the Brace Cost

One critical aspect often overlooked is additional expenses that come hand-in-hand with orthodontic treatments. For ceramic brackets, while they might not require as frequent adjustments as metal braces (thanks to their smooth surface reducing friction), there's still potential for extra costs down the line. One significant consideration here is tooth whitening post-treatment. Ceramic brackets can sometimes stain over time despite their color-matching design intent; hence, some parents opt for professional whitening sessions post-treatment to achieve that sparkling smile everyone desires. These sessions aren't cheap and need factoring into the overall budget.

On the other hand, clear aligners also have associated costs beyond the initial fee—like replacement aligners if lost or damaged (which is quite common given their removable nature) and occasional office visits specifically for fitting new sets as treatment progresses. While these don't directly equate to tooth whitening costs, they contribute significantly to the total expenditure over time.

Insurance Coverage Nuances: Navigating Benefits

Insurance coverage plays a pivotal role in easing—or complicating—the financial burden of orthodontic treatments. Here again, ceramic brackets present an interesting case compared to invisible options like clear aligners. Many dental insurance plans cover a portion of traditional metal brace treatments but may offer less comprehensive coverage for cosmetic options like ceramic brackets or even clearer alternatives like lingual braces (placed behind teeth). Parents should meticulously review their policies regarding what percentages are covered for different types of appliances since this can significantly impact out-of-pocket costs.

Clear aligners often face similar challenges with insurance coverage; while some plans recognize them as legitimate orthodontic treatments worthy of partial reimbursement, others categorize them

****Preventive Measures**

Against Tooth Wear:**

Properly aligned teeth are less prone to excessive wear and tear; adults may pursue

orthodontic treatment to prevent premature tooth degradation and associated costs of restorative dentistry.

When we chat about orthodontic treatments, especially for kids, the focus often shifts to achieving that perfect smile, but it's equally important to consider how these treatments affect comfort and oral hygiene. Let's dive into how ceramic brackets compare with other invisible options like clear aligners and lingual brackets, focusing on their impact on oral comfort during treatment and the ease of maintaining good oral hygiene—a crucial aspect for our younger patients.

Ceramic Brackets: A Balance of Aesthetics and Comfort

Ceramic brackets have made a significant stride in blending with the natural color of teeth, making them a popular choice for those who want a less obvious orthodontic solution. From a comfort standpoint, ceramic brackets are generally well-tolerated. They tend to be smoother than traditional metal brackets, which can reduce the likelihood of irritation to the cheeks and lips—a common complaint with metal appliances. However, they can be more prone to staining if not cleaned properly, which might require kids to be more

vigilant with their oral hygiene routines. In terms of maintaining oral hygiene, while ceramic brackets aren't as shiny and attention-grabbing as some might think, their surface can still accumulate plaque if not brushed diligently around each bracket and the wire. The slightly rougher surface compared to clear aligners might make it a bit harder to keep things spotless, but with regular brushing and flossing techniques tailored for orthodontic wearers, this challenge is manageable.

Clear Aligners: The Invisible Choice

Clear aligners represent a significant leap in cosmetic orthodontics; they're essentially invisible when worn, making them a favorite among teens and adults alike who prioritize discretion. When it comes to comfort during treatment, clear aligners shine—there are no metal parts poking or rubbing against the gums or inner cheeks. This design minimizes irritation significantly. However, maintaining oral hygiene with aligners requires a different approach compared to fixed appliances like brackets. Since aligners need to be removed for eating and brushing, they actually encourage better oral hygiene practices by giving kids full access to all surfaces of their teeth for cleaning. Yet, it's crucial that kids develop a habit of consistently removing and cleaning their aligners along with thorough brushing after meals—these habits are key to preventing decay and gum disease during treatment.

Lingual Brackets: Hidden but Not Without Challenges

Lingual brackets offer another invisible option by attaching to the back side of teeth (the tongue side), making them nearly invisible from the outside. This could be considered the ultimate in discretion for those very conscious about appearance during treatment. Comfort-wise, lingual braces can initially pose a learning curve; speaking and eating might feel awkward at first due to their placement on the tongue side of teeth. Over time though,

most adapt quite well. Regarding oral hygiene, lingual brackets present unique challenges since they're tucked away from easy access. Kids will need special tools or techniques—like interdental brushes designed specifically for lingual braces—to clean effectively around these hidden braces without irritating gums or damaging tooth enamel inadvertently swollen from plaque buildup hidden from sight.

Conclusion: Choosing What Fits Best

In wrapping up this comparison between ceramic brackets and other invisible options like clear aligners and lingual brackets regarding comfort during orthodontic treatment for kids and ease of maintaining oral hygiene—it's clear each choice comes with its own

****Facilitating Better Chewing Efficiency**
: Orthodontic treatment can improve bite function and alignment,**

allowing for more efficient chewing which is crucial for digestion and overall nutritional health in adulthood.

The journey of orthodontic treatment for children, particularly the shift from traditional metal braces to more discreet options like ceramic brackets and other invisible alternatives, represents a significant intersection between dental health and psychological wellbeing. This transformation isn't merely about achieving a straighter smile; it's deeply entwined with the emotional landscape of growing up, where self-esteem and social dynamics play pivotal roles. Let's delve into how different invisible brace options can influence these crucial aspects of a child's development.

Starting with ceramic brackets, often hailed as the "invisible" alternative to metal braces, their impact on self-esteem is notably positive. Made from tooth-colored materials, ceramic brackets blend seamlessly with the natural color of teeth, significantly reducing the visibility of braces. For many children, this subtlety can be a game-changer. Imagine

the confidence boost for a young individual knowing that their orthodontic treatment is working towards a straight smile without drawing unwanted attention or comments. This reduction in visibility can alleviate anxiety about appearance during school years, where social interactions are heavily influenced by peer perceptions. With ceramic brackets, children might feel less self-conscious about smiling widely or participating in photos, fostering an environment where they can engage more freely and positively with their peers.

However, while ceramic brackets offer enhanced aesthetics over traditional metal braces, they're not entirely without drawbacks that could affect psychological comfort. They tend to be more fragile than metal brackets—more susceptible to staining and breaking—and often require closer dental care supervision. For some children, this might introduce additional stress regarding maintenance and potential visits to the orthodontist for repairs, which could momentarily dampen the initial confidence gained from their discreet appearance.

Beyond ceramic brackets, clear aligners like Invisalign have emerged as another formidable contender in the realm of invisible orthodontics. These removable trays offer an even higher level of discretion since they can be taken out for meals and brushing. For adolescents who value independence and want control over their treatment process, clear aligners represent freedom alongside invisibility. The ability to remove aligners can ease concerns about food restrictions common with fixed braces and allows for better oral hygiene practices without the cumbersome task of brushing around wires and brackets. This flexibility might contribute positively to self-esteem by promoting a sense of responsibility and normalcy during treatment—something that resonates deeply with teenagers striving for autonomy.

Yet despite these advantages clear aligners also present unique challenges impacting psychological well-being. The requirement to wear them consistently (typically 22 hours a

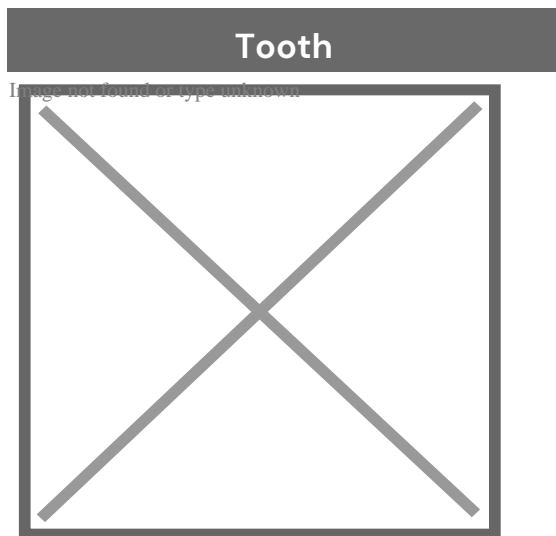
day) demands discipline; missing even a few hours could delay treatment progress. This level of commitment might create stress or feelings of burden for some children, potentially affecting their motivation.

In comparing these invisible options—ceramic brackets versus clear aligners—it becomes evident that while both aim to minimize the visual impact of orthodontic treatment, they cater differently to psychological needs. Ceramic brackets provide a balance between discretion and durability but may come with slight maintenance anxieties. On the other hand, clear aligners offer unprecedented convenience and flexibility, but require discipline and commitment.

Ultimately, the choice between ceramic brackets and clear aligners shouldn't solely rest on

About tooth

This article is about teeth in general. For specifically human teeth, see Human tooth. For other uses, see Tooth (disambiguation).



A chimpanzee displaying his teeth

Details	
Identifiers	
Latin	<i>dens</i>
MeSH	D014070
FMA	12516

Anatomical terminology

[edit on Wikidata]

A **tooth** (pl.: **teeth**) is a hard, calcified structure found in the jaws (or mouths) of many vertebrates and used to break down food. Some animals, particularly carnivores and omnivores, also use teeth to help with capturing or wounding prey, tearing food, for defensive purposes, to intimidate other animals often including their own, or to carry prey or their young. The roots of teeth are covered by gums. Teeth are not made of bone, but rather of multiple tissues of varying density and hardness that originate from the outermost embryonic germ layer, the ectoderm.

The general structure of teeth is similar across the vertebrates, although there is considerable variation in their form and position. The teeth of mammals have deep roots, and this pattern is also found in some fish, and in crocodylians. In most teleost fish, however, the teeth are attached to the outer surface of the bone, while in lizards they are attached to the inner surface of the jaw by one side. In cartilaginous fish, such as sharks, the teeth are attached by tough ligaments to the hoops of cartilage that form the jaw.^[1]

Monophyodonts are animals that develop only one set of teeth, while diphyodonts grow an early set of deciduous teeth and a later set of permanent or "adult" teeth. Polyphyodonts grow many sets of teeth. For example, sharks, grow a new set of teeth every two weeks to replace worn teeth. Most extant mammals including humans are diphyodonts, but there are exceptions including elephants, kangaroos, and manatees, all of which are polyphyodonts.

Rodent incisors grow and wear away continually through gnawing, which helps maintain relatively constant length. The industry of the beaver is due in part to this qualification. Some rodents, such as voles and guinea pigs (but not mice), as well as lagomorpha (rabbits, hares and pikas), have continuously growing molars in addition to incisors.^{[2][3]} Also, tusks (in tusked mammals) grow almost throughout life.^[4]

Teeth are not always attached to the jaw, as they are in mammals. In many reptiles and fish, teeth are attached to the palate or to the floor of the mouth, forming additional rows inside those on the jaws proper. Some teleosts even have teeth in the pharynx. While not true teeth in the usual sense, the dermal denticles of sharks are almost identical in structure and are likely to have the same evolutionary origin. Indeed, teeth appear to have first evolved in sharks, and are not found in the more primitive jawless fish – while lampreys do have tooth-like structures on the tongue, these are in fact, composed of keratin, not of dentine or enamel, and bear no relationship to true teeth.^[1] Though "modern" teeth-like structures with dentine and enamel have been found in late conodonts, they are now supposed to have evolved independently of later vertebrates' teeth.^{[5][6]}

Living amphibians typically have small teeth, or none at all, since they commonly feed only on soft foods. In reptiles, teeth are generally simple and conical in shape, although there is some variation between species, most notably the venom-injecting fangs of snakes. The pattern of incisors, canines, premolars and molars is found only in mammals, and to varying extents, in their evolutionary ancestors. The numbers of these types of teeth vary greatly between species; zoologists use a standardised dental formula to describe the precise pattern in any given group.^[1]

Etymology

[edit]

The word *tooth* comes from Proto-Germanic **tanþs*, derived from the Proto-Indo-European **h₁nt-*, which was composed of the root **h₁nt-* 'to eat' plus the active participle suffix **-nt-*, therefore literally meaning 'that which eats'.^[7]

The irregular plural form *teeth* is the result of Germanic umlaut whereby vowels immediately preceding a high vocalic in the following syllable were raised. As the nominative plural ending of the Proto-Germanic consonant stems (to which **tanþs* belonged) was **-iz*, the root vowel in the plural form **tanþiz* (changed by this point to **t^{ai}ntiz* via unrelated phonological processes) was raised to */e^{ai}/*, and later unrounded to */e^{ai}/*, resulting in the *t^{ai}nt* alternation attested from Old English. Cf. also Old English *b^{ai}ok*/*b^{ae}oks* 'book/books' and *m^{ai}se*/*m^{ae}ses* 'house/mice', from Proto-Germanic **b^{ai}ka* and **m^{ai}sa* respectively.

Cognate with Latin *d^{ai}ns*, Greek *δ^{ai}ς* (*dois*) and Sanskrit *dát*.

Origin

[edit]

Teeth are assumed to have evolved either from ectoderm denticles (scales, much like those on the skin of sharks) that folded and integrated into the mouth (called the "outside-in" theory), or from endoderm pharyngeal teeth (primarily formed in the pharynx of jawless vertebrates) (the "inside-out" theory). In addition, there is another theory stating that neural crest gene regulatory network, and neural crest-derived ectomesenchyme are the key to generate teeth (with any epithelium, either ectoderm or endoderm).^{[4][8]}

The genes governing tooth development in mammals are homologous to those involved in the development of fish scales.^[9] Study of a tooth plate of a fossil of the extinct fish *Romundina stellina* showed that the teeth and scales were made of the same tissues, also found in mammal teeth, lending support to the theory that teeth evolved as a modification of scales.^[10]

Mammals

[edit]

Main article: Mammal tooth

Teeth are among the most distinctive (and long-lasting) features of mammal species. Paleontologists use teeth to identify fossil species and determine their relationships. The shape of the animal's teeth are related to its diet. For example, plant matter is hard to digest, so herbivores have many molars for chewing and grinding. Carnivores, on the other hand, have canine teeth to kill prey and to tear meat.

Mammals, in general, are diphyodont, meaning that they develop two sets of teeth. In humans, the first set (the "baby", "milk", "primary" or "deciduous" set) normally starts to appear at about six months of age, although some babies are born with one or more visible teeth, known as neonatal teeth. Normal tooth eruption at about six months is known as teething and can be painful. Kangaroos, elephants, and manatees are unusual among mammals because they are polyphyodonts.

Aardvark

[edit]

In aardvarks, teeth lack enamel and have many pulp tubules, hence the name of the order Tubulidentata.^[11]

Canines

[edit]

In dogs, the teeth are less likely than humans to form dental cavities because of the very high pH of dog saliva, which prevents enamel from demineralizing.^[12] Sometimes called cuspids, these teeth are shaped like points (cusps) and are used for tearing and grasping food.^[13]

Cetaceans

[edit]

Main article: Baleen

Like human teeth, whale teeth have polyp-like protrusions located on the root surface of the tooth. These polyps are made of cementum in both species, but in human teeth, the protrusions are located on the outside of the root, while in whales the nodule is located on the inside of the pulp chamber. While the roots of human teeth are made of cementum on the outer surface, whales have cementum on the entire surface of the tooth with a very small layer of enamel at the tip. This small enamel layer is only seen in older whales where the cementum has been worn away to show the underlying enamel.^[14]

The toothed whale is a parvorder of the cetaceans characterized by having teeth. The teeth differ considerably among the species. They may be numerous, with some dolphins bearing over 100 teeth in their jaws. On the other hand, the narwhals have a giant unicorn-like tusk, which is a tooth containing millions of sensory pathways and used for sensing during feeding, navigation, and mating. It is the most neurologically complex tooth known. Beaked whales are almost toothless, with only bizarre teeth found in males. These teeth may be used for feeding but also for demonstrating aggression and showmanship.

Primates

[edit]

Main articles: Human tooth and Dental anatomy

In humans (and most other primates), there are usually 20 primary (also "baby" or "milk") teeth, and later up to 32 permanent teeth. Four of these 32 may be third molars or wisdom teeth, although these are not present in all adults, and may be removed surgically later in life.^[15]

Among primary teeth, 10 of them are usually found in the maxilla (i.e. upper jaw) and the other 10 in the mandible (i.e. lower jaw). Among permanent teeth, 16 are found in the maxilla and the other 16 in the mandible. Most of the teeth have uniquely distinguishing features.

Horse

[edit]

Main article: Horse teeth


An adult horse has between 36 and 44 teeth. The enamel and dentin layers of horse teeth are intertwined.^[16] All horses have 12 premolars, 12 molars, and 12 incisors.^[17] Generally, all male equines also have four canine teeth (called tushes) between the molars and incisors. However, few female horses (less than 28%) have canines, and those that do usually have only one or two, which many times are only partially erupted.^[18] A few horses have one to four wolf teeth, which are vestigial premolars, with most of those having only one or two. They are equally common in male and female horses and much more likely to be on the upper jaw. If present these can cause problems as they can interfere with the horse's bit contact. Therefore, wolf teeth are commonly removed.^[17]

Horse teeth can be used to estimate the animal's age. Between birth and five years, age can be closely estimated by observing the eruption pattern on milk teeth and then permanent teeth. By age five, all permanent teeth have usually erupted. The horse is then said to have a "full" mouth. After the age of five, age can only be conjectured by studying the wear patterns on the incisors, shape, the angle at which the incisors meet, and other factors. The wear of teeth may also be affected by diet, natural abnormalities, and cribbing. Two horses of the same age may have different wear patterns.

A horse's incisors, premolars, and molars, once fully developed, continue to erupt as the grinding surface is worn down through chewing. A young adult horse will have teeth, which are 110–130 mm (4.5–5 inches) long, with the majority of the crown remaining below the gumline in the dental socket. The rest of the tooth will slowly emerge from the jaw, erupting about 3 mm (1/8 in) each year, as the horse ages. When the animal reaches old age, the crowns of the teeth are very short and the teeth are often lost altogether. Very old horses, if lacking molars, may need to have their fodder ground up and soaked in water to create a soft mush for them to eat in order to obtain adequate nutrition.

Proboscideans

[edit]



Section through the ivory tusk of a mammoth

Main article: Elephant ivory

Elephants' tusks are specialized incisors for digging food up and fighting. Some elephant teeth are similar to those in manatees, and elephants are believed to have undergone an aquatic phase in their evolution.


At birth, elephants have a total of 28 molar plate-like grinding teeth not including the tusks. These are organized into four sets of seven successively larger teeth which the elephant will slowly wear through during its lifetime of chewing rough plant material. Only four teeth are used for chewing at a given time, and as each tooth wears out, another tooth moves forward to take its place in a process similar to a conveyor belt. The last and largest of these teeth usually becomes exposed when the animal is around 40 years of age, and will often last for an additional 20 years. When the last of these teeth has fallen out, regardless of the elephant's age, the animal will no longer be able to chew food and will die of starvation.^{[19][20]}

Rabbit

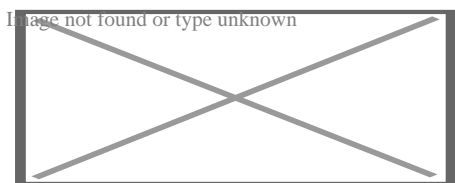
[edit]

Rabbits and other lagomorphs usually shed their deciduous teeth before (or very shortly after) their birth, and are usually born with their permanent teeth.^[21] The teeth of rabbits complement their diet, which consists of a wide range of vegetation. Since many of the foods are abrasive enough to cause attrition, rabbit teeth grow continuously throughout life.^[22] Rabbits have a total of six incisors, three upper premolars, three upper molars, two lower premolars, and two lower molars on each side. There are no canines. Dental formula is $\frac{2.0.3.3}{1.0.2.3} = 28$. Three to four millimeters of the tooth is worn away by incisors every week, whereas the cheek teeth require a month to wear away the same amount.^[23]

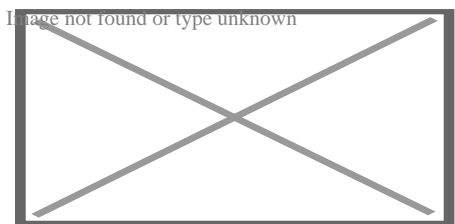
The incisors and cheek teeth of rabbits are called aradicular hypsodont teeth. This is sometimes referred to as an elodont dentition. These teeth grow or erupt continuously. The growth or eruption is held in balance by dental abrasion from chewing a diet high in fiber.



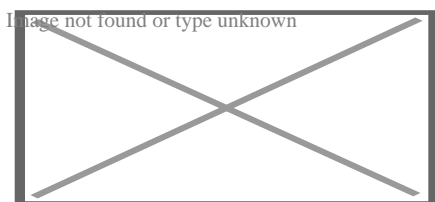
Buccal view of top incisor from *Rattus rattus*. Top incisor outlined in yellow. Molars circled in blue.



Buccal view of the lower incisor from the right dentary of a *Rattus rattus*



Lingual view of the lower incisor from the right dentary of a *Rattus rattus*




Midsagittal view of top incisor from *Rattus rattus*. Top incisor outlined in yellow. Molars circled in blue.

Rodents

[edit]

Rodents have upper and lower hypselodont incisors that can continuously grow enamel throughout its life without having properly formed roots.^[24] These teeth are also known as aradicular teeth, and unlike humans whose ameloblasts die after tooth development, rodents continually produce enamel, they must wear down their teeth by gnawing on various materials.^[25] Enamel and dentin are produced by the enamel organ, and growth is dependent on the presence of stem cells, cellular amplification, and cellular maturation structures in the odontogenic region.^[26] Rodent incisors are used for cutting wood, biting through the skin of fruit, or for defense. This allows for the rate of wear and tooth growth to be at equilibrium.^[24] The microstructure of rodent incisor enamel has shown to be useful in studying the phylogeny and systematics of rodents because of its independent evolution from the other dental traits. The enamel on rodent incisors are composed of two layers: the inner portio interna (PI) with Hunter-Schreger bands (HSB) and an outer portio externa (PE) with radial enamel (RE).^[27] It usually involves the differential regulation of the epithelial stem cell niche in the tooth of two rodent species, such as guinea pigs.^[28]^[29]



Lingual view of top incisor from *Rattus rattus*. Top incisor outlined in yellow. Molars circled in blue.

The teeth have enamel on the outside and exposed dentin on the inside, so they self-sharpen during gnawing. On the other hand, continually growing molars are found in some rodent species, such as the sibling vole and the guinea pig.^[28]^[29] There is variation in the dentition of the rodents, but generally, rodents lack

canines and premolars, and have a space between their incisors and molars, called the diastema region.

Manatee

[edit]

Manatees are polyphyodont with mandibular molars developing separately from the jaw and are encased in a bony shell separated by soft tissue.^{[30][31]}

Walrus


[edit]

Main article: Walrus ivory

Walrus tusks are canine teeth that grow continuously throughout life.^[32]

Fish

[edit]



Teeth of a great white shark

See also: Pharyngeal teeth and Shark tooth

Fish, such as sharks, may go through many teeth in their lifetime. The replacement of multiple teeth is known as polyphyodontia.

A class of prehistoric shark are called cladodonts for their strange forked teeth.

Unlike the continuous shedding of functional teeth seen in modern sharks,^{[33][34]} the majority of stem chondrichthyan lineages retained all tooth generations developed throughout the life of the animal.^[35] This replacement mechanism is exemplified by the tooth whorl-based dentitions of acanthodians,^[36] which include the oldest known toothed vertebrate, *Qianodus duplicis*^[37].

Amphibians

[edit]

All amphibians have pedicellate teeth, which are modified to be flexible due to connective tissue and uncalcified dentine that separates the crown from the base of the tooth.^[38]

Most amphibians exhibit teeth that have a slight attachment to the jaw or acrodont teeth. Acrodont teeth exhibit limited connection to the dentary and have little enervation.^[39] This is ideal for organisms who mostly use their teeth for grasping, but not for crushing and allows for rapid regeneration of teeth at a low energy cost. Teeth are usually lost in the course of feeding if the prey is struggling. Additionally, amphibians that undergo a metamorphosis develop bicuspid shaped teeth.^[40]

Reptiles

[edit]

The teeth of reptiles are replaced constantly throughout their lives. Crocodylian juveniles replace teeth with larger ones at a rate as high as one new tooth per socket every month. Once mature, tooth replacement rates can slow to two years

and even longer. Overall, crocodylians may use 3,000 teeth from birth to death. New teeth are created within old teeth.^[41]

Birds


[edit]

Main article: Ichthyornis

A skull of Ichthyornis discovered in 2014 suggests that the beak of birds may have evolved from teeth to allow chicks to escape their shells earlier, and thus avoid predators and also to penetrate protective covers such as hard earth to access underlying food.^[42]^[43]

Invertebrates

[edit]




The European medicinal leech has three jaws with numerous sharp teeth which function like little saws for incising a host.

True teeth are unique to vertebrates,^[44] although many invertebrates have analogous structures often referred to as teeth. The organisms with the simplest genome bearing such tooth-like structures are perhaps the parasitic worms of the family Ancylostomatidae.^[45] For example, the hookworm *Necator americanus* has two dorsal and two ventral cutting plates or teeth around the anterior margin of

the buccal capsule. It also has a pair of subdorsal and a pair of subventral teeth located close to the rear.^[46]

Historically, the European medicinal leech, another invertebrate parasite, has been used in medicine to remove blood from patients.^[47] They have three jaws (tripartite) that resemble saws in both appearance and function, and on them are about 100 sharp teeth used to incise the host. The incision leaves a mark that is an inverted Y inside of a circle. After piercing the skin and injecting anticoagulants (hirudin) and anaesthetics, they suck out blood, consuming up to ten times their body weight in a single meal.^[48]

In some species of Bryozoa, the first part of the stomach forms a muscular gizzard lined with chitinous teeth that crush armoured prey such as diatoms. Wave-like peristaltic contractions then move the food through the stomach for digestion.^[49]



The limpet rasps algae from rocks using teeth with the strongest known tensile strength of any biological material.

Molluscs have a structure called a radula, which bears a ribbon of chitinous teeth. However, these teeth are histologically and developmentally different from vertebrate teeth and are unlikely to be homologous. For example, vertebrate teeth develop from a neural crest mesenchyme-derived dental papilla, and the neural crest is specific to vertebrates, as are tissues such as enamel.^[44]

The radula is used by molluscs for feeding and is sometimes compared rather inaccurately to a tongue. It is a minutely toothed, chitinous ribbon, typically used for scraping or cutting food before the food enters the oesophagus. The radula is unique to molluscs, and is found in every class of mollusc apart from bivalves.

Within the gastropods, the radula is used in feeding by both herbivorous and carnivorous snails and slugs. The arrangement of teeth (also known as denticles) on the radula ribbon varies considerably from one group to another as shown in the diagram on the left.

Predatory marine snails such as the Naticidae use the radula plus an acidic secretion to bore through the shell of other molluscs. Other predatory marine snails, such as the Conidae, use a specialized radula tooth as a poisoned harpoon. Predatory pulmonate land slugs, such as the ghost slug, use elongated razor-sharp teeth on the radula to seize and devour earthworms. Predatory cephalopods, such as squid, use the radula for cutting prey.

In most of the more ancient lineages of gastropods, the radula is used to graze by scraping diatoms and other microscopic algae off rock surfaces and other substrates. Limpets scrape algae from rocks using radula equipped with exceptionally hard rasping teeth.^[50] These teeth have the strongest known tensile strength of any biological material, outperforming spider silk.^[50] The mineral protein of the limpet teeth can withstand a tensile stress of 4.9 GPa, compared to 4 GPa of spider silk and 0.5 GPa of human teeth.^[51]

Fossilization and taphonomy

[edit]

Because teeth are very resistant, often preserved when bones are not,^[52] and reflect the diet of the host organism, they are very valuable to archaeologists and


palaeontologists.^[53] Early fish such as the thelodonts had scales composed of dentine and an enamel-like compound, suggesting that the origin of teeth was from scales which were retained in the mouth. Fish as early as the late Cambrian had dentine in their exoskeletons, which may have functioned in defense or for sensing their environments.^[54] Dentine can be as hard as the rest of teeth and is composed of collagen fibres, reinforced with hydroxyapatite.^[54]

Though teeth are very resistant, they also can be brittle and highly susceptible to cracking.^[55] However, cracking of the tooth can be used as a diagnostic tool for predicting bite force. Additionally, enamel fractures can also give valuable insight into the diet and behaviour of archaeological and fossil samples.

Decalcification removes the enamel from teeth and leaves only the organic interior intact, which comprises dentine and cementine.^[56] Enamel is quickly decalcified in acids,^[57] perhaps by dissolution by plant acids or via diagenetic solutions, or in the stomachs of vertebrate predators.^[56] Enamel can be lost by abrasion or spalling,^[56] and is lost before dentine or bone are destroyed by the fossilisation process.^[57] In such a case, the 'skeleton' of the teeth would consist of the dentine, with a hollow pulp cavity.^[56] The organic part of dentine, conversely, is destroyed by alkalis.^[57]

See also

[edit]

-  [Medicine portal](#)
- Animal tooth development
- Dragon's teeth (mythology)

References

[edit]

- [^] **abc** *Romer, Alfred Sherwood; Parsons, Thomas S. (1977). The Vertebrate Body. Philadelphia, PA: Holt-Saunders International. pp. 300–310. ISBN 978-0-*

03-910284-5.

2. ^ Tummers M, Thesleff I (March 2003). "Root or crown: a developmental choice orchestrated by the differential regulation of the epithelial stem cell niche in the tooth of two rodent species". *Development*. **130** (6): 1049–57. doi:10.1242/dev.00332. PMID 12571097.
3. ^ Hunt AM (1959). "A description of the molar teeth and investing tissues of normal guinea pigs". *J. Dent. Res.* **38** (2): 216–31. doi:10.1177/00220345590380020301. PMID 13641521. S2CID 45097018.
4. ^ a b Nasoori, Alireza (2020). "Tusks, the extra-oral teeth". *Archives of Oral Biology*. **117**: 104835. doi:10.1016/j.archoralbio.2020.104835. PMID 32668361. S2CID 220585014.
5. ^ McCOLLUM, MELANIE; SHARPE, PAUL T. (July 2001). "Evolution and development of teeth". *Journal of Anatomy*. **199** (1–2): 153–159. doi:10.1046/j.1469-7580.2001.19910153.x. PMC 1594990. PMID 11523817.
6. ^ Kaplan, Matt (October 16, 2013). "Fossil scans reveal origins of teeth". *Nature*. doi:10.1038/nature.2013.13964 – via www.nature.com.
7. ^ Harper, Douglas (2001–2021). "tooth | Origin and meaning of tooth". *Online Etymology Dictionary*.
8. ^ Jheon, Andrew H (2012). "From molecules to mastication: the development and evolution of teeth". *Wiley Interdiscip Rev Dev Biol*. **2** (2): 165–182. doi:10.1002/wdev.63. PMC 3632217. PMID 24009032.
9. ^ Sharpe, P. T. (2001). "Fish scale development: Hair today, teeth and scales yesterday?". *Current Biology*. **11** (18): R751 – R752. Bibcode:2001CBio...11.R751S. doi:10.1016/S0960-9822(01)00438-9. PMID 11566120. S2CID 18868124.
10. ^ Jennifer Viegas (June 24, 2015). "First-known teeth belonged to fierce fish". *ABC Science*. Retrieved June 28, 2015.
11. ^ Shoshani 2002, p. 619
12. ^ Hale, FA (2009). "Dental caries in the dog". *Can. Vet. J.* **50** (12): 1301–4. PMC 2777300. PMID 20190984.
13. ^ "Types of Teeth, Dental Anatomy & Tooth Anatomy | Colgate®". *www.colgate.com*. Archived from the original on 2017-11-19. Retrieved 2017-11-19.
14. ^ "Common Characteristics Of Whale Teeth". Archived from the original on 4 September 2011. Retrieved 18 July 2014.
15. ^ "Everything you need to know about teeth". *NHS Scotland*. Retrieved 5 May 2020.

16. ^ "Gummed Out: Young Horses Lose Many Teeth, Vet Says". Archived from the original on 8 July 2014. Retrieved 6 July 2014.
17. ^ **a b** Patricia Pence (2002). *Equine Dentistry: A Practical Guide*. Baltimore: Lippincott Williams & Wilkins. ISBN 978-0-683-30403-9.
18. ^ Al Cirelli. "Equine Dentition" (PDF). University of Nevada Reno. SP-00-08. Retrieved 7 June 2010.
19. ^ Maurice Burton; Robert Burton (2002). *International Wildlife Encyclopedia*. Marshall Cavendish. p. 769. ISBN 978-0-7614-7266-7.
20. ^ Bram, L. et al. MCMLXXXIII. *Elephants*. Funk & Wagnalls New Encyclopedia, Volume 9, p. 183. ISBN 0-8343-0051-6
21. ^ "Dental Anatomy & Care for Rabbits and Rodents".
22. ^ Brown, Susan. Rabbit Dental Diseases Archived 2007-10-14 at the Wayback Machine, hosted on the San Diego Chapter of the House Rabbit Society Archived 2007-10-13 at the Wayback Machine. Page accessed April 9, 2007.
23. ^ Ryñavy, Robin. Hay & Dental Health, hosted by the Missouri House Rabbit Society-Kansas City. Page accessed January 2, 2024.
24. ^ **a b** Cox, Philip; Hautier, Lionel (2015). *Evolution of the Rodents: Advances in Phylogeny, Functional Morphology and Development*. Cambridge University Press. p. 482. ISBN 9781107044333.
25. ^ Caceci, Thomas. *Veterinary Histology* with subtitle "Digestive System: Oral Cavity" found here Archived 2006-04-30 at the Wayback Machine.
26. ^ Gomes, J.r.; Omar, N.f.; Do Carmo, E.r.; Neves, J.s.; Soares, M.a.m.; Narvaes, E.a.; Novaes, P.d. (30 April 2013). "Relationship Between Cell Proliferation and Eruption Rate in the Rat Incisor". *The Anatomical Record*. **296** (7): 1096–1101. doi:10.1002/ar.22712. ISSN 1932-8494. PMID 23629828. S2CID 13197331.
27. ^ Martin, Thomas (September 1999). "Evolution of Incisor Enamel Microstructure in Theridomyidae (Rodentia)". *Journal of Vertebrate Paleontology*. **19** (3): 550. Bibcode:1999JVPal..19..550M. doi:10.1080/02724634.1999.10011164.
28. ^ **a b** Tummers M and Thesleff I. Root or crown: a developmental choice orchestrated by the differential regulation of the epithelial stem cell niche in the tooth of two rodent species. *Development* (2003). 130(6):1049–57.
29. ^ **a b** AM Hunt. A description of the molar teeth and investing tissues of normal guinea pigs. *J Dent Res.* (1959) 38(2):216–31.

30. ^ Shoshani, J., ed. (2000). *Elephants: Majestic Creatures of the Wild*. Checkmark Books. ISBN 0-87596-143-6.
31. ^ Best, Robin (1984). Macdonald, D. (ed.). *The Encyclopedia of Mammals*. New York: Facts on File. pp. 292–298. ISBN 0-87196-871-1.
32. ^ The Permanent Canine Teeth, hosted on the University of Illinois at Chicago website. Page accessed February 5, 2007.
33. ^ Underwood, Charlie; Johanson, Zerina; Smith, Moya Meredith (November 2016). "Cutting blade dentitions in squaliform sharks form by modification of inherited alternate tooth ordering patterns". *Royal Society Open Science*. **3** (11): 160385. Bibcode:2016RSOS....360385U. doi:10.1098/rsos.160385. ISSN 2054-5703. PMC 5180115. PMID 28018617. S2CID 12821592.
34. ^ Fraser, Gareth J.; Thiery, Alex P. (2019), Underwood, Charlie; Richter, Martha; Johanson, Zerina (eds.), "Evolution, Development and Regeneration of Fish Dentitions", *Evolution and Development of Fishes*, Cambridge: Cambridge University Press, pp. 160–171, doi:10.1017/9781316832172.010, ISBN 978-1-107-17944-8, S2CID 92225621, retrieved 2022-10-22
35. ^ Rücklin, Martin; King, Benedict; Cunningham, John A.; Johanson, Zerina; Marone, Federica; Donoghue, Philip C. J. (2021-05-06). "Acanthodian dental development and the origin of gnathostome dentitions". *Nature Ecology & Evolution*. **5** (7): 919–926. Bibcode:2021NatEE...5..919R. doi:10.1038/s41559-021-01458-4. hdl:1983/27f9a13a-1441-410e-b9a7-116b42cd40f7. ISSN 2397-334X. PMID 33958756. S2CID 233985000.
36. ^ Burrow, Carole (2021). *Acanthodii, Stem Chondrichthyes*. Verlag Dr. Friedrich Pfeil. ISBN 978-3-89937-271-7. OCLC 1335983356.
37. ^ Andreev, Plamen S.; Sansom, Ivan J.; Li, Qiang; Zhao, Wenjin; Wang, Jianhua; Wang, Chun-Chieh; Peng, Lijian; Jia, Liantao; Qiao, Tuo; Zhu, Min (September 2022). "The oldest gnathostome teeth". *Nature*. **609** (7929): 964–968. Bibcode:2022Natur.609..964A. doi:10.1038/s41586-022-05166-2. ISSN 1476-4687. PMID 36171375. S2CID 252569771.
38. ^ Pough, Harvey. *Vertebrate Life*. 9th Ed. Boston: Pearson Education, Inc., 2013. 211–252. Print.
39. ^ Kardong, Kenneth (1995). *Vertebrate: Comparative Anatomy, Function, Evolution*. New York: McGraw-Hill. pp. 215–225. ISBN 9780078023026.
40. ^ Xiong, Jianli (2014). "Comparison of vomerine tooth rows in juvenile and adult *Hynobius guabangshanensis*". *Vertebrate Zoology*. **64**: 215–220.

41. ^ Poole, D. F. G. (January 1961). "Notes on Tooth Replacement in the Nile Crocodile *Crocodylus niloticus*". *Proceedings of the Zoological Society of London*. **136** (1): 131–140. doi:10.1111/j.1469-7998.1961.tb06083.x.
42. ^ Hersher, Rebecca (May 2, 2018). "How Did Birds Lose Their Teeth And Get Their Beaks? Study Offers Clues". NPR.
43. ^ Field, Daniel J.; Hanson, Michael; Burnham, David; Wilson, Laura E.; Super, Kristopher; Ehret, Dana; Ebersole, Jun A.; Bhullar, Bhart-Anjan S. (May 31, 2018). "Complete Ichthyornis skull illuminates mosaic assembly of the avian head". *Nature* Vol 557, pp 96 – 100.
44. ^ **a b** Kardong, Kenneth V. (1995). *Vertebrates: comparative anatomy, function, evolution*. McGraw-Hill. pp. 55, 57. ISBN 978-0-697-21991-6.
45. ^ "Ancylostoma duodenale". *Nematode.net Genome Sequencing Center*. Archived from the original on 2008-05-16. Retrieved 2009-10-27.
46. ^ Roberts, Larry S., and John Janovy, Jr. *Foundations of Parasitology*. Seventh ed. Singapore: McGraw-Hill, 2006.
47. ^ Brian Payton (1981). *Kenneth Muller; John Nicholls; Gunther Stent (eds.). Neurobiology of the Leech*. New York: Cold Spring Harbor Laboratory. pp. 27–34. ISBN 978-0-87969-146-2.
48. ^ Wells MD, Manktelow RT, Boyd JB, Bowen V (1993). "The medical leech: an old treatment revisited". *Microsurgery*. **14** (3): 183–6. doi:10.1002/micr.1920140309. PMID 8479316. S2CID 27891377.
49. ^ Ruppert, E.E.; Fox, R.S.; Barnes, R.D. (2004). "Lophoporata". *Invertebrate Zoology* (7 ed.). Brooks / Cole. pp. 829–845. ISBN 978-0-03-025982-1.
50. ^ **a b** Asa H. Barber; Dun Lu; Nicola M. Pugno (18 February 2015), "Extreme strength observed in limpet teeth", *Journal of the Royal Society Interface*, **12** (105): 20141326, doi:10.1098/rsif.2014.1326, PMC 4387522, PMID 25694539
51. ^ Zachary Davies Boren (18 February 2015). "The strongest materials in the world: Limpet teeth beats record resistance of spider silk". *The Independent*. Retrieved 20 February 2015.
52. ^ *Taphonomy: A Process Approach*. Ronald E. Martin. Illustrated edition. Cambridge University Press, 1999. ISBN 978-0-521-59833-0
53. ^ Towle, Ian; Irish, Joel D.; De Groot, Isabelle (2017). "Behavioral inferences from the high levels of dental chipping in *Homo naledi*". *American Journal of Physical Anthropology*. **164** (1): 184–192. doi:10.1002/ajpa.23250. PMID 28542710. S2CID 24296825. Retrieved 2019-01-09.

54. ^ **a b** Teaford, Mark F and Smith, Moya Meredith, 2007. *Development, Function and Evolution of Teeth*, Cambridge University Press. ISBN 978-0-521-03372-5, Chapter 5.
55. ^ Lee, James J.-W.; Constantino, Paul J.; Lucas, Peter W.; Lawn, Brian R. (2011-11-01). "Fracture in teeth—a diagnostic for inferring bite force and tooth function". *Biological Reviews*. **86** (4): 959–974. doi:10.1111/j.1469-185x.2011.00181.x. ISSN 1469-185X. PMID 21507194. S2CID 205599560.
56. ^ **a b c d** Fisher, Daniel C (1981). "Taphonomic Interpretation of Enamel-Less Teeth in the Shotgun Local Fauna (Paleocene, Wyoming)". *Museum of Paleontology Contributions, the University of Michigan*. **25** (13): 259–275. hdl:2027.42/48503.
57. ^ **a b c** Fernandez-Jalvo, Y.; Sanchez-Chillon, B.; Andrews, P.; Fernandez-Lopez, S.; Alcalá Martínez, L. (2002). "Morphological taphonomic transformations of fossil bones in continental environments, and repercussions on their chemical composition" (PDF). *Archaeometry*. **44** (3): 353–361. doi:10.1111/1475-4754.t01-1-00068.

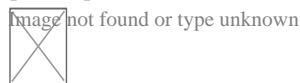
Sources

[edit]

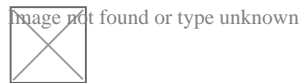
- Shoshani, Jeheskel (2002). "Tubulidentata". In Robertson, Sarah (ed.). *Encyclopedia of Life Sciences. Vol. 18: Svedberg, Theodor to Two-hybrid and Related Systems*. London, UK: Nature Publishing Group. ISBN 978-1-56159-274-6.

External links

[edit]



Wikimedia Commons has media related to ***tooth***.



Look up ***tooth*** in Wiktionary, the free dictionary.

- Beach, Chandler B., ed. (1914). "Teeth" . *The New Student's Reference Work* . Chicago: F. E. Compton and Co.


- Germany
- United States
- France
- BnF data
- Japan
- Czech Republic
- Israel

Authority control databases: National

Image not found or type unknown
 Edit this at Wikidata

About malocclusion

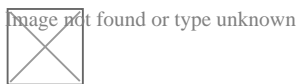
"Deep bite" and "Buck teeth" redirect here. For the village, see Deep Bight, Newfoundland and Labrador.



Malocclusion in 10-year-old girl

Specialty Dentistry

Image not found or type unknown
 Edit this on Wikidata



Look up ***bucktooth*** in Wiktionary, the free dictionary.

In orthodontics, a **malocclusion** is a misalignment or incorrect relation between the teeth of the upper and lower dental arches when they approach each other as the jaws close. The English-language term dates from 1864;^[1] Edward Angle (1855–1930), the "father of modern orthodontics",^[2]^[3] *[need quotation to verify]* popularised it. The word derives from *mal-* 'incorrect' and *occlusion* 'the manner in which opposing teeth meet'.

The malocclusion classification is based on the relationship of the mesiobuccal cusp of the maxillary first molar and the buccal groove of the mandibular first molar. If this molar relationship exists, then the teeth can align into normal occlusion. According to Angle, malocclusion is any deviation of the occlusion from the ideal.^[4] However, assessment for malocclusion should also take into account aesthetics and the impact on functionality. If these aspects are acceptable to the patient despite meeting the formal definition of malocclusion, then treatment may not be necessary. It is estimated that nearly 30% of the population have malocclusions that are categorised as severe and definitely benefit from orthodontic treatment.^[5]

Causes

[edit]

The aetiology of malocclusion is somewhat contentious, however, simply put it is multifactorial, with influences being both genetic^[6] *[unreliable source?]* and environmental.^[7] Malocclusion is already present in one of the Skhul and Qafzeh hominin fossils and other prehistoric human skulls.^[8]^[9] There are three generally accepted causative factors of malocclusion:

- Skeletal factors – the size, shape and relative positions of the upper and lower jaws. Variations can be caused by environmental or behavioral factors such as muscles of mastication, nocturnal mouth breathing, and cleft lip and cleft palate.

- Muscle factors – the form and function of the muscles that surround the teeth. This could be impacted by habits such as finger sucking, nail biting, pacifier and tongue thrusting^[10]
- Dental factors – size of the teeth in relation to the jaw, early loss of teeth could result in spacing or mesial migration causing crowding, abnormal eruption path or timings, extra teeth (supernumeraries), or too few teeth (hypodontia)

There is not one single cause of malocclusion, and when planning orthodontic treatment it is often helpful to consider the above factors and the impact they have played on malocclusion. These can also be influenced by oral habits and pressure resulting in malocclusion.^{[11][12]}

Behavioral and dental factors

[edit]

In the active skeletal growth,^[13] mouthbreathing, finger sucking, thumb sucking, pacifier sucking, onychophagia (nail biting), dermatophagia, pen biting, pencil biting, abnormal posture, deglutition disorders and other habits greatly influence the development of the face and dental arches.^{[14][15][16][17][18]} Pacifier sucking habits are also correlated with otitis media.^{[19][20]} Dental caries, periapical inflammation and tooth loss in the deciduous teeth can alter the correct permanent teeth eruptions.

Primary vs. secondary dentition

[edit]

Malocclusion can occur in primary and secondary dentition.

In primary dentition malocclusion is caused by:

- Underdevelopment of the dentoalveolar tissue.
- Over development of bones around the mouth.
- Cleft lip and palate.
- Overcrowding of teeth.
- Abnormal development and growth of teeth.

In secondary dentition malocclusion is caused by:

- Periodontal disease.
- Overeruption of teeth.^[21]
- Premature and congenital loss of missing teeth.

Signs and symptoms

[edit]

Malocclusion is a common finding,^[22]^[23] although it is not usually serious enough to require treatment. Those who have more severe malocclusions, which present as a part of craniofacial anomalies, may require orthodontic and sometimes surgical treatment (orthognathic surgery) to correct the problem.

The ultimate goal of orthodontic treatment is to achieve a stable, functional and aesthetic alignment of teeth which serves to better the patient's dental and total health.^[24] The symptoms which arise as a result of malocclusion derive from a deficiency in one or more of these categories.^[25]

The symptoms are as follows:

- Tooth decay (caries): misaligned teeth will make it more difficult to maintain oral hygiene. Children with poor oral hygiene and diet will be at an increased risk.
- Periodontal disease: irregular teeth would hinder the ability to clean teeth meaning poor plaque control. Additionally, if teeth are crowded, some may be

more buccally or lingually placed, there will be reduced bone and periodontal support. Furthermore, in Class III malocclusions, mandibular anterior teeth are pushed labially which contributes to gingival recession and weakens periodontal support.

- Trauma to anterior teeth: Those with an increased overjet are at an increased risk of trauma. A systematic review found that an overjet of greater than 3mm will double the risk of trauma.
- Masticatory function: people with anterior open bites, large increased & reverse overjet and hypodontia will find it more difficult to chew food.
- Speech impairment: a lisp is when the incisors cannot make contact, orthodontics can treat this. However, other forms of misaligned teeth will have little impact on speech and orthodontic treatment has little effect on fixing any problems.
- Tooth impaction: these can cause resorption of adjacent teeth and other pathologies for example a dentigerous cyst formation.
- Psychosocial wellbeing: malocclusions of teeth with poor aesthetics can have a significant effect on self-esteem.

Malocclusions may be coupled with skeletal disharmony of the face, where the relations between the upper and lower jaws are not appropriate. Such skeletal disharmonies often distort sufferer's face shape, severely affect aesthetics of the face, and may be coupled with mastication or speech problems. Most skeletal malocclusions can only be treated by orthognathic surgery. ^[citation needed]

Classification

[edit]

Depending on the sagittal relations of teeth and jaws, malocclusions can be divided mainly into three types according to Angle's classification system published 1899. However, there are also other conditions, e.g. *crowding of teeth*, not

directly fitting into this classification.

Many authors have tried to modify or replace Angle's classification. This has resulted in many subtypes and new systems (see section below: *Review of Angle's system of classes*).

A deep bite (also known as a Type II Malocclusion) is a condition in which the upper teeth overlap the lower teeth, which can result in hard and soft tissue trauma, in addition to an effect on appearance.^[26] It has been found to occur in 15–20% of the US population.^[27]

An open bite is a condition characterised by a complete lack of overlap and occlusion between the upper and lower incisors.^[28] In children, open bite can be caused by prolonged thumb sucking.^[29] Patients often present with impaired speech and mastication.^[30]

Overbites

[edit]

This is a vertical measurement of the degree of overlap between the maxillary incisors and the mandibular incisors. There are three features that are analysed in the classification of an overbite:


- Degree of overlap: edge to edge, reduced, average, increased
- Complete or incomplete: whether there is contact between the lower teeth and the opposing teeth/tissue (hard palate or gingivae) or not.
- Whether contact is traumatic or atraumatic

An average overbite is when the upper anterior teeth cover a third of the lower teeth. Covering less than this is described as 'reduced' and more than this is an 'increased' overbite. No overlap or contact is considered an 'anterior open bite'.^[25]
^[31]^[32]


Angle's classification method

[edit]

This section **may be too technical for most readers to understand**. Please help improve it to make it understandable to non-experts, without removing the technical details. *(September 2023) (Learn how and when to remove this message)*



Class I with severe crowding and labially erupted canines



Class II molar relationship

Edward Angle, who is considered the father of modern orthodontics, was the first to classify malocclusion. He based his classifications on the relative position of the maxillary first molar.^[33] According to Angle, the mesiobuccal cusp of the upper first molar should align with the buccal groove of the mandibular first molar. The teeth should all fit on a line of occlusion which, in the upper arch, is a smooth curve through the central fossae of the posterior teeth and cingulum of the canines and incisors, and in the lower arch, is a smooth curve through the buccal cusps of the posterior teeth and incisal edges of the anterior teeth. Any variations from this

resulted in malocclusion types. It is also possible to have different classes of malocclusion on left and right sides.

- **Class I** (Neutroclusion): Here the molar relationship of the occlusion is normal but the incorrect line of occlusion or as described for the maxillary first molar, but the other teeth have problems like spacing, crowding, over or under eruption, etc.
- **Class II** (Distocclusion (retrognathism, overjet, overbite)): In this situation, the mesiobuccal cusp of the upper first molar is not aligned with the mesiobuccal groove of the lower first molar. Instead it is anterior to it. Usually the mesiobuccal cusp rests in between the first mandibular molars and second premolars. There are two subtypes:
 - Class II Division 1: The molar relationships are like that of Class II and the anterior teeth are protruded.
 - Class II Division 2: The molar relationships are Class II but the central are retroclined and the lateral teeth are seen overlapping the centrals.
- **Class III**: (Mesioclusion (prognathism, anterior crossbite, negative overjet, underbite)) In this case the upper molars are placed not in the mesiobuccal groove but posteriorly to it. The mesiobuccal cusp of the maxillary first molar lies posteriorly to the mesiobuccal groove of the mandibular first molar. Usually seen as when the lower front teeth are more prominent than the upper front teeth. In this case the patient very often has a large mandible or a short maxillary bone.

Review of Angle's system of classes and alternative systems

[edit]

A major disadvantage of Angle's system of classifying malocclusions is that it only considers two dimensions along a spatial axis in the sagittal plane in the terminal occlusion, but occlusion problems can be three-dimensional. It does not recognise deviations in other spatial axes, asymmetric deviations, functional faults and other

therapy-related features.

Angle's classification system also lacks a theoretical basis; it is purely descriptive. Its much-discussed weaknesses include that it only considers static occlusion, it does not account for the development and causes (aetiology) of occlusion problems, and it disregards the proportions (or relationships in general) of teeth and face.^[34] Thus, many attempts have been made to modify the Angle system or to replace it completely with a more efficient one,^[35] but Angle's classification continues to be popular mainly because of its simplicity and clarity.^[citation needed]

Well-known modifications to Angle's classification date back to Martin Dewey (1915) and Benno Lischer (1912, 1933). Alternative systems have been suggested by, among others, Simon (1930, the first three-dimensional classification system), Jacob A. Salzman (1950, with a classification system based on skeletal structures) and James L. Ackerman and William R. Proffit (1969).^[36]

Incisor classification

[edit]

Besides the molar relationship, the British Standards Institute Classification also classifies malocclusion into incisor relationship and canine relationship.

- Class I: The lower incisor edges occlude with or lie immediately below the cingulum plateau of the upper central incisors
- Class II: The lower incisor edges lie posterior to the cingulum plateau of the upper incisors
 - Division 1 – the upper central incisors are proclined or of average inclination and there is an increase in overjet
 - Division 2 – The upper central incisors are retroclined. The overjet is usually minimal or may be increased.

- Class III: The lower incisor edges lie anterior to the cingulum plateau of the upper incisors. The overjet is reduced or reversed.

Canine relationship by Ricketts

[edit]

- Class I: Mesial slope of upper canine coincides with distal slope of lower canine
- Class II: Mesial slope of upper canine is ahead of distal slope of lower canine
- Class III: Mesial slope of upper canine is behind to distal slope of lower canine

Crowding of teeth

[edit]

Dental crowding is defined by the amount of space that would be required for the teeth to be in correct alignment. It is obtained in two ways: 1) by measuring the amount of space required and reducing this from calculating the space available via the width of the teeth, or 2) by measuring the degree of overlap of the teeth.

The following criterion is used:[²⁵]

- 0-4mm = Mild crowding
- 4-8mm = Moderate crowding
- >8mm = Severe crowding

Causes

[edit]

Genetic (inheritance) factors, extra teeth, lost teeth, impacted teeth, or abnormally shaped teeth have been cited as causes of crowding. Ill-fitting dental fillings, crowns, appliances, retainers, or braces as well as misalignment of jaw fractures after a severe injury are also known to cause crowding.[²⁶] Tumors of the mouth

and jaw, thumb sucking, tongue thrusting, pacifier use beyond age three, and prolonged use of a bottle have also been identified.^[26]

Lack of masticatory stress during development can cause tooth overcrowding.^[37]^[38] Children who chewed a hard resinous gum for two hours a day showed increased facial growth.^[37] Experiments in animals have shown similar results. In an experiment on two groups of rock hyraxes fed hardened or softened versions of the same foods, the animals fed softer food had significantly narrower and shorter faces and thinner and shorter mandibles than animals fed hard food.^[37]^[39]^[failed verification]

A 2016 review found that breastfeeding lowers the incidence of malocclusions developing later on in developing infants.^[40]

During the transition to agriculture, the shape of the human mandible went through a series of changes. The mandible underwent a complex shape changes not matched by the teeth, leading to incongruity between the dental and mandibular form. These changes in human skulls may have been "driven by the decreasing bite forces required to chew the processed foods eaten once humans switched to growing different types of cereals, milking and herding animals about 10,000 years ago."^[38]^[41]

Treatment

[edit]

Orthodontic management of the condition includes dental braces, lingual braces, clear aligners or palatal expanders.^[42] Other treatments include the removal of one or more teeth and the repair of injured teeth. In some cases, surgery may be necessary.^[43]

Treatment

[edit]

Malocclusion is often treated with orthodontics,^[42] such as tooth extraction, clear aligners, or dental braces,^[44] followed by growth modification in children or jaw surgery (orthognathic surgery) in adults. Surgical intervention is used only in rare occasions. This may include surgical reshaping to lengthen or shorten the jaw. Wires, plates, or screws may be used to secure the jaw bone, in a manner like the surgical stabilization of jaw fractures. Very few people have "perfect" alignment of their teeth with most problems being minor that do not require treatment.^[37]

Crowding

[edit]

Crowding of the teeth is treated with orthodontics, often with tooth extraction, clear aligners, or dental braces, followed by growth modification in children or jaw surgery (orthognathic surgery) in adults. Surgery may be required on rare occasions. This may include surgical reshaping to lengthen or shorten the jaw (orthognathic surgery). Wires, plates, or screws may be used to secure the jaw bone, in a manner similar to the surgical stabilization of jaw fractures. Very few people have "perfect" alignment of their teeth. However, most problems are very minor and do not require treatment.^[39]

Class I

[edit]

While treatment is not crucial in class I malocclusions, in severe cases of crowding can be an indication for intervention. Studies indicate that tooth extraction can have benefits to correcting malocclusion in individuals.^[45]^[46] Further research is needed as reoccurring crowding has been examined in other clinical trials.^[45]^[47]

Class II

[edit]

A few treatment options for class II malocclusions include:

1. Functional appliance which maintains the mandible in a postured position to influence both the orofacial musculature and dentoalveolar development prior to fixed appliance therapy. This is ideally done through pubertal growth in pre-adolescent children and the fixed appliance during permanent dentition . [48] Different types of removable appliances include Activator, Bionatar, Medium opening activator, Herbst, Frankel and twin block appliance with the twin block being the most widely used one. [49]
2. Growth modification through headgear to redirect maxillary growth
3. Orthodontic camouflage so that jaw discrepancy no longer apparent
4. Orthognathic surgery – sagittal split osteotomy mandibular advancement carried out when growth is complete where skeletal discrepancy is severe in anterior–posterior relationship or in vertical direction. Fixed appliance is required before, during and after surgery.
5. Upper Removable Appliance – limited role in contemporary treatment of increased overjets. Mostly used for very mild Class II, overjet due to incisor proclination, favourable overbite.

Class II Division 1

[edit]

Low- to moderate- quality evidence suggests that providing early orthodontic treatment for children with prominent upper front teeth (class II division 1) is more effective for reducing the incidence of incisal trauma than providing one course of orthodontic treatment in adolescence. [50] There do not appear to be any other

advantages of providing early treatment when compared to late treatment.^[50]
Low-quality evidence suggests that, compared to no treatment, late treatment in adolescence with functional appliances is effective for reducing the prominence of upper front teeth.^[50]

Class II Division 2

[edit]

Treatment can be undertaken using orthodontic treatments using dental braces.^[51]
] While treatment is carried out, there is no evidence from clinical trials to recommend or discourage any type of orthodontic treatment in children.^[51] A 2018 Cochrane systematic review anticipated that the evidence base supporting treatment approaches is not likely to improve occlusion due to the low prevalence of the condition and the ethical difficulties in recruiting people to participate in a randomized controlled trials for treating this condition.^[51]

Class III

[edit]

The British Standard Institute (BSI) classify class III incisor relationship as the lower incisor edge lies anterior to the cingulum plateau of the upper incisors, with reduced or reversed over jet.^[52] The skeletal facial deformity is characterized by mandibular prognathism, maxillary retrognathism or a combination of the two. This effects 3–8% of UK population with a higher incidence seen in Asia.^[53]

One of the main reasons for correcting Class III malocclusion is aesthetics and function. This can have a psychological impact on the person with malocclusion resulting in speech and mastication problems as well. In mild class III cases, the patient is quite accepting of the aesthetics and the situation is monitored to

observe the progression of skeletal growth.^[54]

Maxillary and mandibular skeletal changes during prepubertal, pubertal and post pubertal stages show that class III malocclusion is established before the prepubertal stage.^[55] One treatment option is the use of growth modification appliances such as the Chin Cap which has greatly improved the skeletal framework in the initial stages. However, majority of cases are shown to relapse into inherited class III malocclusion during the pubertal growth stage and when the appliance is removed after treatment.^[55]

Another approach is to carry out orthognathic surgery, such as a bilateral sagittal split osteotomy (BSSO) which is indicated by horizontal mandibular excess. This involves surgically cutting through the mandible and moving the fragment forward or backwards for desired function and is supplemented with pre and post surgical orthodontics to ensure correct tooth relationship. Although the most common surgery of the mandible, it comes with several complications including: bleeding from inferior alveolar artery, unfavorable splits, condylar resorption, avascular necrosis and worsening of temporomandibular joint.^[56]

Orthodontic camouflage can also be used in patients with mild skeletal discrepancies. This is a less invasive approach that uses orthodontic brackets to correct malocclusion and try to hide the skeletal discrepancy. Due to limitations of orthodontics, this option is more viable for patients who are not as concerned about the aesthetics of their facial appearance and are happy to address the malocclusion only, as well as avoiding the risks which come with orthognathic surgery. Cephalometric data can aid in the differentiation between the cases that benefit from ortho-surgical or orthodontic treatment only (camouflage); for instance, examining a large group of orthognathic patient with Class III malocclusions they had average ANB angle of -3.57° (95% CI, -3.92° to -3.21°).^[57]

Deep bite

[edit]

The most common corrective treatments available are fixed or removal appliances (such as dental braces), which may or may not require surgical intervention. At this time there is no robust evidence that treatment will be successful.^[51]

Open bite

[edit]

An open bite malocclusion is when the upper teeth don't overlap the lower teeth. When this malocclusion occurs at the front teeth it is known as anterior open bite. An open bite is difficult to treat due to multifactorial causes, with relapse being a major concern. This is particularly so for an anterior open bite.^[58] Therefore, it is important to carry out a thorough initial assessment in order to obtain a diagnosis to tailor a suitable treatment plan.^[58] It is important to take into consideration any habitual risk factors, as this is crucial for a successful outcome without relapse. Treatment approach includes behavior changes, appliances and surgery. Treatment for adults include a combination of extractions, fixed appliances, intermaxillary elastics and orthognathic surgery.^[30] For children, orthodontics is usually used to compensate for continued growth. With children with mixed dentition, the malocclusion may resolve on its own as the permanent teeth erupt. Furthermore, should the malocclusion be caused by childhood habits such as digit, thumb or pacifier sucking, it may result in resolution as the habit is stopped. Habit deterrent appliances may be used to help in breaking digit and thumb sucking habits. Other treatment options for patients who are still growing include functional appliances and headgear appliances.

Tooth size discrepancy

[edit]

Identifying the presence of tooth size discrepancies between the maxillary and mandibular arches is an important component of correct orthodontic diagnosis and treatment planning.

To establish appropriate alignment and occlusion, the size of upper and lower front teeth, or upper and lower teeth in general, needs to be proportional. Inter-arch tooth size discrepancy (ITSD) is defined as a disproportion in the mesio-distal dimensions of teeth of opposing dental arches. The prevalence is clinically significant among orthodontic patients and has been reported to range from 17% to 30%.^[59]

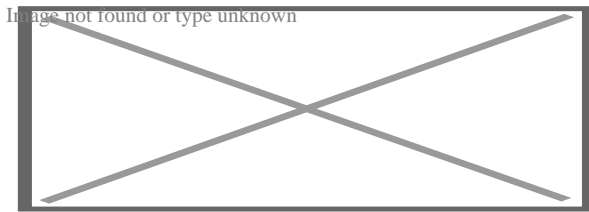
Identifying inter-arch tooth size discrepancy (ITSD) before treatment begins allows the practitioner to develop the treatment plan in a way that will take ITSD into account. ITSD corrective treatment may entail demanding reduction (interproximal wear), increase (crowns and resins), or elimination (extractions) of dental mass prior to treatment finalization.^[60]

Several methods have been used to determine ITSD. Of these methods the one most commonly used is the Bolton analysis. Bolton developed a method to calculate the ratio between the mesiodistal width of maxillary and mandibular teeth and stated that a correct and harmonious occlusion is possible only with adequate proportionality of tooth sizes.^[60] Bolton's formula concludes that if in the anterior portion the ratio is less than 77.2% the lower teeth are too narrow, the upper teeth are too wide or there is a combination of both. If the ratio is higher than 77.2% either the lower teeth are too wide, the upper teeth are too narrow or there is a combination of both.^[59]

Other conditions

[edit]

Further information: Open bite malocclusion



Open bite treatment after eight months of braces.

Other kinds of malocclusions can be due to or horizontal, vertical, or transverse skeletal discrepancies, including skeletal asymmetries.

Increased vertical growth causes a long facial profile and commonly leads to an open bite malocclusion, while decreased vertical facial growth causes a short facial profile and is commonly associated with a deep bite malocclusion. However, there are many other more common causes for open bites (such as tongue thrusting and thumb sucking) and likewise for deep bites.^{[61][62][63]}

The upper or lower jaw can be overgrown (macrognathia) or undergrown (micrognathia).^{[62][61][63]} It has been reported that patients with micrognathia are also affected by retrognathia (abnormal posterior positioning of the mandible or maxilla relative to the facial structure).^[62] These patients are majorly predisposed to a class II malocclusion. Mandibular macrognathia results in prognathism and predisposes patients to a class III malocclusion.^[64]

Most malocclusion studies to date have focused on Class III malocclusions. Genetic studies for Class II and Class I malocclusion are more rare. An example of hereditary mandibular prognathism can be seen amongst the Hapsburg Royal family where one third of the affected individuals with severe class III malocclusion had one parent with a similar phenotype ^[65]

The frequent presentation of dental malocclusions in patients with craniofacial birth defects also supports a strong genetic aetiology. About 150 genes are

associated with craniofacial conditions presenting with malocclusions.^[66]

Micrognathia is a commonly recurring craniofacial birth defect appearing among multiple syndromes.

For patients with severe malocclusions, corrective jaw surgery or orthognathic surgery may be carried out as a part of overall treatment, which can be seen in about 5% of the general population.^{[62][61][63]}

See also

[edit]

- Crossbite
- Elastics
- Facemask (orthodontics)
- Maximum intercuspation
- Mouth breathing
- Occlusion (dentistry)

References

[edit]

1. [^] "malocclusion". *Oxford English Dictionary (Online ed.)*. Oxford University Press. (Subscription or participating institution membership required.)
2. [^] Bell B (September 1965). "Paul G. Spencer". *American Journal of Orthodontics*. **51** (9): 693–694. doi:10.1016/0002-9416(65)90262-9. PMID 14334001.
3. [^] Gruenbaum T (2010). "Famous Figures in Dentistry". *Mouth – JASDA*. **30** (1): 18.
4. [^] Hurt MA (2012). "Weedon D. Weedon's Skin Pathology. 3rd ed. London: Churchill Livingstone Elsevier, 2010". *Dermatology Practical & Conceptual*. **2** (1): 79–82. doi:10.5826/dpc.0201a15. PMC 3997252.
5. [^] Borzabadi-Farahani, A (2011). "An Overview of Selected Orthodontic Treatment Need Indices". In Naretto, Silvano (ed.). *Principles in Contemporary Orthodontics*. IntechOpen Limited. pp. 215–236. doi:10.5772/19735. ISBN 978-953-307-687-4.

6. ^ "How genetics can affect your teeth". *Orthodontics Australia*. 2018-11-25. Retrieved 2020-11-16.
7. ^ Corruccini RS, Potter RH (August 1980). "Genetic analysis of occlusal variation in twins". *American Journal of Orthodontics*. **78** (2): 140–54. doi:10.1016/0002-9416(80)90056-1. PMID 6931485.
8. ^ Sarig, Rachel; Slon, Viviane; Abbas, Janan; May, Hila; Shpack, Nir; Vardimon, Alexander Dan; HersHKovitz, Israel (2013-11-20). "Malocclusion in Early Anatomically Modern Human: A Reflection on the Etiology of Modern Dental Misalignment". *PLOS ONE*. **8** (11): e80771. Bibcode:2013PLoSO...880771S. doi:10.1371/journal.pone.0080771. ISSN 1932-6203. PMC 3835570. PMID 24278319.
9. ^ Pajević, Tina; Juloski, Jovana; Glišić, Branislav (2019-08-29). "Malocclusion from the prehistoric to the medieval times in Serbian population: Dentoalveolar and skeletal relationship comparisons in samples". *Homo: Internationale Zeitschrift für die vergleichende Forschung am Menschen*. **70** (1): 31–43. doi:10.1127/homo/2019/1009. ISSN 1618-1301. PMID 31475289. S2CID 201203069.
10. ^ Moimaz SA, Garbin AJ, Lima AM, Lolli LF, Saliba O, Garbin CA (August 2014). "Longitudinal study of habits leading to malocclusion development in childhood". *BMC Oral Health*. **14** (1): 96. doi:10.1186/1472-6831-14-96. PMC 4126276. PMID 25091288.
11. ^ Klein ET (1952). "Pressure Habits, Etiological Factors in Malocclusion". *Am. J. Orthod.* **38** (8): 569–587. doi:10.1016/0002-9416(52)90025-0.
12. ^ Graber TM. (1963). "The "Three m's": Muscles, Malformation and Malocclusion". *Am. J. Orthod.* **49** (6): 418–450. doi:10.1016/0002-9416(63)90167-2. hdl:2027.42/32220. S2CID 57626540.
13. ^ Björk A, Helm S (April 1967). "Prediction of the age of maximum puberal growth in body height" (PDF). *The Angle Orthodontist*. **37** (2): 134–43. PMID 4290545.
14. ^ Brucker M (1943). "Studies on the Incidence and Cause of Dental Defects in Children: IV. Malocclusion" (PDF). *J Dent Res*. **22** (4): 315–321. doi:10.1177/00220345430220041201. S2CID 71368994.
15. ^ Calisti LJ, Cohen MM, Fales MH (1960). "Correlation between malocclusion, oral habits, and socio-economic level of preschool children". *Journal of Dental Research*. **39** (3): 450–4. doi:10.1177/00220345600390030501. PMID 13806967. S2CID 39619434.
16. ^ Subtelny JD, Subtelny JD (October 1973). "Oral habits--studies in form, function, and therapy". *The Angle Orthodontist*. **43** (4): 349–83. PMID 4583311.

17. ^ Aznar T, Galán AF, Marín I, Domínguez A (May 2006). "Dental arch diameters and relationships to oral habits". *The Angle Orthodontist*. **76** (3): 441–5. PMID 16637724.
18. ^ Yamaguchi H, Sueishi K (May 2003). "Malocclusion associated with abnormal posture". *The Bulletin of Tokyo Dental College*. **44** (2): 43–54. doi:10.2209/tdcpublication.44.43. PMID 12956088.
19. ^ Wellington M, Hall CB (February 2002). "Pacifier as a risk factor for acute otitis media". *Pediatrics*. **109** (2): 351–2, author reply 353. doi:10.1542/peds.109.2.351. PMID 11826228.
20. ^ Rovers MM, Numans ME, Langenbach E, Grobbee DE, Verheij TJ, Schilder AG (August 2008). "Is pacifier use a risk factor for acute otitis media? A dynamic cohort study". *Family Practice*. **25** (4): 233–6. doi:10.1093/fampra/cmn030. PMID 18562333.
21. ^ Hamish T (1990). *Occlusion*. Parkins, B. J. (2nd ed.). London: Wright. ISBN 978-0723620754. OCLC 21226656.
22. ^ Thilander B, Pena L, Infante C, Parada SS, de Mayorga C (April 2001). "Prevalence of malocclusion and orthodontic treatment need in children and adolescents in Bogota, Colombia. An epidemiological study related to different stages of dental development". *European Journal of Orthodontics*. **23** (2): 153–67. doi:10.1093/ejo/23.2.153. PMID 11398553.
23. ^ Borzabadi-Farahani A, Borzabadi-Farahani A, Eslamipour F (October 2009). "Malocclusion and occlusal traits in an urban Iranian population. An epidemiological study of 11- to 14-year-old children". *European Journal of Orthodontics*. **31** (5): 477–84. doi:10.1093/ejo/cjp031. PMID 19477970.
24. ^ "5 reasons you should see an orthodontist". *Orthodontics Australia*. 2017-09-27 . Retrieved 2020-08-18.
25. ^ **a b c** Oliver RG (December 2001). "An Introduction to Orthodontics, 2nd edn". *Journal of Orthodontics*. **28** (4): 320. doi:10.1093/ortho/28.4.320.
26. ^ **a b c** Millett DT, Cunningham SJ, O'Brien KD, Benson PE, de Oliveira CM (February 2018). "Orthodontic treatment for deep bite and retroclined upper front teeth in children". *The Cochrane Database of Systematic Reviews*. **2** (3): CD005972. doi:10.1002/14651858.cd005972.pub4. PMC 6491166. PMID 29390172.
27. ^ Brunelle JA, Bhat M, Lipton JA (February 1996). "Prevalence and distribution of selected occlusal characteristics in the US population, 1988-1991". *Journal of Dental Research*. **75** Spec No (2 Suppl): 706–13. doi:10.1177/002203459607502S10. PMID 8594094. S2CID 30447284.

28. ^ de Castilho LS, Abreu MH, Pires e Souza LG, Romualdo LT, Souza e Silva ME, Resende VL (January 2018). "Factors associated with anterior open bite in children with developmental disabilities". *Special Care in Dentistry*. **38** (1): 46–50. doi:10.1111/scd.12262. PMID 29278267. S2CID 42747680.
29. ^ Feres MF, Abreu LG, Insabralde NM, Almeida MR, Flores-Mir C (June 2016). "Effectiveness of the open bite treatment in growing children and adolescents. A systematic review". *European Journal of Orthodontics*. **38** (3): 237–50. doi:10.1093/ejo/cjv048. PMC 4914905. PMID 26136439.
30. ^ **a b** Cambiano AO, Janson G, Lorenzoni DC, Garib DG, Dávalos DT (2018). "Nonsurgical treatment and stability of an adult with a severe anterior open-bite malocclusion". *Journal of Orthodontic Science*. **7**: 2. doi:10.4103/jos.JOS_69_17. PMC 5952238. PMID 29765914.
31. ^ Houston, W. J. B. (1992-02-01). "Book Reviews". *The European Journal of Orthodontics*. **14** (1): 69. doi:10.1093/ejo/14.1.69.
32. ^ Hamdan AM, Lewis SM, Kelleher KE, Elhady SN, Lindauer SJ (November 2019). "Does overbite reduction affect smile esthetics?". *The Angle Orthodontist*. **89** (6): 847–854. doi:10.2319/030819-177.1. PMC 8109173. PMID 31306077.
33. ^ "Angle's Classification of Malocclusion". Archived from the original on 2008-02-13. Retrieved 2007-10-31.
34. ^ Sunil Kumar (Ed.): *Orthodontics*. New Delhi 2008, 624 p., ISBN 978–81–312–1054–3, p. 127
35. ^ Sunil Kumar (Ed.): *Orthodontics*. New Delhi 2008, p. 123. A list of 18 approaches to modify or replace Angle's system is given here with further references at the end of the book.
36. ^ Gurkeerat Singh: *Textbook of Orthodontics*, p. 163–170, with further references on p. 174.
37. ^ **a b c d** Lieberman, D (May 2004). "Effects of food processing on masticatory strain and craniofacial growth in a retrognathic face". *Journal of Human Evolution*. **46** (6): 655–77. doi:10.1016/s0047-2484(04)00051-x. PMID 15183669.
38. ^ **a b** Ingervall B, Bitsanis E (February 1987). "A pilot study of the effect of masticatory muscle training on facial growth in long-face children" (PDF). *European Journal of Orthodontics*. **9** (1): 15–23. doi:10.1093/ejo/9.1.15. PMID 3470182.
39. ^ **a b** Rosenberg J (2010-02-22). "Malocclusion of teeth". *Medline Plus*. Retrieved 2012-02-06.

40. ^ Victora CG, Bahl R, Barros AJ, França GV, Horton S, Krasevec J, Murch S, Sankar MJ, Walker N, Rollins NC (January 2016). "Breastfeeding in the 21st century: epidemiology, mechanisms, and lifelong effect". *Lancet*. 387 (10017): 475–90. doi:10.1016/s0140-6736(15)01024-7. PMID 26869575.
41. ^ Quaglio CL, de Freitas KM, de Freitas MR, Janson G, Henriques JF (June 2011). "Stability and relapse of maxillary anterior crowding treatment in class I and class II Division 1 malocclusions". *American Journal of Orthodontics and Dentofacial Orthopedics*. **139** (6): 768–74. doi:10.1016/j.ajodo.2009.10.044. PMID 21640883.
42. ^ a b "Dental Crowding: Causes and Treatment Options". *Orthodontics Australia*. 2020-06-29. Retrieved 2020-11-19.
43. ^ "Malocclusion of teeth: MedlinePlus Medical Encyclopedia". *medlineplus.gov*. Retrieved 2021-04-07.
44. ^ "Can Buck Teeth Be Fixed? Causes & Treatment Options". *Orthodontics Australia*. 2021-07-01. Retrieved 2021-10-11.
45. ^ a b Alam, MK (October 2018). "Treatment of Angle Class I malocclusion with severe crowding by extraction of four premolars: a case report". *Bangladesh Journal of Medical Science*. **17** (4): 683–687. doi:10.3329/bjms.v17i4.38339.
46. ^ Persson M, Persson EC, Skagius S (August 1989). "Long-term spontaneous changes following removal of all first premolars in Class I cases with crowding". *European Journal of Orthodontics*. **11** (3): 271–82. doi:10.1093/oxfordjournals.ejo.a035995. PMID 2792216.
47. ^ von Cramon-Taubadel N (December 2011). "Global human mandibular variation reflects differences in agricultural and hunter-gatherer subsistence strategies". *Proceedings of the National Academy of Sciences of the United States of America*. **108** (49): 19546–51. Bibcode:2011PNAS..10819546V. doi:10.1073/pnas.1113050108. PMC 3241821. PMID 22106280.
48. ^ Nayak KU, Goyal V, Malviya N (October 2011). "Two-phase treatment of class II malocclusion in young growing patient". *Contemporary Clinical Dentistry*. **2** (4): 376–80. doi:10.4103/0976-237X.91808. PMC 3276872. PMID 22346172.
49. ^ "Treatment of class ii malocclusions". 2013-11-14.
50. ^ a b c Pinhasi R, Eshed V, von Cramon-Taubadel N (2015-02-04). "Incongruity between affinity patterns based on mandibular and lower dental dimensions following the transition to agriculture in the Near East, Anatolia and Europe". *PLOS ONE*. **10** (2): e0117301. Bibcode:2015PLoSO..1017301P. doi:10.1371/journal.pone.0117301. PMC 4317182. PMID 25651540.

51. ^ **a b c d** Batista KB, Thiruvengkatachari B, Harrison JE, O'Brien KD (March 2018). "Orthodontic treatment for prominent upper front teeth (Class II malocclusion) in children and adolescents". *The Cochrane Database of Systematic Reviews*. **2018** (3): CD003452. doi:10.1002/14651858.cd003452.pub4. PMC 6494411. PMID 29534303.
52. ^ CLASSIFICATION OF SKELETAL AND DENTAL MALOCCLUSION: REVISITED; Mageet, Adil Osman (2016). "Classification of Skeletal and Dental Malocclusion: Revisited". *Stomatology Edu Journal*. **3** (2): 205–211. doi:10.25241/2016.3(2).11.
53. ^ *Esthetics and biomechanics in orthodontics*. Nanda, Ravindra,, Preceded by (work): Nanda, Ravindra. (Second ed.). St. Louis, Missouri. 2014-04-10. ISBN 978-0-323-22659-2. OCLC 880707123.cite book: CS1 maint: location missing publisher (link) CS1 maint: others (link)
54. ^ Eslami S, Faber J, Fateh A, Sheikholaemmeh F, Grassia V, Jamilian A (August 2018). "Treatment decision in adult patients with class III malocclusion: surgery versus orthodontics". *Progress in Orthodontics*. **19** (1): 28. doi:10.1186/s40510-018-0218-0. PMC 6070451. PMID 30069814.
55. ^ **a b** Uner O, Yüksel S, Uçuncü N (April 1995). "Long-term evaluation after chin-cap treatment". *European Journal of Orthodontics*. **17** (2): 135–41. doi:10.1093/ejo/17.2.135. PMID 7781722.
56. ^ Ravi MS, Shetty NK, Prasad RB (January 2012). "Orthodontics-surgical combination therapy for Class III skeletal malocclusion". *Contemporary Clinical Dentistry*. **3** (1): 78–82. doi:10.4103/0976-237X.94552. PMC 3341765. PMID 22557903.
57. ^ Borzabadi Farahani A, Olkun HK, Eslamian L, Eslamipour F (2024). "A retrospective investigation of orthognathic patients and functional needs". *Australasian Orthodontic Journal*. **40**: 111–120. doi:10.2478/aoj-2024-0013.
58. ^ **a b** Atsawasuwan P, Hohlt W, Evans CA (April 2015). "Nonsurgical approach to Class I open-bite malocclusion with extrusion mechanics: a 3-year retention case report". *American Journal of Orthodontics and Dentofacial Orthopedics*. **147** (4): 499–508. doi:10.1016/j.ajodo.2014.04.024. PMID 25836010.
59. ^ **a b** Grauer D, Heymann GC, Swift EJ (June 2012). "Clinical management of tooth size discrepancies". *Journal of Esthetic and Restorative Dentistry*. **24** (3): 155–9. doi:10.1111/j.1708-8240.2012.00520.x. PMID 22691075. S2CID 11482185.
60. ^ **a b** Cançado RH, Gonçalves Júnior W, Valarelli FP, Freitas KM, Crêspo JA (2015). "Association between Bolton discrepancy and Angle malocclusions". *Brazilian Oral Research*. **29**: 1–6. doi:10.1590/1807-3107BOR-2015.vol29.0116.

PMID 26486769.

61. ^ **a b c** Harrington C, Gallagher JR, Borzabadi-Farahani A (July 2015). "A retrospective analysis of dentofacial deformities and orthognathic surgeries using the index of orthognathic functional treatment need (IOFTN)". *International Journal of Pediatric Otorhinolaryngology*. **79** (7): 1063–6. doi:10.1016/j.ijporl.2015.04.027. PMID 25957779.
62. ^ **a b c d** Posnick JC (September 2013). "Definition and Prevalence of Dentofacial Deformities". *Orthognathic Surgery: Principles and Practice*. Amsterdam: Elsevier. pp. 61–68. doi:10.1016/B978-1-4557-2698-1.00003-4. ISBN 978-145572698-1.
63. ^ **a b c** Borzabadi-Farahani A, Eslamipour F, Shahmoradi M (June 2016). "Functional needs of subjects with dentofacial deformities: A study using the index of orthognathic functional treatment need (IOFTN)". *Journal of Plastic, Reconstructive & Aesthetic Surgery*. **69** (6): 796–801. doi:10.1016/j.bjps.2016.03.008. PMID 27068664.
64. ^ Purkait, S (2011). *Essentials of Oral Pathology 4th Edition*.
65. ^ Joshi N, Hamdan AM, Fakhouri WD (December 2014). "Skeletal malocclusion: a developmental disorder with a life-long morbidity". *Journal of Clinical Medicine Research*. **6** (6): 399–408. doi:10.14740/jocmr1905w. PMC 4169080. PMID 25247012.
66. ^ Moreno Uribe LM, Miller SF (April 2015). "Genetics of the dentofacial variation in human malocclusion". *Orthodontics & Craniofacial Research*. **18** Suppl 1 (S1): 91–9. doi:10.1111/ocr.12083. PMC 4418210. PMID 25865537.

Further reading

[edit]

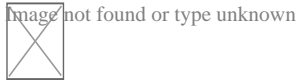
- Peter S. Ungar, "The Trouble with Teeth: Our teeth are crowded, crooked and riddled with cavities. It hasn't always been this way", *Scientific American*, vol. 322, no. 4 (April 2020), pp. 44–49. "Our teeth [...] evolved over hundreds of millions of years to be incredibly strong and to align precisely for efficient chewing. [...] Our dental disorders largely stem from a shift in the oral environment caused by the introduction of softer, more sugary foods than the ones our ancestors typically ate."

External links

[edit]

Classification

- **ICD-10:** K07.3, K07.4, K07.5, D K07.6
- **ICD-9-CM:** 524.4
- **MeSH:** D008310



Wikimedia Commons has media related to ***Malocclusion***.

- v
- t
- e

Orthodontics

Diagnosis

- Bolton analysis
- Cephalometric analysis
- Cephalometry
- Dentition analysis
- Failure of eruption of teeth
- Little's Irregularity Index
- Malocclusion
- Scissor bite
- Standard anatomical position
- Tooth ankylosis
- Tongue thrust

Conditions

- Overbite
- Overjet
- Open bite
- Crossbite
- Dental crowding
- Dental spacing
- Bimaxillary Protrusion
- Prognathism
- Retrognathism
- Maxillary hypoplasia
- Condylar hyperplasia
- Overeruption
- Mouth breathing
- Temporomandibular dysfunction

- ACCO appliance
- Archwire
- Activator appliance
- Braces
- Damon system
- Elastics
- Frankel appliance
- Invisalign
- Lingual arch
- Lip bumper
- Herbst Appliance
- List of orthodontic functional appliances
- List of palatal expanders
- Lingual braces
- Headgear
- Orthodontic technology
- Orthodontic spacer
- Palatal lift prosthesis
- Palatal expander
- Quad helix
- Retainer
- SureSmile
- Self-ligating braces
- Splint activator
- Twin Block Appliance

Appliances

Procedures

- Anchorage (orthodontics)
- Cantilever mechanics
- Fiberotomy
- Interproximal reduction
- Intrusion (orthodontics)
- Molar distalization
- SARPE
- Serial extraction

Materials

- Beta-titanium
- Nickel titanium
- Stainless steel
- TiMolium
- Elgiloy
- Ceramic
- Composite
- Dental elastics

- Edward Angle
- Spencer Atkinson
- Clifford Ballard
- Raymond Begg
- Hans Peter Bimler
- Samir Bishara
- Arne Björk
- Charles B. Bolton
- Holly Broadbent Sr.
- Allan G. Brodie
- Charles J. Burstone
- Peter Buschang
- Calvin Case
- Harold Chapman (Orthodontist)
- David Di Biase
- Jean Delaire
- Terry Dischinger
- William B. Downs
- John Nutting Farrar
- Rolf Frankel
- Sheldon Friel
- Thomas M. Graber
- Charles A. Hawley
- Reed Holdaway
- John Hooper (Orthodontist)
- Joseph Jarabak
- Harold Kesling
- Albert Ketcham
- Juri Kurol
- Craven Kurz
- Benno Lischer
- James A. McNamara
- Birte Melsen
- Robert Moyers

**Notable
contributors**

- American Association of Orthodontists
- American Board of Orthodontics
- British Orthodontic Society
- Organizations**
 - Canadian Association of Orthodontists
 - Indian Orthodontic Society
 - Italian Academy of Orthodontic Technology
 - Society for Orthodontic Dental Technology (Germany)
 - American Journal of Orthodontics and Dentofacial Orthopedics
- Journals**
 - The Angle Orthodontist
 - Journal of Orthodontics
- Institution**
 - Angle School of Orthodontia

- v
- t
- e

Dental disease involving the jaw

- General**
 - Jaw abnormality
 - malocclusion
 - Orthodontics
 - Gnathitis
- Size**
 - Micrognathism
 - Maxillary hypoplasia
 - Cherubism
- Maxilla and Mandible**
 - Congenital epulis
 - Torus mandibularis
 - Torus palatinus

Other

- Jaw and base of cranium
 - Prognathism
 - Retrognathism
- Dental arch
 - Crossbite
 - Overbite
- Temporomandibular joint disorder

Check our other pages :

- [Streamlining Communication Among Healthcare Providers](#)
- [Balancing Cosmetic Goals and Functional Needs](#)
- [Building a Unified Strategy for Long Term Stability](#)

IQDENT – Ortodontska Klinika

Phone : +385953817015

City : Zagreb

State : Hrvatska

Zip : 10000

Address : IQDENT – Ortodontska Klinika

Company Website : <https://iqdent.hr/>

USEFUL LINKS

[Orthodontic treatment can help improve your child's smile](#)

[Orthodontic treatment for children](#)

[Sitemap](#)

[Privacy Policy](#)

[About Us](#)

Follow us