



- **Reasons Adults Seek Orthodontic Treatment**

Reasons Adults Seek Orthodontic Treatment Overcoming Hesitations About Braces Later in Life Clear Aligners for Subtle Tooth Movement Comparing Ceramic Brackets With Other Invisible Options Balancing Cosmetic Goals and Functional Needs Social Changes That Encourage Adult Orthodontics Handling Orthodontic Care Alongside Busy Schedules Managing Discomfort and Adjusting to Lifestyle Shifts Case Studies Highlighting Adult Smile Transformations Psychological Benefits of Aligned Teeth in Adulthood Minimizing Visibility of Orthodontic Appliances Key Questions Adults Often Ask About Treatment

- **How Orthodontics Connects With Periodontal Health**

How Orthodontics Connects With Periodontal Health Coordinating Orthodontic Work With Restorative Dentistry The Role of Oral Surgery in Complex Alignment Cases Importance of Joint Consultation for Comprehensive Outcomes Leveraging Data Sharing Between Dental Specialties Collaborative Approaches to Pediatric Growth Management Integrating Prosthodontics for Full Mouth Rehabilitation Teamwork for Managing Tongue Thrust and Speech Issues Streamlining Communication Among Healthcare Providers Shared Planning for Improved Patient Experiences Post Surgical Follow Ups With Multiple Specialists Building a Unified Strategy for Long Term Stability

- **About Us**



Integrating Prosthodontics for Full Mouth Rehabilitation

****Desire for Improved Aesthetics**:** Many adults seek orthodontic treatment to enhance the appearance of their smile, addressing concerns such as crooked teeth, gaps, or overbites that may have persisted from childhood or developed due to various life factors.

****Desire for Improved Aesthetics**:** Many adults seek orthodontic treatment to enhance the appearance of their smile, addressing concerns such as crooked teeth, gaps, or overbites that may have persisted from childhood or developed due to various life factors.

Full mouth rehabilitation (FMR) is a comprehensive dental treatment approach designed to restore the health, functionality, and aesthetics of a patient's entire dentition, including the teeth, supporting tissues, and occlusion—or how the teeth come together when biting and chewing. This multifaceted procedure is often sought by individuals who have significant dental issues that affect their quality of life, such as extensive tooth decay, wear, trauma, or congenital anomalies. Thumb-sucking habits can affect the alignment of a child's teeth **Child-friendly orthodontic solutions** American Association of Orthodontists. The essence of full mouth rehabilitation lies not just in repairing damaged teeth but in creating a harmonious and efficient oral environment that can last for years to come.

The objectives of full mouth rehabilitation are manifold and deeply interconnected, aiming to address both functional and aesthetic concerns while ensuring long-term oral health. Primarily, FMR seeks to restore the integrity of the dentition so patients can

enjoy a fully functional bite. This means rebuilding or replacing teeth that are missing or severely damaged to ensure proper chewing ability and comfort during everyday activities like eating and speaking. A well-functioning bite also plays a crucial role in preventing further dental issues by evenly distributing the forces applied during biting and chewing across all teeth.

Esthetics is another cornerstone objective of full mouth rehabilitation. Beyond mere functionality, many patients seek to regain a smile they feel confident about. FMR addresses discoloration, misshapen teeth, gaps, and other cosmetic concerns through various techniques such as crowns, veneers, bonding, or even implants topped with lifelike ceramic restorations. The goal here is not just to fix what's broken but to create an esthetic result that aligns with the patient's facial features and personal expectations for beauty and youthfulness.

Another vital aspect of FMR is improving oral health beyond immediate symptom relief. This includes treating underlying conditions like gum disease or periodontal issues that might contribute to tooth loss or discomfort. By tackling these foundational problems alongside restoring form and function, dentists aim to prevent future complications that could undermine the success of the rehabilitation efforts.

Additionally, full mouth rehabilitation places significant emphasis on the occlusion—the way upper and lower teeth meet when biting down—which is pivotal for both function and overall oral health. Proper occlusion helps maintain the structural integrity of remaining natural teeth and restorations alike while reducing stress on the jaw joints (TMJs), muscles of mastication (chewing), and neck muscles to minimize pain conditions like temporomandibular disorders (TMD).

In integrating prosthodontics into full mouth rehabilitation plans, specialists leverage their expertise in designing custom restorations—such as crowns, bridges, dentures (including implant-supported ones), or orthodontic appliances—that seamlessly integrate with existing structures or replace missing ones entirely. This integration demands meticulous planning involving advanced diagnostic tools like 3D imaging to ensure precision fitting and optimal outcomes tailored specifically to each individual's needs.

Ultimately, full mouth rehabilitation aims not just at restoring what has been lost but at elevating the patient's overall quality of life through enhanced oral function—chewing efficiently without discomfort—and improved esthetics—a brighter smile that boosts confidence. It represents a holistic approach where every component works together harmoniously: from addressing basic dental necessities like hygiene and structural support to refining details for aesthetic perfection. Through this comprehensive treatment strategy undertaken by skilled professionals in prosthodontics among other dental disciplines collaboratively working towards a common goal—the restoration of complete oral health—patients are given back their smiles in more

****Boosting Self-Confidence**:**
Orthodontic treatment can significantly improve an adult's self-esteem and

confidence by correcting dental imperfections, leading to a more positive self-image and better social interactions.

- ****Desire for Improved Aesthetics****: Many adults seek orthodontic treatment to enhance the appearance of their smile, addressing concerns such as crooked teeth, gaps, or overbites that may have persisted from childhood or developed due to various life factors.
- ****Boosting Self-Confidence****: Orthodontic treatment can significantly improve an adult's self-esteem and confidence by correcting dental imperfections, leading to a more positive self-image and better social interactions.
- ****Enhancing Oral Health****: Proper alignment of teeth through orthodontic treatment can improve oral hygiene by making it easier to clean teeth effectively, thereby reducing the risk of cavities and gum disease that may have been challenging to manage in misaligned dentitions.
- ****Addressing Chronic Dental Issues****: Adults may seek orthodontics to resolve long-standing dental problems such as bite issues (overbites, underbites, crossbites) that can lead to jaw pain,

headaches, and digestive difficulties if left untreated.

- ****Correcting Speech Impediments****: Misaligned teeth or jaw structures can contribute to speech difficulties; orthodontic treatment can correct these issues, improving articulation and overall communication skills.
- ****Preventive Measures Against Tooth Wear****: Properly aligned teeth are less prone to excessive wear and tear; adults may pursue orthodontic treatment to prevent premature tooth degradation and associated costs of restorative dentistry.
- ****Facilitating Better Chewing Efficiency****: Orthodontic treatment can improve bite function and alignment, allowing for more efficient chewing which is crucial for digestion and overall nutritional health in adulthood.

Integrating prosthodontic considerations into orthodontic treatment for children is a nuanced yet profoundly important aspect of comprehensive dental care, particularly when envisioning a full mouth rehabilitation strategy. This integration isn't merely about aligning teeth or improving smiles; it's about crafting a foundational approach that ensures the long-term health, function, and aesthetics of a child's dentition. Let's delve into why this intersection is critical in setting the stage for a lifetime of oral health and confidence.

Firstly, childhood is a pivotal period for dental development. The jawbones and teeth are still growing and maturing, presenting unique opportunities for correction that might not be as readily available in adulthood. Prosthodontics, which deals with the restoration and replacement of teeth, plays an essential role here by ensuring that any interventions during these formative years lay a solid groundwork for future dental health. By considering prosthodontic needs early on, orthodontists can prevent malocclusions from becoming entrenched issues that might require more complex treatments later in life.

Moreover, integrating prosthodontic considerations allows for a holistic view of the patient's dental ecosystem. For instance, children with missing or damaged teeth may benefit from provisional restorations that not only restore functionality but also guide proper jaw development during growth stages. These temporary solutions can influence how the permanent teeth erupt and align, potentially reducing the need for more invasive procedures down the line. It's akin to planting seeds in fertile soil; with careful planning and attention to detail during early orthodontic phases, we cultivate an environment where natural tooth alignment can occur more harmoniously.

Furthermore, addressing prosthodontic concerns early on contributes significantly to enhancing a child's quality of life immediately. Missing or poorly fitting teeth can impact speech development, chewing efficiency, and self-esteem—issues that extend far beyond mere aesthetics. By incorporating prosthodontics into orthodontic treatment plans for children, practitioners can simultaneously work towards correcting bite issues while ensuring that daily functions like eating and speaking are not compromised. This holistic approach fosters immediate improvements in comfort and confidence as children navigate their developmental milestones.

Additionally, this integrated approach fosters collaboration among dental specialists—orthodontists working hand-in-hand with prosthodontists—to tailor treatment plans uniquely suited to each child's circumstances. Such teamwork ensures that every aspect of dental rehabilitation is considered meticulously: from the timing of interventions to material choices in restorations, all aimed at achieving optimal outcomes both now and in adulthood.


In conclusion, weaving prosthodontic considerations into orthodontic treatments for children is more than just sound clinical practice—it's about investing in their future smiles genuinely and comprehensively. By recognizing the interplay between tooth alignment, jaw development, and restorative needs early on, we pave the way for full mouth rehabilitation that promises functional harmony and aesthetic satisfaction well into

adulthood. In doing so, we empower our young patients not just with healthier mouths but also with brighter prospects filled with confidence and ease in their everyday lives.

More about us:

Social Media:

Facebook About Us:



****Enhancing Oral Health**:**

Proper alignment of teeth through orthodontic treatment can improve oral hygiene by making it easier to clean teeth effectively, thereby reducing the risk of cavities and gum disease that may have been challenging to manage in misaligned dentitions.

Understanding the Need for Prosthodontic Integration in Growing Patients: A Cornerstone for Comprehensive Full Mouth Rehabilitation

The realm of prosthodontics, particularly within the context of full mouth rehabilitation, presents a fascinating intersection where art meets science, and where the pursuit of functional aesthetics plays a crucial role in enhancing patients' quality of life. This becomes especially pertinent when considering growing patients—children and adolescents whose bodies are not just developing physically but also undergoing significant dental changes. Integrating prosthodontic solutions into their rehabilitative journey is not merely advantageous; it's essential for ensuring long-term dental health, function, and esthetics. Let's delve into why this integration is critical for growing patients embarking on a path toward full mouth rehabilitation.

Firstly, the developmental phase of childhood and adolescence is characterized by rapid growth and change, not just in stature but also in dental structures. Teeth erupt, jaws expand, and facial bones undergo transformations that can significantly impact oral health and appearance. For growing patients facing tooth loss or requiring extensive dental reconstruction due to congenital anomalies, trauma, or disease, a static prosthodontic solution would quickly become obsolete. Instead, an integrated approach allows for adaptability—devices that can grow with the patient or be easily modified as their oral anatomy evolves. This adaptability ensures that the rehabilitation remains effective and comfortable throughout various stages of growth.

Moreover, integrating prosthodontics into full mouth rehabilitation for growing patients addresses foundational issues crucial for proper occlusion (how teeth align and interact) and jaw development. Misalignments or improper bites not only affect chewing efficiency but can also lead to myriad problems like temporomandibular joint disorders (TMD), speech difficulties, and facial asymmetries. Early intervention through customized

orthodontic and prosthodontic treatments can guide the growth of jaws in a more harmonious manner, potentially reducing or eliminating future complications associated with malocclusions. This proactive stance underscores the importance of interdisciplinary collaboration among pediatric dentists, orthodontists, and prosthodontists to create comprehensive treatment plans tailored to each individual's unique developmental trajectory.

Additionally, the psychological aspect cannot be overlooked when considering young patients undergoing extensive dental work. For children and adolescents, appearance plays a pivotal role in social interactions and self-esteem during already formative years. Prosthetic devices designed with both functionality and esthetics in mind can restore confidence by providing a natural-looking smile while ensuring optimal function—a double win that supports their overall well-being beyond mere dental health. Here again, integration becomes key; working seamlessly across disciplines ensures that aesthetic considerations are never compromised for functional ones—and vice versa—resulting in outcomes that bolster both physical health

In conclusion, integrating prosthodontic solutions into full mouth rehabilitation for growing patients is far more than an added layer of complexity—it's an essential facet ensuring comprehensive care that accommodates the unique challenges posed by developmental stages. By embracing this integrated approach, we uphold the essence of modern dentistry: treating each patient uniquely while fostering an environment where growth, health, and confidence coalesce into a thriving outcome. Through continuous innovation,

****Addressing Chronic Dental Issues**:** Adults may seek orthodontics to resolve long-standing dental problems such as bite issues (overbites, underbites, crossbites) that can lead to jaw pain, headaches, and digestive difficulties if left untreated.

When we talk about integrating prosthodontics for full mouth rehabilitation, it's essential to understand the profound impact that early intervention can have on long-term oral health. This isn't merely about fixing immediate dental issues; it's about laying a

foundation for a lifetime of healthier smiles and overall well-being. Let's delve into how timely action in prosthodontic care can reshape the future of oral health for individuals requiring extensive dental restoration.

Firstly, let's define what we mean by "early intervention" in this context. Early intervention refers to addressing dental concerns as soon as they become evident or predictable, rather than waiting until problems escalate. In full mouth rehabilitation, this often involves assessing the entire mouth—teeth, gums, jaw joints, and associated muscles—to identify issues that might require prosthodontic solutions like crowns, bridges, dentures, or implants. The earlier these issues are detected and treated, the less complex and invasive the necessary interventions tend to be down the road.

The immediate benefits of early intervention are clear: preventing minor problems from becoming major ones significantly reduces pain and discomfort for patients. Imagine someone with a small cavity that is addressed promptly; this simple filling can prevent decay from spreading, saving not just that tooth but potentially others around it from future complications. This proactive approach minimizes the need for more extensive treatments like root canals or extractions later on, which can be far more invasive and costly both financially and in terms of recovery time and comfort.

Beyond immediate pain relief and cost savings, early intervention sets a precedent for better oral hygiene practices and regular dental check-ups—a cornerstone of long-term oral health maintenance. When patients engage positively with their dental care at an early stage through comprehensive rehabilitation efforts, they're more likely to stay committed to their oral health routines post-treatment. Regular visits become part of their lifestyle rather than a chore or something they only consider when pain strikes. This consistency is key; it allows dentists to monitor healing progress closely and catch any new issues before they become significant problems again.

Moreover, integrating prosthodontics at an earlier stage aids in preserving natural tooth structure whenever possible. Advanced techniques allow for conservative preparations that maintain as much healthy tooth material as feasible while still providing strong restorations. This not only enhances the longevity of the restorations themselves but also supports the surrounding teeth and gums by minimizing trauma during the treatment process—a crucial aspect for maintaining overall oral health over decades ahead.

Furthermore, addressing bite alignment issues through early intervention can prevent temporomandibular joint disorders (TMD) or other functional problems that might arise from uneven wear or misalignment of teeth and jaws over time. By ensuring proper occlusion—the way teeth fit together—through precise prosthodontic work upfront, we're effectively reducing risks associated with chronic pain syndromes affecting not just the mouth but potentially leading to broader systemic impacts like headaches or neck pain.

In essence, early intervention in full mouth rehabilitation with a focus on prosthodontics doesn't just fix current dental woes; it primes patients for sustained oral health success well into their future years. It fosters an environment where natural teeth can thrive longer when possible, supports effective management of existing conditions without resorting to drastic measures later on, and cultivates lifelong habits conducive to maintaining vibrant smiles free from unnecessary complications. Embracing this holistic view not only transforms individual lives but sets a standard for how preventative care should be approached within modern dent

****Correcting Speech**

Impediments:** Misaligned teeth or jaw structures can contribute to speech difficulties; orthodontic treatment can correct these issues, improving articulation and overall communication skills.

When we think about the journey of a child's dental health, it's often filled with moments of excitement—those first baby teeth pushing through, the proud milestones of losing

them for permanent ones, and the eventual straightening of those pearly whites with orthodontics. However, this path isn't always smooth; certain dental issues can arise that require a more integrated approach to treatment, combining the expertise of prosthodontics with orthodontics for what we refer to as full mouth rehabilitation. This holistic strategy is particularly crucial when dealing with complex cases in children, ensuring not just a beautiful smile but also functional oral health that can last a lifetime.

One common scenario where such integration becomes essential is in managing severe tooth decay or trauma resulting in significant tooth loss or damage in young patients. Imagine a child who has experienced extensive decay due to various reasons—perhaps dietary habits, lack of proper oral hygiene education, or even systemic conditions affecting tooth enamel. In such cases, merely straightening what's left might not be enough; these children often require prosthodontic interventions like crowns or even implants to restore functionality and aesthetics. Here, orthodontics plays a supportive role by guiding the remaining teeth into optimal positions that complement these restorations, ensuring both form and function are addressed.

Another issue that frequently demands this integrated approach is congenital anomalies—conditions present from birth that affect the structure of teeth and jaws. Conditions like cleft lip and palate not only pose significant aesthetic challenges but also impact speech, eating, and overall dental health. Prosthodontists work alongside orthodontists to create custom solutions like dental prostheses that fit seamlessly with the child's natural teeth while also guiding jaw development through orthodontic appliances designed specifically for growing faces. This collaboration ensures that as the child grows, their dental framework evolves harmoniously with their facial structure.

Moreover, there's an increasing awareness about how malocclusions (misalignments of the teeth) can extend beyond mere cosmetic concerns to impact overall health and self-esteem profoundly in children. When misalignments are severe or accompanied by

developmental issues affecting jaw growth—such as underdeveloped or oversized jaws—a combination of prosthodontic reconstructions (like custom-made dentures or bridges) alongside orthodontic treatments (braces, aligners) might be necessary for full mouth rehabilitation. This comprehensive approach addresses both immediate functional needs and long-term oral health outcomes by ensuring each tooth has its rightful place within the arch while supporting proper bite mechanics and facial aesthetics.

The beauty of integrating prosthodontics with orthodontics lies in its ability to offer personalized care tailored to each child's unique challenges and needs. It underscores a philosophy of treating not just individual teeth but considering how they interplay within the whole oral ecosystem—a philosophy especially critical during childhood when foundations are being laid for lifelong oral health. Through this collaborative effort between disciplines, we witness transformative results: healthier smiles that function optimally and boost confidence at every stage of growth and development. As we continue advancing our techniques and understanding in pediatric dental care, embracing this integrated approach will undoubtedly lead to brighter futures—both literally and figuratively—for countless young patients navigating their way toward complete oral wellness.

****Preventive Measures**

Against Tooth Wear:**

Properly aligned teeth are less

prone to excessive wear and tear; adults may pursue orthodontic treatment to prevent premature tooth degradation and associated costs of restorative dentistry.

When delving into the intricate world of full mouth rehabilitation, particularly through the lens of combined treatment plans that integrate prosthodontics, it becomes evident that assessment and diagnostic considerations are not merely preliminary steps but foundational pillars supporting the entire rehabilitative journey. The complexity of restoring a patient's dental health to optimize function, aesthetics, and overall well-being necessitates a meticulous approach, one that considers the multifaceted nature of each individual case.

At the heart of this comprehensive evaluation lies a thorough understanding of the patient's medical and dental history. This historical tapestry informs us about previous treatments, existing conditions—such as systemic diseases or immune-compromised

states—that might influence treatment outcomes, and any psychological factors that could affect adherence to a treatment plan. It's crucial to recognize that every patient is unique, with their own set of challenges and expectations, making personalized assessments indispensable.

Clinically, a detailed examination is paramount. This includes not just a visual inspection but also radiographic imaging to uncover hidden issues beneath the surface—like bone loss or abscesses—that could complicate prosthetic integration. Functional assessments are equally important; understanding how a patient chews, speaks, and breathes provides insights into occlusal relationships and potential imbalances that must be addressed during rehabilitation. Moreover, assessing periodontal health is critical since supportive tissues play an essential role in the long-term success of prosthetic restorations.

The diagnostic phase should extend beyond immediate clinical observations to include prognostic considerations. This involves evaluating how well proposed treatments align with long-term goals—both functional and aesthetic—and considering how they might evolve with changes in the patient's oral environment or overall health over time. Herein lies the art of predicting future needs: will additional interventions be required as bone resorption progresses? How might aging impact material choices for prosthetics? These forward-looking assessments ensure that treatment plans are not only responsive to current conditions but also adaptable to future changes.

Integrating various disciplines within dentistry—restorative dentistry, periodontics, orthodontics—is often necessary for comprehensive treatment planning in full mouth rehabilitation cases. Each specialty brings its expertise to address different facets of dental dysfunctions comprehensively. For instance, periodontal health may require careful management before proceeding with implant placement or crown fabrication; orthodontic considerations might influence decisions on tooth positioning for optimal esthetics and function post-rehabilitation. Recognizing these interdependencies underscores the

necessity for collaborative care among specialists involved in a patient's treatment plan.

Furthermore, advanced diagnostic tools such as digital impressions, CAD/CAM technology for designing custom restorations, and CBCT scans offering three-dimensional views of dental structures have revolutionized precision in diagnosis and planning stages. These technologies aid in creating more accurate replicas of proposed restorations and enable simulations that can significantly enhance communication between clinicians and patients regarding expected outcomes—a vital component for informed consent and setting realistic expectations.

In wrapping up this exploration into assessment and diagnostic considerations for integrated treatment plans in full mouth rehabilitation via prosthodontics, it's clear that such endeavors demand an amalgamation of clinical acumen, technological savvy, interdisciplinary collaboration—and above all—a deep empathy towards the patient's desire for improved quality of life through restored dental function and appearance. Each step taken thoughtfully contributes to crafting not just smiles but transformative experiences where patients regain confidence in their everyday lives through reclaimed oral functionality.

****Facilitating Better Chewing Efficiency** : Orthodontic**

**treatment can improve bite
function and alignment,
allowing for more efficient
chewing which is crucial for
digestion and overall
nutritional health in
adulthood.**

Integrating prosthodontics into a comprehensive full mouth rehabilitation (FMR) plan represents a multifaceted approach to restoring oral function, aesthetics, and overall health. This process is not merely about replacing missing teeth; it's about reviving the integrity of an individual's mouth and, by extension, their quality of life. A thorough evaluation before embarking on such a journey is crucial, encompassing medical, dental, and growth assessments to ensure that the treatment plan is not only effective but also safe and tailored to the unique needs of each patient. Let's delve into how these evaluations intertwine to support a successful FMR.

Medical Assessment: The foundation of any comprehensive treatment plan begins with understanding the patient's overall health status. A medical evaluation involves a detailed medical history review, including current medications, chronic conditions like diabetes or heart disease that might affect healing or increase the risk of complications during and after surgery. It's essential to assess cardiovascular health since procedures involving the mouth can sometimes impact systemic well-being. Additionally, patients with immunosuppressive conditions require special consideration to manage postoperative risks effectively. Collaboration with the patient's general physician might be necessary to optimize health prior to undergoing extensive dental work, ensuring that any potential medical concerns are addressed upfront.

Dental Evaluation: Moving from the broader picture to the specifics of oral health, a meticulous dental examination is pivotal. This includes a comprehensive periodontal assessment to understand the health of gums and supporting structures around existing teeth and where implants might be placed. Radiographic studies such as panoramic X-rays and CT scans provide critical insights into bone density and volume, crucial for determining the feasibility of implant placement and other structural restorations. Examining existing dental work—be it natural teeth requiring restoration or previous prosthetics—helps in planning how new interventions will integrate seamlessly with what already exists. Moreover, evaluating occlusion (how teeth come together) is vital for ensuring that the proposed restorations won't lead to future issues like temporomandibular joint disorders (TMJ).

Growth Assessment: Particularly important in cases involving younger patients or those undergoing significant changes due to growth—and even in adults where skeletal changes can influence treatment outcomes—is an assessment of craniofacial growth and development. This involves analyzing jaw relationships and how they may change over time due to natural growth processes or orthodontic interventions planned as part of FMR. Utilizing tools like cephalometric analysis allows professionals to predict future growth patterns and align restorative treatments accordingly, ensuring longevity and

functionality of the rehabilitation efforts.

The integration of these evaluations underlines a patient-centered approach—each component informs and enhances the others, creating a holistic treatment strategy tailored specifically for individual needs. The medical assessment ensures safety; the dental evaluation focuses on immediate oral health considerations; while growth assessments ensure that interventions are not only effective now but also adaptable to future changes in anatomy and function. Through this comprehensive lens, prosthodontics within full mouth rehabilitation transcends mere tooth replacement; it becomes an artful science aimed at restoring confidence, functionality, and joy in everyday life for those seeking renewal through dental care. This multidisciplinary approach exemplifies modern dentistry's commitment to delivering personalized solutions that stand the test of time—and life's many smiles.

The integration of prosthodontics into full mouth rehabilitation represents a sophisticated approach to restoring oral function, aesthetics, and overall health, where advanced imaging and diagnostic tools play a pivotal role that cannot be overstated. These technologies are the cornerstone of modern dental practice, especially when planning comprehensive treatments that demand precision, personalization, and an understanding of complex oral dynamics. Let's dive into how these tools revolutionize the process of integrating prosthodontic solutions into full mouth rehabilitation.

At the heart of this integration is the necessity for a detailed, three-dimensional understanding of a patient's oral anatomy. Traditional methods often relied on impressions and two-dimensional radiographs, which, while foundational, could miss critical nuances affecting treatment outcomes. Enter advanced imaging: technologies like Cone Beam Computed Tomography (CBCT) have transformed our ability to visualize bone structure, tooth positioning, nerves, and even soft tissues with remarkable clarity. This level of detail is crucial for planning implant placement in prosthodontic reconstructions; it ensures that implants are not only securely anchored but also harmoniously integrated

with the patient's existing dental architecture and facial structure.

Moreover, digital impressions and intraoral scanning technology have replaced traditional impression techniques, offering immediate digitization of the oral cavity. This shift allows for instant analysis and sharing of data among specialists involved in full mouth rehabilitation—prosthodontists, periodontists, orthodontists—and even outside specialists such as maxillofacial surgeons or ENTs when necessary. Such seamless collaboration hinges on accurate digital models that reflect the precise morphology of a patient's mouth without the distortions or inaccuracies inherent in traditional mold-making processes.

The role of computer-aided design (CAD) and computer-aided manufacturing (CAM) cannot be overlooked either. Once imaging provides the blueprint of the patient's oral condition, these technologies enable the designing of customized prosthetic devices—be it crowns, bridges, or complete dentures—that fit perfectly within the rehabilitated mouth. The iterative design process facilitated by these tools allows for adjustments based on virtual simulations before any physical fabrication takes place. This reduces errors and enhances predictability in outcomes significantly.

In addition to enhancing accuracy and personalized treatment planning, advanced diagnostics contribute to minimizing invasive procedures. With detailed imaging guiding surgical interventions like bone grafting or implant placements planned with high precision via guided surgery templates derived from CBCT data—these innovations reduce operative time and improve patient comfort while ensuring optimal aesthetic and functional results in full mouth rehabilitation scenarios.

Furthermore, advancements in diagnostic tools extend beyond structural analysis; they encompass biological assessments too. Innovations like saliva testing or advanced

periodontal probes provide insights into systemic health influences on oral conditions—a crucial consideration in holistic treatment planning for full mouth rehabilitation where systemic diseases might impact healing rates or material choices for prostheses.

In conclusion, the integration of advanced imaging and diagnostic tools into planning integrated treatments for full mouth rehabilitation epitomizes a leap forward in dental care delivery. These technologies empower practitioners to craft tailored solutions with unprecedented accuracy and efficiency while enhancing patient comfort and satisfaction throughout their journey toward restored oral health and confidence. As we continue to embrace these innovations, we advance not just individual treatments but set new benchmarks for comprehensive care in prosthodontics—ensuring that each smile rebuilt is as unique as the individual it serves.

When we delve into the intricate world of full mouth rehabilitation, especially through the lens of integrating prosthodontics with orthodontic treatment planning, we're navigating a fascinating intersection where art meets science, and the smile becomes a canvas for transformation. This holistic approach is not merely about aligning teeth or replacing missing ones; it's about restoring function, enhancing aesthetics, and improving overall quality of life for patients who have endured significant dental challenges.

At the heart of this balancing act lies the fundamental goal: to harmonize orthodontic objectives with prosthodontic necessities. Orthodontics focuses on correcting tooth positioning and bite issues, aiming for that perfect alignment that not only improves aesthetics but also optimizes oral function. On the other hand, prosthodontics deals with the restoration and replacement of teeth using various appliances like crowns, bridges, dentures, and implants—essential for addressing structural deficiencies in the mouth. When these two disciplines converge in full mouth rehabilitation, they must do so with a careful consideration of each other's goals to achieve a symbiotic outcome.

The planning phase is paramount here; it's where meticulous assessment and patient-centric decision-making take center stage. Clinicians must first understand the patient's unique situation—evaluating bone structure, existing dental conditions, occlusal (bite) relationships, aesthetic desires, and functional needs. This comprehensive evaluation sets the foundation for crafting a treatment plan that doesn't just address immediate concerns but also contemplates long-term stability and satisfaction.

A critical aspect of this integration involves determining when and how orthodontic treatments can facilitate or complement prosthodontic interventions. For instance, aligning teeth through orthodontics might be essential prior to placing dental implants or fabricating certain types of crowns or bridges to ensure optimal fit and function. Conversely, prosthetic restorations might be necessary to support orthodontic movements by providing stable anchor points or by helping to manage forces during tooth movement.

Moreover, communication between specialists is non-negotiable in this collaborative effort. Orthodontists and prosthodontists must work in tandem, sharing insights on progress and potential adjustments needed along the way. This dialogue ensures that as teeth are moved into better positions through orthodontics, any subsequent prosthetic work can seamlessly integrate without compromising the achieved alignment or function. It's about creating a coherent narrative where every step taken towards one goal supports advancements toward another.

In terms of materials and technology—aided by modern advancements—the possibilities for achieving these integrative goals have expanded exponentially. Digital imaging, CAD/CAM technology for precise fabrication of prostheses alongside 3D printing for custom aligners are just some examples enriching this multidisciplinary approach. These tools allow for more accurate predictions of outcomes and enhanced precision in both diagnosis and treatment execution.

Ultimately, successful integration demands flexibility and adaptability from all parties involved—patients included—in embracing potentially multi-phased treatments tailored specifically to their needs. The journey towards full mouth rehabilitation via this integrated approach isn't linear; it requires patience as each component builds upon another over time towards a beautifully functional smile that stands as both an aesthetic triumph and a testament to meticulous planning and execution across disciplines.

In conclusion, treating patients requiring full mouth rehabilitation through an integrated lens of orthodontics and prosthodontics illuminates how diverse expertise can unite towards common goals—restoring health, confidence, and ultimately transforming

Creating a cohesive treatment plan for full mouth rehabilitation, especially when integrating prosthodontics, is akin to crafting a symphony where each instrument—each aspect of dental care—must play in harmony to achieve a beautiful and functional whole. This comprehensive approach is not just about addressing immediate dental issues but also about laying a foundation that ensures long-term oral health and functionality. Let's delve into the strategies that make this intricate process sing.

Understanding the Patient's Complete Needs: The cornerstone of a successful full mouth rehabilitation lies in a thorough assessment of the patient's current dental condition, medical history, and personal goals. This initial step requires empathy and detailed communication, ensuring that every concern, from aesthetic desires to functional needs like biting and speaking clearly, is understood. A comprehensive evaluation includes clinical examinations, radiographic imaging, and possibly models or digital scans of the teeth and jaws to visualize the full picture.

Setting Clear Objectives: With a clear understanding of the patient's needs comes the establishment of specific, measurable objectives. These might range from alleviating pain and restoring lost function to enhancing aesthetics and preventing future issues. Setting

these goals collaboratively with the patient ensures that the treatment plan aligns with their expectations and lifestyle, making adherence more likely. It's crucial to balance immediate relief with long-term sustainability; for instance, while temporary restorations might offer quick comfort, durable solutions like implants or fixed bridges should be considered for lasting results.

Integrating Prosthodontic Solutions: Prosthodontics plays a pivotal role in full mouth rehabilitation due to its focus on replacing missing teeth and restoring oral function with devices such as dentures, bridges, or implants. The integration of these solutions requires careful planning to ensure they work seamlessly with existing dental structures and complement other treatments like orthodontics or periodontal therapy. For instance, implant placement must consider bone health and volume; sometimes bone grafting may be necessary precursor to ensure long-term stability of prosthetic devices.

Emphasizing Interdisciplinary Collaboration: No single dentist can handle all aspects of full mouth rehabilitation alone. Effective treatment planning demands collaboration among various dental specialists—prosthodontists for complex restorations, periodontists for gum health, orthodontists for alignment issues—and possibly even general practitioners when systemic health factors are involved. Regular interdisciplinary meetings ensure that each specialist contributes their expertise towards a unified goal: optimal patient outcomes.

Customizing Treatment Timelines: Recognizing that every patient's situation is unique means tailoring treatment timelines accordingly. Some may require immediate interventions for severe pain or infection management, while others might benefit from a phased approach starting with less invasive procedures before progressing to more complex restorations like implants or full-mouth reconstructions involving prosthodontics. Flexibility in timing respects both the urgency of certain conditions and the patient's capacity to undergo multiple procedures over time.

Education and Support Throughout: Finally, educating patients about their treatment plan fosters understanding and cooperation throughout the journey towards full mouth rehabilitation. Clear explanations about why certain procedures are recommended—not just what they involve—empower patients to make informed decisions regarding their oral health care. Ongoing support helps manage expectations during recovery phases post-treatment stages ensuring patients feel confident in their path forward toward lasting oral health and well-being.

In essence, integrating prosthodontics into a full mouth rehabilitation treatment plan requires meticulous planning characterized by comprehensive assessment, clear goal-setting

When delving into the realm of full mouth rehabilitation through the lens of prosthodontics, it becomes clear that understanding and considering growth patterns isn't just a nicety; it's a fundamental cornerstone for achieving successful treatment outcomes. The mouth, much like the rest of our body, is a dynamic environment—a living canvas where change is not only inevitable but constant. This notion holds profound implications for those embarking on the journey of full mouth rehabilitation, an ambitious endeavor aimed at restoring oral function, aesthetics, and overall health.

Growth patterns in the context of prosthodontics encompass more than just the physical expansion or alteration of dental structures; they reflect a broader biological narrative that includes bone remodeling, periodontal changes, and even muscular adaptations. These processes are influenced by a myriad of factors—age being a pivotal player. As individuals age, their skeletal and dental structures undergo significant transformations. For instance, jawbone density may diminish, affecting how prosthetic devices integrate and function over time. Understanding these nuances allows clinicians to tailor treatments that not only meet immediate needs but also anticipate future changes, thereby enhancing longevity and effectiveness.

Moreover, recognizing growth patterns can significantly impact treatment planning and material selection in prosthodontic interventions. For example, in cases involving implants—a common component in full mouth rehabilitation—it's crucial to consider how bone integration will evolve post-surgery. Bone healing and integration rates vary among individuals due to genetic predispositions, systemic health conditions (like diabetes), and lifestyle factors (such as smoking). By factoring in these variables alongside typical growth patterns specific to age groups—be it the rapid changes seen in adolescents or the stabilization observed in adults—prosthodontists can design more resilient and adaptive restorative solutions.

Furthermore, this consideration extends beyond mere physical aspects to include psychological components crucial for patient satisfaction and compliance. When patients understand that their treatment plan has taken into account not just their current condition but also potential future changes driven by growth patterns, it fosters a sense of security and confidence in their care plan. This psychological reinforcement can be pivotal in ensuring adherence to post-treatment protocols, such as follow-up appointments or maintenance regimens critical for long-term success.

In essence, integrating an awareness of growth patterns into full mouth rehabilitation within prosthodontics is akin to weaving a tapestry where each thread represents different facets of patient care—biological evolution, individual variability, material science advancement, psychological well-being—and their interplay dictates the strength and beauty of the final piece: a restored smile that stands resilient against time's passage. It emphasizes not just fixing what's broken but predicting and adapting to life's ongoing dance of change within the oral environment. Such holistic consideration ensures that treatments aren't merely effective in isolation but remain relevant as life unfolds around them—a testament to thoughtful design and forward-thinking care in prosthodontic practice dedicated to full mouth rehabilitation.

When we delve into the intricate world of full mouth rehabilitation, particularly through the lens of integrating prosthodontics for growing patients, the topic of material selection for prosthetic solutions becomes paramount. It's not merely about choosing materials that serve a functional purpose; it's about selecting solutions that grow, adapt, and support the patient throughout their developmental journey—a journey marked by change, growth, and unique challenges.

For children and adolescents requiring prosthetic solutions, especially in cases where extensive rehabilitation is needed, the choice of materials cannot be taken lightly. These young patients are not static cases; they are dynamic individuals whose bodies are in a constant state of transformation. As their jaws develop, as their teeth erupt and sometimes fall out to make way for permanent ones, the materials used in their prosthetics must be able to accommodate these changes without compromising comfort, function, or aesthetics.

Traditionally, materials like acrylic resins have been favored for their versatility and ease of manipulation. They allow for adjustments and repairs as needed and are relatively lightweight, which is crucial for growing patients who may already be sensitive to discomfort or weight in their mouths. However, acrylic resins have limitations—they can wear down over time, especially under the rigorous use typical of children and teenagers engaging in active lifestyles. This necessitates regular monitoring and potential replacements or adjustments to ensure continued fit and functionality.

In recent years, advancements have introduced newer materials such as high-strength ceramics and composite resins into the mix. These modern materials offer enhanced durability and aesthetic appeal—crucial considerations when aiming to provide solutions that look natural while enduring the test of time—and growth. Ceramics, with their biocompatibility and strength comparable to natural tooth enamel, present an excellent option for long-term stability despite ongoing development in the jawbone and

surrounding tissues. Composite resins further bridge the gap between functionality and aesthetics by offering customizable color options that match naturally with surrounding teeth while providing a sturdy bite surface resilient enough to withstand daily wear-and-tear.

Moreover, incorporating adaptive technologies like 3D printing has revolutionized how we approach material selection for growing patients. This technology allows for precise customization based on individual anatomical needs at different growth stages. It facilitates creating provisional restorations that can evolve alongside the patient's developing dentition without requiring complete overhauls every few years—a significant boon considering both financial implications and psychological comfort for young patients who might otherwise feel self-conscious about frequent changes to their smiles or biting capabilities.

Selecting appropriate materials isn't just about matching current needs but also anticipating future requirements as these patients transition into adulthood. The goal is harmony—functional harmony that allows them to eat comfortably; aesthetic harmony that boosts confidence; structural harmony that supports ongoing growth without faltering or necessitating drastic interventions down the line.

In conclusion, choosing suitable prosthetic solutions for growing patients undergoing full mouth rehabilitation requires a nuanced understanding of both immediate needs and future possibilities inherent in pediatric dentistry. By thoughtfully considering material properties—durability against childhood vigor, adaptability through growth phases, comfort amidst developmental shifts—and leveraging modern advancements like 3D printing alongside traditional wisdom regarding material use such as acrylics and ceramics—we can craft personalized pathways toward comprehensive dental health that stand resilient through life's earliest yet most transformative chapters.

When delving into the world of pediatric prosthodontics, particularly within the context of full mouth rehabilitation, it's crucial to understand the materials that form the backbone of this specialized field. Pediatric prosthodontics, a niche yet vital area of dentistry, focuses on restoring the oral health and functionality of children's teeth, often through complex methods necessitated by their unique developmental needs. The materials chosen for these restorative efforts—such as composite resins and acrylics—play a pivotal role in ensuring both effectiveness and safety for young patients.

Composite resins have emerged as a cornerstone in pediatric prosthodontics due to their versatility and esthetic appeal. These tooth-colored materials are composed of a plastic resin base filled with glass particles, offering a blend of durability and natural appearance that is particularly important for children. In full mouth rehabilitation scenarios, where multiple teeth may require restoration or replacement, composite resins can be utilized for direct restorations like fillings or indirectly through custom-made crowns or veneers. One significant advantage is their ability to bond directly to tooth structure, which minimizes the need for extensive preparation and helps preserve more of the natural tooth—a critical consideration in growing mouths where future dental development must be respected.

Acrylics, on the other hand, while less commonly used for primary restorations in pediatrics due to their somewhat less durable nature compared to composites, find application in certain contexts within full mouth rehabilitation. Acrylic resins are valued for their ease of manipulation and cost-effectiveness, making them suitable for provisional restorations or as part of removable appliances like dentures or orthodontic appliances. For children who might require temporary solutions while awaiting permanent treatments or during phases of growth when final decisions on permanent restorations are deferred, acrylics offer a flexible and adaptable option. Their transparency can also mimic natural teeth well enough for certain situations where immediate aesthetics are a priority without the long-term commitment needed for definitive restorations.

The choice between composite resins and acrylics—or even combining both materials—in pediatric prosthodontics hinges on several factors: the specific needs of the child's oral health condition, considerations around growth and development impacting future dental work, aesthetic demands considering the child's age and social environment, and practical aspects including cost and durability required for different types of restorative work. Moreover, advancements in material science continue to refine these options; newer composite resins boast enhanced strength and longevity while maintaining their esthetic qualities, whereas acrylic formulations evolve toward improved biocompatibility and performance.

In conclusion, integrating prosthodontics into full mouth rehabilitation for children requires careful selection of materials that cater not only to immediate functional needs but also consider long-term dental health outcomes. Composite resins shine with their aesthetic versatility and conservative approach to treatment, making them ideal for definitive restorations aimed at lasting health. Meanwhile, acrylics provide valuable roles in provisional solutions or situations demanding flexibility. Together, these materials exemplify how modern pediatric dentistry balances innovation with care tailored specifically to our youngest patients' unique requirements.

When diving into the intricate world of full mouth rehabilitation through prosthodontics, the selection of materials becomes a pivotal decision, weaving together a tapestry of considerations that range from the tangible durability of materials to the subtler yet equally crucial aspects of biocompatibility and aesthetics. This choice isn't merely about selecting a material off a shelf; it's about crafting a solution that harmonizes with the patient's lifestyle, health, and personal expectations, ensuring that the restoration not only functions well but also feels and looks natural.

Durability stands at the forefront of this decision-making process. In full mouth rehabilitation, patients are often seeking solutions that will withstand the rigorous daily grind—chewing, speaking, and enduring years of use without failing. Materials like zirconia

and certain grades of porcelain have emerged as favorites due to their exceptional strength and resistance to wear. Zirconia, for instance, boasts impressive mechanical properties; it's not just durable but also offers a high level of fracture resistance, making it ideal for situations where bite forces are significant. The longevity of these materials is paramount; after all, no one wants to revisit the dentist for replacements prematurely. It's about investing in a future where functionality meets resilience.

However, durability isn't the sole factor influencing material choice; **biocompatibility** is equally critical. This term refers to how well a material interacts with living tissues in the body without causing adverse reactions or rejection. For prosthodontic materials used in full mouth rehabilitation, biocompatibility ensures that gums and surrounding tissues thrive rather than react negatively to the implanted materials. Titanium alloys have long been celebrated for their outstanding biocompatibility—they integrate seamlessly with bone tissue through osseointegration—a process where bone grows directly onto the surface of the titanium implant, creating an incredibly stable foundation for prostheses like dentures or bridges. The goal here is harmony within the oral environment; materials should support health rather than hinder it.

Finally, let's not overlook **aesthetics**—the often understated yet profoundly impactful element in full mouth rehabilitation. A smile is one of our most expressive features; thus, restoring it requires more than just functional replacement—it demands visual harmony with existing teeth and an overall natural appearance that boosts confidence. Here's where advancements in ceramics shine brightly. Contemporary porcelain veneers and crowns can mimic the translucency and color variation of natural teeth remarkably well, offering results that are not just functional but beautiful. The ability to tailor shades and contours means each restoration can be customized to fit perfectly within a patient's existing dental landscape—a genuine blend into their smile story.

In integrating these elements—durability for longevity, biocompatibility for health assurance, and aesthetics for psychological well-being—prosthodontists weave together tailored solutions for full mouth rehabilitation that go beyond mere functionality. Each decision on material selection becomes an artful balance aimed at enhancing quality of life through restored oral function and appearance. As we continue advancing in dental technology and understanding human biology better, these choices grow increasingly nuanced but remain rooted in one fundamental principle: providing patients with smiles they can trust and cherish throughout their lives.

Integrating prosthodontics into orthodontic therapy, especially within the ambitious context of full mouth rehabilitation, represents a fascinating intersection of dental specialties aimed at restoring both function and aesthetics to patients' smiles. This approach is not merely about aligning teeth but weaving together a comprehensive treatment plan that addresses the complex interplay between oral structures and overall dental health. Full mouth rehabilitation, by its very nature, demands a multidisciplinary strategy where prosthodontics plays a pivotal role, complementing orthodontic interventions to achieve optimal outcomes.

At the heart of this integration lies the understanding that orthodontics deals with the positioning of teeth and jaws, aiming for improved occlusion and facial aesthetics. However, in cases requiring full mouth rehabilitation, the scope expands significantly. Here's where prosthodontics steps in—a specialty that focuses on the restoration and replacement of damaged or missing teeth through various fixed or removable appliances like crowns, bridges, implants, and dentures. The synergy between these disciplines ensures that while orthodontic treatments straighten and align teeth, prosthodontic solutions fill in gaps left by missing teeth or provide support for weakened structures, thereby enhancing the stability and long-term success of orthodontic corrections.

The process begins with an exhaustive examination to assess not just the alignment issues but also the condition of existing dental structures, jaw relationships, and overall

oral health. This foundational step is crucial as it informs both the orthodontic treatment plan—focusing on tooth movement—and the prosthodontic components needed post-treatment to complete the rehabilitation process. For instance, after successful orthodontic alignment, if significant tooth structure has been lost due to decay or trauma, prosthodontic interventions such as crowns or implants become essential to restore both function and aesthetic appeal.

In clinical practice, this integration might involve coordinating phases of treatment meticulously. Initially, orthodontic forces might be applied to correct malocclusions while provisional restorations are used to maintain aesthetics and protect restored areas during active treatment. As orthodontic goals are achieved—straighter teeth in better positions—the focus shifts towards finalizing prosthodontic components tailored specifically for each patient's needs. This could involve placing permanent crowns over treated roots after end periodontal therapy or integrating implant-supported restorations for those with extensive tooth loss.

Moreover, patient comfort and satisfaction stand as critical metrics in evaluating success within this integrated approach. Effective communication between the treating orthodontist and prosthodontist ensures seamless transitions between phases of care and fosters a collaborative environment aimed at achieving patient-centered outcomes. Educating patients about what to expect throughout their journey from initial consultations through final restorations builds trust and ensures they understand how each phase contributes to their overall dental health improvement.

Furthermore, advancements in materials science and technology continue to enhance our capabilities in this domain. Innovations like digital impressions streamline workflows; CAD/CAM technologies allow for precise fabrication of restorative devices; while improved biocompatible materials ensure longevity and functionality of these restorations within dynamic oral environments. These technological strides further

reinforce how closely intertwined modern orthodontics and prosthodontics have become in delivering comprehensive care solutions like full mouth rehabilitation.

In conclusion, integrating prosthodontics into orthodontic therapy for full mouth rehabilitation exemplifies contemporary dentistry's commitment to holistic patient care—where every smile is meticulously crafted not just for beauty but for sustained health.

When embarking on the comprehensive journey of full mouth rehabilitation, integrating various prosthodontic techniques becomes essential for achieving optimal functional and aesthetic outcomes. Among these techniques, bonded restorations, space maintainers, and temporary anchorage devices (TADs) play pivotal roles in restoring not just the teeth but the entire masticatory system to its former glory. Let's delve into how each of these contributes to the intricate process of full mouth rehabilitation.

Bonded Restorations: The Art of Preservation and Aesthetics

Bonded restorations are a cornerstone in modern dentistry, especially within the realm of full mouth rehabilitation. These restorations involve adhering materials—such as composite resins or ceramics—to existing tooth structures using adhesives. The beauty of bonded restorations lies in their ability to conserve healthy tooth structure while simultaneously addressing issues like decay, fractures, or esthetic concerns. In a full mouth rehabilitation scenario, where multiple teeth might require restoration, bonding allows for a conservative approach that minimizes preparation of the tooth structure compared to traditional crowns or bridges. This not only preserves more natural tooth substance but also offers a highly aesthetic result that blends seamlessly with surrounding teeth. Moreover, advancements in materials science have significantly enhanced the durability and longevity of bonded restorations, making them a reliable choice for long-term rehabilitation needs.

Space Maintainers: Safeguarding Future Smiles

In scenarios where premature loss of primary teeth occurs—perhaps due to decay or trauma—the space maintainers step in as unsung heroes in full mouth rehabilitation. These devices are critical for maintaining the spacing necessary for permanent teeth to erupt correctly. Without proper space maintenance, erupted permanent teeth can drift into spaces meant for other teeth, leading to crowding and misalignment that complicates future orthodontic treatments and overall dental health. Space maintainers can be simple appliances like bands placed on adjacent teeth or more complex devices designed to accommodate growth and development. Their strategic use ensures that when it's time for permanent teeth to come in, they have the room they need to establish a balanced occlusion—a fundamental aspect of both function and aesthetics in full mouth rehabilitation.

Temporary Anchorage Devices (TADs): Revolutionizing Orthodontic Stability

The introduction of Temporary Anchorage Devices (TADs) has revolutionized orthodontic procedures integral to full mouth rehabilitation. TADs are miniature screws or plates temporarily inserted into the bone to provide absolute anchorage for tooth movement that would otherwise be challenging or impossible with traditional orthodontic methods alone. They play a crucial role when precise control over individual tooth movements is required—for instance, correcting complex malocclusions or preparing space for implant placement as part of comprehensive rehabilitative efforts. By utilizing TADs, clinicians gain unprecedented control over forces applied during treatment phases such as extraction-prosthetic cases or when aligning teeth ahead of definitive restorative work like crowns or bridges. This level of precision not only improves treatment outcomes but also shortens overall treatment time by simplifying what would otherwise be multi-step processes into more streamlined interventions.

In weaving together these techniques—bonded restorations for conservation and aesthetics, space maintainers for guiding proper eruption sequences, and TADs for achieving precise orthodontic control—dentists craft personalized pathways through full mouth rehabilitation that honor both form and function. Each element addresses specific challenges encountered along this

The integration of prosthodontic elements within orthodontic treatments represents a pivotal advancement in the realm of dentistry, particularly when it comes to full mouth rehabilitation. This comprehensive approach marries the art of restoring teeth with the science of correcting bites and aligning jaws, offering patients a pathway to not just functional improvement but also enhanced aesthetics and confidence. To appreciate this synthesis, let's delve into some illustrative case studies that highlight its successful application.

Case Study 1: The Comprehensive Smile Makeover

Consider a patient who presented with severe tooth wear, malocclusion, and missing teeth—common challenges requiring both orthodontic and prosthodontic interventions. The treatment plan involved initial orthodontic therapy to align the remaining teeth properly, followed by the placement of dental implants to support new crowns for the missing teeth. This not only corrected bite issues but also restored a complete set of teeth, dramatically improving the patient's ability to chew comfortably and smile confidently. The combination allowed for an aesthetic outcome that was both natural-looking and functional, showcasing how integrating these disciplines can lead to holistic rehabilitation.

Case Study 2: Addressing Complex Jaw Relationships

Another compelling example involves a patient with a complex case of temporomandibular joint (TMJ) disorder coupled with significant overbite and crowding. Here, orthodontic treatment was essential for correcting jaw positioning and alignment, but without addressing the structural deficiencies in the occlusion (bite), long-term stability and comfort could not be guaranteed. Prosthodontic elements such as customized occlusal splints were integrated during various stages of orthodontics to manage biting forces while teeth were being moved. This strategy not only facilitated smoother orthodontic movement but also provided immediate relief from TMJ symptoms, illustrating how prosthodontic considerations can enhance the efficacy of orthodontic treatments in complex cases.

Case Study 3: Full Mouth Reconstruction Post-Trauma

Imagine a scenario where trauma has resulted in extensive tooth loss and skeletal discrepancies. For such cases, full mouth reconstruction becomes imperative. Here, orthodontics plays a crucial role in preparing the dental arch for restorative procedures like crowns, bridges, or implant-supported restorations by ensuring proper tooth positioning and occlusion. In one remarkable recovery story, this combined approach allowed for the restoration of both form and function—imbuing the patient with a fully functional bite alongside an appealing smile that mirrored their pre-trauma condition as closely as possible. It's these success stories that underline how integrating prosthodontics within orthodontics is indispensable for achieving comprehensive rehabilitation outcomes.

These case studies serve as vivid illustrations of how merging prosthodontic expertise with orthodontic care can transform challenging dental scenarios into success stories marked by restored health, function, and aesthetics. They highlight not just technical synergies but also emphasize the importance of personalized treatment planning that respects each patient's unique needs while harnessing advancements in both fields to

deliver superior outcomes in full mouth rehabilitation endeavors.

The integration of interdisciplinary collaboration into the treatment delivery, particularly within the realm of full mouth rehabilitation through prosthodontics, represents a pivotal evolution in dental care. This approach harnesses the collective expertise from various dental specialties and beyond, weaving together a tapestry of knowledge that significantly enhances patient outcomes. The essence of full mouth rehabilitation is not merely about restoring teeth; it's about rejuvenating function, aesthetics, and overall quality of life for patients who often present with complex oral health challenges.

At the heart of this interdisciplinary effort lies the recognition that no single specialist holds all the answers or skills necessary to address every aspect of a patient's needs. Prosthodontists, specialists in restoring and replacing teeth, play a crucial role but must collaborate seamlessly with general dentists, orthodontists, periodontists, endodontists, oral surgeons, and even physicians and therapists outside the traditional dental sphere. Each professional brings unique insights and capabilities that are indispensable when tackling comprehensive cases involving extensive tooth loss, jaw disorders, or systemic health conditions affecting oral health.

This collaborative framework fosters a holistic approach to treatment planning. For instance, an orthodontist might outline the necessary tooth movement to optimize space for prosthetic appliances; a periodontist could contribute insights on gum health critical for supporting these restorations; while an oral surgeon might be essential for complex extractions or bone grafting procedures that prepare the mouth for implants or other prosthetic devices. The synergy generated by these diverse perspectives ensures treatments are not only effective but also tailored to each individual's unique biological and functional requirements.

Moreover, interdisciplinary collaboration extends beyond mere technical coordination; it encourages open communication among team members which is vital for addressing psychological and social dimensions impacting patient care. Full mouth rehabilitation can profoundly affect one's self-esteem and social interactions due to its impact on appearance and speech. By including psychologists or counselors in the treatment team—even if only consultatively—these personal aspects receive attention alongside the physical restoration process.

In embracing this collaborative model, we witness improved efficiency in treatment delivery as well. Referrals between specialists become more streamlined when there's established rapport and mutual understanding among team members. This reduces redundancy in diagnostic processes and ensures that each phase of treatment—from initial assessment through follow-up care—is executed with precision and purposefulness. Patients benefit from reduced waiting times for specialized procedures and a clearer pathway toward their rehabilitation goals.

Furthermore, fostering an environment of continuous learning within these interdisciplinary teams accelerates innovation in materials science, surgical techniques, and digital technologies applicable to prosthodontics. When professionals from different backgrounds come together regularly to discuss cases and share research findings or new methodologies, they collectively push the boundaries of what's possible in patient care. This dynamic not only elevates individual practices but propels advancements across the entire field of dentistry.

In conclusion, interdisciplinary collaboration is not just beneficial—it's essential—for delivering cutting-edge full mouth rehabilitation through advanced prosthodontic techniques. By breaking down silos between specialties and fostering comprehensive teamwork centered around patient needs, we ensure that those seeking extensive dental restoration receive not just treatments but transformative care experiences that restore

functionality, confidence, and ultimately improve their quality of life. As we continue on this path towards integrated healthcare models within dentistry—and medicine at large—we pave the way for even more personalized and effective therapeutic strategies in years to come.

The journey of integrating prosthodontics into full mouth rehabilitation is a testament to the profound necessity of teamwork among various dental specialists. This interdisciplinary approach isn't merely beneficial; it's essential for achieving optimal outcomes in complex cases where the patient's needs span beyond the scope of any single specialty. At the heart of this collaborative effort are orthodontists, prosthodontists, pediatric dentists, and other experts, each contributing their unique expertise to craft a comprehensive treatment plan that addresses not just the immediate dental concerns but also the long-term health and functionality of a patient's oral cavity.

To begin with, consider the intricate nature of full mouth rehabilitation. This process often involves restoring or replacing damaged or missing teeth, correcting bites, and improving overall oral function and aesthetics. Such extensive work requires a deep understanding of how different dental elements interact—something no single specialist can fully encompass on their own. Here's where teamwork shines. An orthodontist, with their specialized knowledge in tooth alignment and bite correction, plays a pivotal role in ensuring that any restorative work done by a prosthodontist fits seamlessly into the patient's existing dental structure. Their collaboration ensures that while prosthetic appliances like crowns, bridges, or implants are being crafted for stability and function, they also harmonize with the patient's bite and orthodontic goals.

Moreover, pediatric dentists bring an invaluable perspective when children or adolescents require such comprehensive care. Their expertise in treating younger patients ensures that early interventions are appropriately managed, setting a solid foundation for future dental health. The integration of their insights into the rehabilitation plan guarantees that growing patients receive treatments tailored to their developmental needs without

compromising future options for permanent dentition or orthodontic treatments.

Prosthodontists themselves are the architects of these complex reconstructions, but their role extends beyond mere fabrication of prosthetic devices. They must work closely with orthodontists to align restorations with ongoing or planned orthodontic treatments, ensuring that as teeth are moved into better positions, restorations adapt accordingly to maintain function and aesthetics. This dynamic partnership is crucial for patients undergoing significant structural changes in their mouths—a change that affects not just individual teeth but how all components of the occlusion interact.

Furthermore, incorporating periodontists into this collaborative framework is equally important. Their specialization in gum health is indispensable when planning surgeries or placing implants—a common component in full mouth rehabilitation—which must be executed with meticulous attention to periodontal tissues to ensure longevity and stability of restorations. Communication between these specialists ensures that aesthetic outcomes don't compromise gum health or vice versa.

In essence, full mouth rehabilitation exemplifies why teamwork among diverse dental professionals isn't just advantageous—it's imperative for success. Each specialist brings a distinct set of skills tailored to specific aspects of patient care within this multifaceted treatment paradigm. By working together—sharing insights, planning strategically across disciplines, and executing treatments collectively—these practitioners transcend individual capabilities to deliver comprehensive care that addresses every facet of a patient's oral health needs truly holistically. In doing so, they elevate treatment outcomes from merely functional to transformational—restoring smiles not just for today but for an entire lifetime filled with confidence and comfort.

Integrating prosthodontics into the comprehensive plan for full mouth rehabilitation (FMR) represents a pivotal moment where the art and science of dentistry converge to restore

not just function, but also confidence and quality of life for patients. The success of such an endeavor hinges significantly on seamless communication among the treatment team, which typically includes dentists, prosthodontists, oral surgeons, periodontists, orthodontists, general practitioners, and sometimes specialists like endodontists or pediatric dentists. Herein lies the crux of effective coordination: a multi-faceted communication strategy that ensures every voice is heard, every expertise is levered, and every patient's journey is tailored to their unique needs.

1. Establishing a Common Ground: The foundation of successful team coordination begins with setting up regular interdisciplinary meetings. These should be structured yet flexible enough to accommodate the dynamic nature of FMR cases. From the outset, it's vital to establish shared goals and expectations for each patient's treatment plan. This common ground acts as a reference point throughout the rehabilitation process, ensuring that all team members are aligned and working towards the same outcomes.

2. Utilizing Advanced Communication Tools: In today's digital age, leveraging technology can significantly enhance communication within the treatment team. Implementing secure online platforms where professionals can share patient records, imaging studies, progress notes, and updates in real-time fosters transparency and accessibility. Such tools facilitate quicker decision-making processes and allow specialists to review cases outside traditional meeting times, thus keeping everyone informed without overcrowding scheduled meetings.

3. Clear Documentation Practices: Detailed documentation isn't just about compliance; it's a cornerstone of effective communication in multidisciplinary settings. Each team member should contribute to a comprehensive treatment plan document that outlines proposed interventions, materials to be used (especially pertinent in prosthodontics), potential challenges anticipated during FMR, and preliminary timelines for each phase of treatment. This shared document serves as a living record that evolves with the patient's

progress and must be readily available to all involved parties.

4. Encouraging Open Dialogue: Beyond formal meetings and documents lies the importance of fostering an environment where open dialogue is encouraged—where questions are welcomed, doubts aired openly, and differing opinions constructively discussed. This culture supports collaborative problem-solving and innovation in addressing complex FMR challenges that may arise during treatment. Regular check-ins not only keep everyone informed but also provide psychological support for patients navigating what can often be an extensive rehabilitation journey.

5. Patient-Centric Communication: Central to all strategies should be an unyielding focus on patient-centered care. Patients should feel engaged in their treatment planning from the start—a concept known as shared decision-making. Clear explanations about their condition, proposed treatments within prosthodontics for FMR, potential risks versus benefits outlined in layman's terms empower patients to actively participate in their care decisions alongside their dental team leaders. This approach not only enhances satisfaction but also improves adherence to prescribed treatments due to heightened understanding and personal investment in outcomes.

6. Scheduling Flexibility: Understanding that full mouth rehabilitation is seldom linear—and often requires adjustments along the way—is crucial for maintaining cohesion within the team. Flexible scheduling practices ensure that immediate discussions regarding unexpected developments or changes in a patient's condition can occur swiftly without delaying other critical appointments or procedures within individual specialists' schedules..

In essence, integrating prosthodontics

Long-term Maintenance and Follow-up Care Post-Rehabilitation: Integrating Prosthodontics for Full Mouth Rehabilitation

The journey of full mouth rehabilitation, particularly when integrating prosthodontic solutions, is not merely a series of procedures but the commencement of a lifelong commitment to oral health and functionality. This endeavor, while transformative in restoring both form and function to one's dentition, necessitates a profound understanding of the importance of long-term maintenance and follow-up care. The intricate dance between patient adherence, professional oversight, and technological advancements crafts the narrative of successful rehabilitation that spans years, if not a lifetime.

To begin with, the cornerstone of post-rehabilitation maintenance is education. Patients must be well-versed in the nuances of their new prosthetic appliances—be it dentures, bridges, or implants—and the meticulous care they require. This includes daily cleaning routines tailored to individual appliance types, recognizing signs of wear or damage early on, and understanding the significance of regular dental check-ups. Education extends beyond personal care; it encompasses lifestyle adjustments that protect investments in oral health—considerations like dietary choices that minimize excessive wear or potential damage to prostheses.

Regular follow-up appointments are another pillar supporting long-term success. These visits serve multiple critical functions: monitoring the fit and condition of prosthetic devices for any necessary adjustments; assessing overall oral health for issues like gum disease or tooth decay that could compromise rehabilitation outcomes; and maintaining a dialogue between patient and practitioner that fosters trust and responsiveness to emerging concerns. The frequency of these visits might vary based on individual needs but underscores a proactive approach rather than a reactive one to oral health challenges.

Moreover, technology plays an ever-increasing role in enhancing both the initial rehabilitation process and its sustaining care. Advances such as digital impressions for more accurate prosthesis fabrication, software-aided design for personalized fit adjustments, and even tele-dentistry platforms for remote monitoring or consultations bridge gaps in accessibility and continuity of care. Such innovations empower both practitioners to deliver precision-tailored solutions and patients to receive timely support without geographical constraints.

It's also essential to highlight the psychological aspect inherent in long-term maintenance-rebuilding confidence through restored function can profoundly impact one's quality of life. Regular engagement with healthcare providers reinforces this positive trajectory by ensuring any issues are swiftly addressed, preventing setbacks that could undermine self-esteem or nutritional intake-both crucial elements for holistic well-being post-rehabilitation.

In conclusion, integrating prosthodontics into full mouth rehabilitation is just the beginning-a dynamic process requiring diligent long-term maintenance and follow-up care to truly thrive. Through education, regular professional oversight, leveraging technology innovatively, and acknowledging the psychological dimensions involved, individuals can navigate this journey with greater assurance. The collaboration between patient commitment and expert guidance paves the way not just for functional restoration but for reclaiming a vibrant quality of life enriched by confident smiles and fulfilling interactions-an outcome worth every effort invested in post-rehabilitative care.

The integration of prosthodontics into full mouth rehabilitation represents a pivotal journey for patients seeking to restore not just the functionality but also the aesthetic and psychological aspects of their oral health. Central to this comprehensive approach is the concept of ongoing monitoring, a practice that underscores the critical importance of maintaining both the stability and health of natural teeth alongside prosthetic appliances. This essay explores why continuous oversight is not merely beneficial but essential in

ensuring long-term success and comfort for individuals undergoing such transformative dental rehabilitations.

To begin with, natural teeth, despite being remarkably resilient, are subject to a myriad of challenges over time, including decay, periodontal disease, and structural damage due to trauma or wear. Prosthetic appliances, whether crowns, bridges, dentures, or implants, serve as vital supports and replacements but are not immune to issues either. Materials can wear down, connections can loosen, and biological responses like gum recession can occur around both natural teeth and implant sites. Ongoing monitoring allows dental professionals to detect these potential problems early on before they escalate into more serious conditions that could compromise the integrity of the rehabilitation plan.

Moreover, the dynamic nature of oral environments means that changes in a patient's oral health status—be it due to systemic health fluctuations or lifestyle factors—can have direct implications for both natural teeth and prosthetic devices. Regular check-ups enable dentists to adjust treatments as necessary, ensuring that any alterations in bite mechanics, occlusion (the way teeth come together), or overall oral hygiene practices are addressed promptly. This proactive stance is crucial because neglecting these details can lead to discomfort, further tooth loss, or even complications like infections that could jeopardize the entire rehabilitation effort.

Additionally, the psychological aspect should not be overlooked. A confident smile significantly impacts one's quality of life; however, this confidence hinges on feeling secure in one's dental restoration. Ongoing monitoring fosters an environment where patients feel supported and informed about their oral health journey. Regular appointments provide opportunities for reinforcing proper care techniques tailored specifically for their individual needs—a blend of natural teeth maintenance alongside care instructions for prosthetic appliances—and this education empowers patients to take an active role in their own oral health management.

In essence, integrating ongoing monitoring into full mouth rehabilitation through prosthodontics isn't just about safeguarding hardware; it's about nurturing an ecosystem where both natural teeth and prosthetic appliances thrive together harmoniously over time. By prioritizing regular evaluations and adjustments based on evolving patient needs and circumstances, dental professionals ensure not only immediate functionality and comfort but also lay a sturdy foundation for lasting oral health outcomes. This holistic approach reaffirms that true success in full mouth rehabilitation extends beyond mere restoration—it encompasses a commitment to continuous care that respects the complex interplay between natural anatomy and modern dental innovations.

Maintaining oral hygiene and managing complications post-treatment are pivotal aspects when integrating prosthodontics into a full mouth rehabilitation plan. This journey, while transformative for many, demands a conscious effort to ensure the longevity and success of the treatment, alongside the overall health of the mouth. Let's delve into why these guidelines are not just recommendations but essential practices for anyone embracing this significant dental restoration process.

The Foundation: Oral Hygiene

At the heart of successful prosthodontic integration and full mouth rehabilitation lies meticulous oral hygiene. The introduction of prosthetic devices—be it dentures, bridges, or implants—changes the landscape of your mouth, necessitating an upgraded approach to care. Here's why maintaining impeccable oral hygiene is non-negotiable:

1. **Preventing Infections:** Prosthetic devices, while marvels of modern dentistry, can create new niches for bacteria if not cleaned properly. Regular brushing, flossing (or using interdental brushes as recommended by your dentist), and rinsing with an

antiseptic mouthwash become crucial to prevent gum disease and infections that could jeopardize your new appliances or natural teeth alike.

2. **Preserving Natural Teeth:** For those fortunate enough to have some natural teeth remaining alongside prosthetic restorations, diligent care helps preserve these teeth from decay and periodontal disease. The contrast in materials and potential fit issues with new restorations means these natural teeth require extra attention.
3. **Longevity of Prosthetics:** Proper cleaning routines not only maintain your oral health but also extend the life of your prosthetic appliances. Regular removal, thorough cleaning, and inspections for wear or damage ensure they function optimally and safely over time.

Managing Complications Post-Treatment

Despite best efforts and meticulous care, complications can arise post-treatment in full mouth rehabilitation. Being proactive in managing these potential issues is key to a smooth recovery and successful outcome:

- 1.

Immediate Post-Treatment Care: After procedures like implant placement or fitting new dentures, patients may experience discomfort, swelling, or minor bleeding. Following dental instructions regarding pain management, dietary adjustments (opting for soft foods initially), and maintaining cleanliness is crucial during this period.

2. **Monitoring for Fit Issues:** New prosthetics may require adjustments to achieve a perfect fit that's both comfortable and functional. Regular follow-up appointments with your prosthodontist allow for necessary tweaks before small issues escalate into larger problems.

3. **Addressing Biological Complications:** Inflammation or infection around implants (peri-implantitis) or under dentures (denture stomatitis) are serious concerns necessitating prompt attention. Early signs like persistent discomfort, redness, or unusual discharges should be reported immediately to prevent progression.

4. **Adapting to Changes:** Adjustment periods vary widely among individuals; some might adapt quickly while others might take longer to get used to their new smile and its functionality. Patience coupled with open communication with your dental team ensures any emerging issues are addressed effectively without compromising comfort or confidence in your rehabilitation journey.


In essence, integrating prosthodontics into a full mouth rehabilitation program is an investment in both aesthetics and function—one that thrives on vigilant maintenance of oral hygiene standards alongside proactive management of potential complications post-treatment. By treating these guidelines not as mere suggestions but as

About health professional


A **health professional, healthcare professional, or healthcare worker** (sometimes abbreviated **HCW**)^[1] is a provider of health care treatment and advice based on formal training and experience. The field includes those who work as a nurse, physician (such as family physician, internist, obstetrician, psychiatrist, radiologist, surgeon etc.), physician assistant, registered dietitian, veterinarian, veterinary technician, optometrist, pharmacist, pharmacy technician, medical assistant, physical therapist, occupational therapist, dentist, midwife, psychologist, audiologist, or healthcare scientist, or who perform services in allied health professions. Experts in public health and community health are also health professionals.

Fields

[edit]



NY College of Health Professions massage therapy class




US Navy doctors deliver a healthy baby

- v
- t
- e

**Health practitioners
and professionals**

- Athletic trainer
- Audiologist
- Chiropractor
- Clinical coder
- Clinical nurse specialist
- Clinical officer
- Community health worker
- Dentist
- Dietitian and nutritionist
- Emergency medical technician
- Feldsher
- Health administrator
- Medical assistant
- Medical laboratory scientist
- Medical transcriptionist
- Nurse anesthetist
- Nurse practitioner
- Nurse midwife
- Nurse
- Occupational Therapist
- Optometrist
- Paramedic
- Pharmacist
- Pharmaconomist
- Pharmacy technician
- Phlebotomist
- Physician
- Physician assistant
- Podiatrist
- Psychologist
- Psychotherapist
- Physical therapist



70% of global health and social care workers are women, 30% of leaders in the global health sector are women

The healthcare workforce comprises a wide variety of professions and occupations who provide some type of healthcare service, including such direct care practitioners as physicians, nurse practitioners, physician assistants, nurses, respiratory therapists, dentists, pharmacists, speech-language pathologist, physical therapists, occupational therapists, physical and behavior therapists, as well as allied health professionals such as phlebotomists, medical laboratory scientists, dieticians, and social workers. They often work in hospitals, healthcare centers and other service delivery points, but also in academic training, research, and administration. Some provide care and treatment services for patients in private homes. Many countries have a large number of community health workers who work outside formal healthcare institutions. Managers of healthcare services, health information technicians, and other assistive personnel and support workers are also considered a vital part of health care teams.^[2]

Healthcare practitioners are commonly grouped into health professions. Within each field of expertise, practitioners are often classified according to skill level and skill specialization. "Health professionals" are highly skilled workers, in professions that usually require extensive knowledge including university-level

study leading to the award of a first degree or higher qualification.^[3] This category includes physicians, physician assistants, registered nurses, veterinarians, veterinary technicians, veterinary assistants, dentists, midwives, radiographers, pharmacists, physiotherapists, optometrists, operating department practitioners and others. Allied health professionals, also referred to as "health associate professionals" in the International Standard Classification of Occupations, support implementation of health care, treatment and referral plans usually established by medical, nursing, respiratory care, and other health professionals, and usually require formal qualifications to practice their profession. In addition, unlicensed assistive personnel assist with providing health care services as permitted.^[citation needed]

Another way to categorize healthcare practitioners is according to the sub-field in which they practice, such as mental health care, pregnancy and childbirth care, surgical care, rehabilitation care, or public health.^[citation needed]

Mental health

[edit]

Main article: Mental health professional

A mental health professional is a health worker who offers services to improve the mental health of individuals or treat mental illness. These include psychiatrists, psychiatry physician assistants, clinical, counseling, and school psychologists, occupational therapists, clinical social workers, psychiatric-mental health nurse practitioners, marriage and family therapists, mental health counselors, as well as other health professionals and allied health professions. These health care providers often deal with the same illnesses, disorders, conditions, and issues; however, their scope of practice often differs. The most significant difference across categories of mental health practitioners is education and training.^[4] There are many damaging effects to the health care workers. Many have had diverse negative psychological symptoms ranging from emotional trauma to very severe

anxiety. Health care workers have not been treated right and because of that their mental, physical, and emotional health has been affected by it. The SAGE author's said that there were 94% of nurses that had experienced at least one PTSD after the traumatic experience. Others have experienced nightmares, flashbacks, and short and long term emotional reactions.^[5] The abuse is causing detrimental effects on these health care workers. Violence is causing health care workers to have a negative attitude toward work tasks and patients, and because of that they are "feeling pressured to accept the order, dispense a product, or administer a medication".^[6] Sometimes it can range from verbal to sexual to physical harassment, whether the abuser is a patient, patient's families, physician, supervisors, or nurses.^[citation needed]

Obstetrics

[edit]

Main articles: Obstetrics, Midwifery, and Birth attendant

A maternal and newborn health practitioner is a health care expert who deals with the care of women and their children before, during and after pregnancy and childbirth. Such health practitioners include obstetricians, physician assistants, midwives, obstetrical nurses and many others. One of the main differences between these professions is in the training and authority to provide surgical services and other life-saving interventions.^[7] In some developing countries, traditional birth attendants, or traditional midwives, are the primary source of pregnancy and childbirth care for many women and families, although they are not certified or licensed. According to research, rates for unhappiness among obstetrician-gynecologists (Ob-Gyns) range somewhere between 40 and 75 percent.^[8]

Geriatrics

[edit]

Main articles: Geriatrics and Geriatric care management

A geriatric care practitioner plans and coordinates the care of the elderly and/or disabled to promote their health, improve their quality of life, and maintain their independence for as long as possible.^[9] They include geriatricians, occupational therapists, physician assistants, adult-gerontology nurse practitioners, clinical nurse specialists, geriatric clinical pharmacists, geriatric nurses, geriatric care managers, geriatric aides, nursing aides, caregivers and others who focus on the health and psychological care needs of older adults.^[*citation needed*]

Surgery

[edit]

A surgical practitioner is a healthcare professional and expert who specializes in the planning and delivery of a patient's perioperative care, including during the anaesthetic, surgical and recovery stages. They may include general and specialist surgeons, physician assistants, assistant surgeons, surgical assistants, veterinary surgeons, veterinary technicians, anesthesiologists, anesthesiologist assistants, nurse anesthetists, surgical nurses, clinical officers, operating department practitioners, anaesthetic technicians, perioperative nurses, surgical technologists, and others.^[*citation needed*]

Rehabilitation

[edit]

A rehabilitation care practitioner is a health worker who provides care and treatment which aims to enhance and restore functional ability and quality of life to those with physical impairments or disabilities. These include physiatrists,

physician assistants, rehabilitation nurses, clinical nurse specialists, nurse practitioners, physiotherapists, chiropractors, orthotists, prosthetists, occupational therapists, recreational therapists, audiologists, speech and language pathologists, respiratory therapists, rehabilitation counsellors, physical rehabilitation therapists, athletic trainers, physiotherapy technicians, orthotic technicians, prosthetic technicians, personal care assistants, and others.^[10]

Optometry

[edit]

Main article: [Optometry](#)

Optometry is a field traditionally associated with the correction of refractive errors using glasses or contact lenses, and treating eye diseases. Optometrists also provide general eye care, including screening exams for glaucoma and diabetic retinopathy and management of routine or eye conditions. Optometrists may also undergo further training in order to specialize in various fields, including glaucoma, medical retina, low vision, or paediatrics. In some countries, such as the United Kingdom, United States, and Canada, Optometrists may also undergo further training in order to be able to perform some surgical procedures.

Diagnostics

[edit]


Main article: [Medical diagnosis](#)

Medical diagnosis providers are health workers responsible for the process of determining which disease or condition explains a person's symptoms and signs. It is most often referred to as diagnosis with the medical context being implicit. This usually involves a team of healthcare providers in various diagnostic units. These include radiographers, radiologists, Sonographers, medical laboratory scientists,

pathologists, and related professionals.^[*citation needed*]

Dentistry

[edit]



Dental assistant on the right supporting a dental operator on the left, during a procedure.

Main article: Dentistry

A dental care practitioner is a health worker and expert who provides care and treatment to promote and restore oral health. These include dentists and dental surgeons, dental assistants, dental auxiliaries, dental hygienists, dental nurses, dental technicians, dental therapists or oral health therapists, and related professionals.

Podiatry

[edit]

Care and treatment for the foot, ankle, and lower leg may be delivered by podiatrists, chiropodists, pedorthists, foot health practitioners, podiatric medical assistants, podiatric nurse and others.

Public health

[edit]

A public health practitioner focuses on improving health among individuals, families and communities through the prevention and treatment of diseases and injuries, surveillance of cases, and promotion of healthy behaviors. This category includes community and preventive medicine specialists, physician assistants, public health nurses, pharmacist, clinical nurse specialists, dietitians, environmental health officers (public health inspectors), paramedics, epidemiologists, public health dentists, and others.^[*citation needed*]

Alternative medicine


[edit]

In many societies, practitioners of alternative medicine have contact with a significant number of people, either as integrated within or remaining outside the formal health care system. These include practitioners in acupuncture, Ayurveda, herbalism, homeopathy, naturopathy, Reiki, Shamballa Reiki energy healing Archived 2021-01-25 at the Wayback Machine, Siddha medicine, traditional Chinese medicine, traditional Korean medicine, Unani, and Yoga. In some countries such as Canada, chiropractors and osteopaths (not to be confused with doctors of osteopathic medicine in the United States) are considered alternative medicine practitioners.

Occupational hazards

[edit]

See also: Occupational hazards in dentistry and Nursing § Occupational hazards



A healthcare professional wears an air sampling device to investigate exposure to airborne influenza

A video describing the Occupational Health and Safety Network, a tool for monitoring occupational hazards to health care workers

The healthcare workforce faces unique health and safety challenges and is recognized by the National Institute for Occupational Safety and Health (NIOSH) as a priority industry sector in the National Occupational Research Agenda (NORA) to identify and provide intervention strategies regarding occupational health and safety issues.^[1]

Biological hazards

[edit]

Exposure to respiratory infectious diseases like tuberculosis (caused by *Mycobacterium tuberculosis*) and influenza can be reduced with the use of respirators; this exposure is a significant occupational hazard for health care professionals.^[2] Healthcare workers are also at risk for diseases that are contracted through extended contact with a patient, including scabies.^[3] Health professionals are also at risk for contracting blood-borne diseases like hepatitis B, hepatitis C, and HIV/AIDS through needlestick injuries or contact with bodily fluids.^[4]^[5] This risk can be mitigated with vaccination when there is a vaccine available, like with hepatitis B.^[5] In epidemic situations, such as the 2014–2016 West African Ebola virus epidemic or the 2003 SARS outbreak, healthcare workers

are at even greater risk, and were disproportionately affected in both the Ebola and SARS outbreaks.^[16]

In general, appropriate personal protective equipment (PPE) is the first-line mode of protection for healthcare workers from infectious diseases. For it to be effective against highly contagious diseases, personal protective equipment must be watertight and prevent the skin and mucous membranes from contacting infectious material. Different levels of personal protective equipment created to unique standards are used in situations where the risk of infection is different. Practices such as triple gloving and multiple respirators do not provide a higher level of protection and present a burden to the worker, who is additionally at increased risk of exposure when removing the PPE. Compliance with appropriate personal protective equipment rules may be difficult in certain situations, such as tropical environments or low-resource settings. A 2020 Cochrane systematic review found low-quality evidence that using more breathable fabric in PPE, double gloving, and active training reduce the risk of contamination but that more randomized controlled trials are needed for how best to train healthcare workers in proper PPE use.^[16]

Tuberculosis screening, testing, and education

[edit]

Based on recommendations from The United States Center for Disease Control and Prevention (CDC) for TB screening and testing the following best practices should be followed when hiring and employing Health Care Personnel.^[17]

When hiring Health Care Personnel, the applicant should complete the following:^[18]
] a TB risk assessment,^[19] a TB symptom evaluation for at least those listed on the Signs & Symptoms page,^[20] a TB test in accordance with the guidelines for Testing for TB Infection,^[21] and additional evaluation for TB disease as needed

(e.g. chest x-ray for HCP with a positive TB test)[¹⁸] The CDC recommends either a blood test, also known as an interferon-gamma release assay (IGRA), or a skin test, also known as a Mantoux tuberculin skin test (TST).[²¹] A TB blood test for baseline testing does not require two-step testing. If the skin test method is used to test HCP upon hire, then two-step testing should be used. A one-step test is not recommended.[¹⁸]

The CDC has outlined further specifics on recommended testing for several scenarios.[²²] In summary:

1. Previous documented positive skin test (TST) then a further TST is not recommended
2. Previous documented negative TST within 12 months before employment OR at least two documented negative TSTs ever then a single TST is recommended
3. All other scenarios, with the exception of programs using blood tests, the recommended testing is a two-step TST

According to these recommended testing guidelines any two negative TST results within 12 months of each other constitute a two-step TST.

For annual screening, testing, and education, the only recurring requirement for all HCP is to receive TB education annually.[¹⁸] While the CDC offers education materials, there is not a well defined requirement as to what constitutes a satisfactory annual education. Annual TB testing is no longer recommended unless there is a known exposure or ongoing transmission at a healthcare facility. Should an HCP be considered at increased occupational risk for TB annual screening may be considered. For HCP with a documented history of a positive TB test result do not need to be re-tested but should instead complete a TB symptom evaluation. It is assumed that any HCP who has undergone a chest x-ray test has had a previous positive test result. When considering mental health you may see your

doctor to be evaluated at your digression. It is recommended to see someone at least once a year in order to make sure that there has not been any sudden changes.[²³]

Psychosocial hazards

[edit]

Occupational stress and occupational burnout are highly prevalent among health professionals.[²⁴] Some studies suggest that workplace stress is pervasive in the health care industry because of inadequate staffing levels, long work hours, exposure to infectious diseases and hazardous substances leading to illness or death, and in some countries threat of malpractice litigation. Other stressors include the emotional labor of caring for ill people and high patient loads. The consequences of this stress can include substance abuse, suicide, major depressive disorder, and anxiety, all of which occur at higher rates in health professionals than the general working population. Elevated levels of stress are also linked to high rates of burnout, absenteeism and diagnostic errors, and reduced rates of patient satisfaction.[²⁵] In Canada, a national report (*Canada's Health Care Providers*) also indicated higher rates of absenteeism due to illness or disability among health care workers compared to the rest of the working population, although those working in health care reported similar levels of good health and fewer reports of being injured at work.[²⁶]

There is some evidence that cognitive-behavioral therapy, relaxation training and therapy (including meditation and massage), and modifying schedules can reduce stress and burnout among multiple sectors of health care providers. Research is ongoing in this area, especially with regards to physicians, whose occupational stress and burnout is less researched compared to other health professions.[²⁷]

Healthcare workers are at higher risk of on-the-job injury due to violence. Drunk, confused, and hostile patients and visitors are a continual threat to providers attempting to treat patients. Frequently, assault and violence in a healthcare setting goes unreported and is wrongly assumed to be part of the job.^[28] Violent incidents typically occur during one-on-one care; being alone with patients increases healthcare workers' risk of assault.^[29] In the United States, healthcare workers experience 2/3 of nonfatal workplace violence incidents.^[28] Psychiatric units represent the highest proportion of violent incidents, at 40%; they are followed by geriatric units (20%) and the emergency department (10%). Workplace violence can also cause psychological trauma.^[29]

Health care professionals are also likely to experience sleep deprivation due to their jobs. Many health care professionals are on a shift work schedule, and therefore experience misalignment of their work schedule and their circadian rhythm. In 2007, 32% of healthcare workers were found to get fewer than 6 hours of sleep a night. Sleep deprivation also predisposes healthcare professionals to make mistakes that may potentially endanger a patient.^[30]

COVID pandemic

[edit]

Especially in times like the present (2020), the hazards of health professional stem into the mental health. Research from the last few months highlights that COVID-19 has contributed greatly to the degradation of mental health in healthcare providers. This includes, but is not limited to, anxiety, depression/burnout, and insomnia.^[citation needed]

A study done by Di Mattei et al. (2020) revealed that 12.63% of COVID nurses and 16.28% of other COVID healthcare workers reported extremely severe anxiety symptoms at the peak of the pandemic.^[31] In addition, another study was

conducted on 1,448 full time employees in Japan. The participants were surveyed at baseline in March 2020 and then again in May 2020. The result of the study showed that psychological distress and anxiety had increased more among healthcare workers during the COVID-19 outbreak.^[32]

Similarly, studies have also shown that following the pandemic, at least one in five healthcare professionals report symptoms of anxiety.^[33] Specifically, the aspect of "anxiety was assessed in 12 studies, with a pooled prevalence of 23.2%" following COVID.^[33] When considering all 1,448 participants that percentage makes up about 335 people.

Abuse by patients

[edit]

- The patients are selecting victims who are more vulnerable. For example, Cho said that these would be the nurses that are lacking experience or trying to get used to their new roles at work.^[34]
- Others authors that agree with this are Vento, Cainelli, & Vallone and they said that, the reason patients have caused danger to health care workers is because of insufficient communication between them, long waiting lines, and overcrowding in waiting areas.^[35] When patients are intrusive and/or violent toward the faculty, this makes the staff question what they should do about taking care of a patient.
- There have been many incidents from patients that have really caused some health care workers to be traumatized and have so much self doubt. Goldblatt and other authors said that there was a lady who was giving birth, her husband said, "Who is in charge around here"? "Who are these sluts you employ here".^[5] This was very avoidable to have been said to the people who are taking care of your wife and child.

Physical and chemical hazards

[edit]

Slips, trips, and falls are the second-most common cause of worker's compensation claims in the US and cause 21% of work absences due to injury. These injuries most commonly result in strains and sprains; women, those older than 45, and those who have been working less than a year in a healthcare setting are at the highest risk.^[36]

An epidemiological study published in 2018 examined the hearing status of noise-exposed health care and social assistance (HSA) workers sector to estimate and compare the prevalence of hearing loss by subsector within the sector. Most of the HSA subsector prevalence estimates ranged from 14% to 18%, but the Medical and Diagnostic Laboratories subsector had 31% prevalence and the Offices of All Other Miscellaneous Health Practitioners had a 24% prevalence. The Child Day Care Services subsector also had a 52% higher risk than the reference industry.^[37]

Exposure to hazardous drugs, including those for chemotherapy, is another potential occupational risk. These drugs can cause cancer and other health conditions.^[38]

Gender factors

[edit]

Female health care workers may face specific types of workplace-related health conditions and stress. According to the World Health Organization, women predominate in the formal health workforce in many countries and are prone to musculoskeletal injury (caused by physically demanding job tasks such as lifting

and moving patients) and burnout. Female health workers are exposed to hazardous drugs and chemicals in the workplace which may cause adverse reproductive outcomes such as spontaneous abortion and congenital malformations. In some contexts, female health workers are also subject to gender-based violence from coworkers and patients.^[39]^[40]

Workforce shortages

[edit]

See also: Health workforce, Doctor shortage, and Nursing shortage

Many jurisdictions report shortfalls in the number of trained health human resources to meet population health needs and/or service delivery targets, especially in medically underserved areas. For example, in the United States, the 2010 federal budget invested \$330 million to increase the number of physicians, physician assistants, nurse practitioners, nurses, and dentists practicing in areas of the country experiencing shortages of trained health professionals. The Budget expands loan repayment programs for physicians, nurses, and dentists who agree to practice in medically underserved areas. This funding will enhance the capacity of nursing schools to increase the number of nurses. It will also allow states to increase access to oral health care through dental workforce development grants. The Budget's new resources will sustain the expansion of the health care workforce funded in the Recovery Act.^[41] There were 15.7 million health care professionals in the US as of 2011.^[36]

In Canada, the 2011 federal budget announced a Canada Student Loan forgiveness program to encourage and support new family physicians, physician assistants, nurse practitioners and nurses to practice in underserved rural or remote communities of the country, including communities that provide health services

to First Nations and Inuit populations.^[42]

In Uganda, the Ministry of Health reports that as many as 50% of staffing positions for health workers in rural and underserved areas remain vacant. As of early 2011, the Ministry was conducting research and costing analyses to determine the most appropriate attraction and retention packages for medical officers, nursing officers, pharmacists, and laboratory technicians in the country's rural areas.^[43]

At the international level, the World Health Organization estimates a shortage of almost 4.3 million doctors, midwives, nurses, and support workers worldwide to meet target coverage levels of essential primary health care interventions.^[44] The shortage is reported most severe in 57 of the poorest countries, especially in sub-Saharan Africa.

Nurses are the most common type of medical field worker to face shortages around the world. There are numerous reasons that the nursing shortage occurs globally. Some include: inadequate pay, a large percentage of working nurses are over the age of 45 and are nearing retirement age, burnout, and lack of recognition.^[45]

Incentive programs have been put in place to aid in the deficit of pharmacists and pharmacy students. The reason for the shortage of pharmacy students is unknown but one can infer that it is due to the level of difficulty in the program.^[46]

Results of nursing staff shortages can cause unsafe staffing levels that lead to poor patient care. Five or more incidents that occur per day in a hospital setting as a result of nurses who do not receive adequate rest or meal breaks is a common issue.^[47]

Regulation and registration

[edit]

Main article: Health professional requisites

Practicing without a license that is valid and current is typically illegal. In most jurisdictions, the provision of health care services is regulated by the government. Individuals found to be providing medical, nursing or other professional services without the appropriate certification or license may face sanctions and criminal charges leading to a prison term. The number of professions subject to regulation, requisites for individuals to receive professional licensure, and nature of sanctions that can be imposed for failure to comply vary across jurisdictions.

In the United States, under Michigan state laws, an individual is guilty of a felony if identified as practicing in the health profession without a valid personal license or registration. Health professionals can also be imprisoned if found guilty of practicing beyond the limits allowed by their licenses and registration. The state laws define the scope of practice for medicine, nursing, and a number of allied health professions.^[48]^[*unreliable source?*] In Florida, practicing medicine without the appropriate license is a crime classified as a third degree felony,^[49] which may give imprisonment up to five years. Practicing a health care profession without a license which results in serious bodily injury classifies as a second degree felony,^[49] providing up to 15 years' imprisonment.

In the United Kingdom, healthcare professionals are regulated by the state; the UK Health and Care Professions Council (HCPC) protects the 'title' of each profession it regulates. For example, it is illegal for someone to call himself an Occupational Therapist or Radiographer if they are not on the register held by the HCPC.

See also

[edit]

- List of healthcare occupations
- Community health center
- Chronic care management

- Electronic superbill
- Geriatric care management
- Health human resources
- Uniform Emergency Volunteer Health Practitioners Act

References

[edit]

1. ^ "HCWs With Long COVID Report Doubt, Disbelief From Colleagues". *Medscape*. 29 November 2021.
2. ^ World Health Organization, 2006. *World Health Report 2006: working together for health*. Geneva: WHO.
3. ^ "Classifying health workers" (PDF). World Health Organization. Geneva. 2010. Archived (PDF) from the original on 2015-08-16. Retrieved 2016-02-13.
4. ^ "Difference Between Psychologists and Psychiatrists". *Psychology.about.com*. 2007. Archived from the original on April 3, 2007. Retrieved March 4, 2007.
5. ^ **a b** Goldblatt, Hadass; Freund, Anat; Drach-Zahavy, Anat; Enosh, Guy; Peterfreund, Ilana; Edlis, Neomi (2020-05-01). "Providing Health Care in the Shadow of Violence: Does Emotion Regulation Vary Among Hospital Workers From Different Professions?". *Journal of Interpersonal Violence*. **35** (9–10): 1908–1933. doi:10.1177/0886260517700620. ISSN 0886-2605. PMID 29294693. S2CID 19304885.
6. ^ Johnson, Cheryl L.; DeMass Martin, Suzanne L.; Markle-Elder, Sara (April 2007). "Stopping Verbal Abuse in the Workplace". *American Journal of Nursing*. **107** (4): 32–34. doi:10.1097/01.naj.0000271177.59574.c5. ISSN 0002-936X. PMID 17413727.
7. ^ Gupta N et al. "Human resources for maternal, newborn and child health: from measurement and planning to performance for improved health outcomes. Archived 2015-09-24 at the Wayback Machine *Human Resources for Health*, 2011, 9(16). Retrieved 20 October 2011.
8. ^ "Ob-Gyn Burnout: Why So Many Doctors Are Questioning Their Calling". *healthcareers.com*. Retrieved 2023-05-22.
9. ^ Araujo de Carvalho, Islene; Epping-Jordan, JoAnne; Pot, Anne Margriet; Kelley, Edward; Toro, Nuria; Thiyagarajan, Jotheeswaran A; Beard, John R (2017-11-01). "Organizing integrated health-care services to meet older people's

- needs". *Bulletin of the World Health Organization*. **95** (11): 756–763. doi:10.2471/BLT.16.187617 (inactive 5 December 2024). ISSN 0042-9686. PMC 5677611. PMID 29147056.cite journal: CS1 maint: DOI inactive as of December 2024 (link)
10. ^ Gupta N et al. "Health-related rehabilitation services: assessing the global supply of and need for human resources." Archived 2012-07-20 at the Wayback Machine *BMC Health Services Research*, 2011, 11:276. Published 17 October 2011. Retrieved 20 October 2011.
 11. ^ "National Occupational Research Agenda for Healthcare and Social Assistance | NIOSH | CDC". www.cdc.gov. 2019-02-15. Retrieved 2019-03-14.
 12. ^ Bergman, Michael; Zhuang, Ziqing; Shaffer, Ronald E. (25 July 2013). "Advanced Headforms for Evaluating Respirator Fit". National Institute for Occupational Safety and Health. Archived from the original on 16 January 2015. Retrieved 18 January 2015.
 13. ^ FitzGerald, Deirdre; Grainger, Rachel J.; Reid, Alex (2014). "Interventions for preventing the spread of infestation in close contacts of people with scabies". *The Cochrane Database of Systematic Reviews*. **2014** (2): CD009943. doi:10.1002/14651858.CD009943.pub2. ISSN 1469-493X. PMC 10819104. PMID 24566946.
 14. ^ Cunningham, Thomas; Burnett, Garrett (17 May 2013). "Does your workplace culture help protect you from hepatitis?". National Institute for Occupational Safety and Health. Archived from the original on 18 January 2015. Retrieved 18 January 2015.
 15. ^ a b Reddy, Viraj K; Lavoie, Marie-Claude; Verbeek, Jos H; Pahwa, Manisha (14 November 2017). "Devices for preventing percutaneous exposure injuries caused by needles in healthcare personnel". *Cochrane Database of Systematic Reviews*. **2017** (11): CD009740. doi:10.1002/14651858.CD009740.pub3. PMC 6491125. PMID 29190036.
 16. ^ a b Verbeek, Jos H.; Rajamaki, Blair; Ijaz, Sharee; Sauni, Riitta; Toomey, Elaine; Blackwood, Bronagh; Tikka, Christina; Ruotsalainen, Jani H.; Kilinc Balci, F. Selcen (May 15, 2020). "Personal protective equipment for preventing highly infectious diseases due to exposure to contaminated body fluids in healthcare staff". *The Cochrane Database of Systematic Reviews*. **2020** (5): CD011621. doi:10.1002/14651858.CD011621.pub5. hdl:1983/b7069408-3bf6-457a-9c6f-ecc38c00ee48. ISSN 1469-493X. PMC 8785899. PMID 32412096. S2CID 218649177.

17. ^ Sosa, Lynn E. (April 2, 2019). "Tuberculosis Screening, Testing, and Treatment of U.S. Health Care Personnel: Recommendations from the National Tuberculosis Controllers Association and CDC, 2019". *MMWR. Morbidity and Mortality Weekly Report*. **68** (19): 439–443. doi:10.15585/mmwr.mm6819a3. PMC 6522077. PMID 31099768.
18. ^ **a b c d** "Testing Health Care Workers | Testing & Diagnosis | TB | CDC". www.cdc.gov. March 8, 2021.
19. ^ "Health Care Personnel (HCP) Baseline Individual TB Risk Assessment" (PDF) . cdc.gov. Retrieved 18 September 2022.
20. ^ "Signs & Symptoms | Basic TB Facts | TB | CDC". www.cdc.gov. February 4, 2021.
21. ^ **a b** "Testing for TB Infection | Testing & Diagnosis | TB | CDC". www.cdc.gov. March 8, 2021.
22. ^ "Guidelines for Preventing the Transmission of Mycobacterium tuberculosis in Health-Care Settings, 2005". www.cdc.gov.
23. ^ Spoorthy, Mamidipalli Sai; Pratapa, Sree Karthik; Mahant, Supriya (June 2020). "Mental health problems faced by healthcare workers due to the COVID-19 pandemic—A review". *Asian Journal of Psychiatry*. **51**: 102119. doi:10.1016/j.ajp.2020.102119. PMC 7175897. PMID 32339895.
24. ^ Ruotsalainen, Jani H.; Verbeek, Jos H.; Mariné, Albert; Serra, Consol (2015-04-07). "Preventing occupational stress in healthcare workers". *The Cochrane Database of Systematic Reviews*. **2015** (4): CD002892. doi:10.1002/14651858.CD002892.pub5. ISSN 1469-493X. PMC 6718215. PMID 25847433.
25. ^ "Exposure to Stress: Occupational Hazards in Hospitals". NIOSH Publication No. 2008–136 (July 2008). 2 December 2008. doi:10.26616/NIOSH/PUB2008136 . Archived from the original on 12 December 2008.
26. ^ *Canada's Health Care Providers, 2007 (Report)*. Ottawa: Canadian Institute for Health Information. 2007. Archived from the original on 2011-09-27.
27. ^ Ruotsalainen, JH; Verbeek, JH; Mariné, A; Serra, C (7 April 2015). "Preventing occupational stress in healthcare workers". *The Cochrane Database of Systematic Reviews*. **2015** (4): CD002892. doi:10.1002/14651858.CD002892.pub5. PMC 6718215. PMID 25847433.
28. ^ **a b** Hartley, Dan; Ridenour, Marilyn (12 August 2013). "Free On-line Violence Prevention Training for Nurses". National Institute for Occupational Safety and Health. Archived from the original on 16 January 2015. Retrieved 15 January 2015.

29. ^ a b Hartley, Dan; Ridenour, Marilyn (September 13, 2011). "Workplace Violence in the Healthcare Setting". NIOSH: Workplace Safety and Health. Medscape and NIOSH. Archived from the original on February 8, 2014.
30. ^ Caruso, Claire C. (August 2, 2012). "Running on Empty: Fatigue and Healthcare Professionals". NIOSH: Workplace Safety and Health. Medscape and NIOSH. Archived from the original on May 11, 2013.
31. ^ Di Mattei, Valentina; Perego, Gaia; Milano, Francesca; Mazzetti, Martina; Taranto, Paola; Di Pierro, Rossella; De Panfilis, Chiara; Madeddu, Fabio; Preti, Emanuele (2021-05-15). "The "Healthcare Workers' Wellbeing (Benessere Operatori)" Project: A Picture of the Mental Health Conditions of Italian Healthcare Workers during the First Wave of the COVID-19 Pandemic". *International Journal of Environmental Research and Public Health*. **18** (10): 5267. doi:10.3390/ijerph18105267. ISSN 1660-4601. PMC 8156728. PMID 34063421.
32. ^ Sasaki, Natsu; Kuroda, Reiko; Tsuno, Kanami; Kawakami, Norito (2020-11-01). "The deterioration of mental health among healthcare workers during the COVID-19 outbreak: A population-based cohort study of workers in Japan". *Scandinavian Journal of Work, Environment & Health*. **46** (6): 639–644. doi:10.5271/sjweh.3922. ISSN 0355-3140. PMC 7737801. PMID 32905601.
33. ^ a b Pappa, Sofia; Ntella, Vasiliki; Giannakas, Timoleon; Giannakoulis, Vassilis G.; Papoutsis, Eleni; Katsaounou, Paraskevi (August 2020). "Prevalence of depression, anxiety, and insomnia among healthcare workers during the COVID-19 pandemic: A systematic review and meta-analysis". *Brain, Behavior, and Immunity*. **88**: 901–907. doi:10.1016/j.bbi.2020.05.026. PMC 7206431. PMID 32437915.
34. ^ Cho, Hyeonmi; Pavek, Katie; Steege, Linsey (2020-07-22). "Workplace verbal abuse, nurse-reported quality of care and patient safety outcomes among early-career hospital nurses". *Journal of Nursing Management*. **28** (6): 1250–1258. doi:10.1111/jonm.13071. ISSN 0966-0429. PMID 32564407. S2CID 219972442.
35. ^ Vento, Sandro; Cainelli, Francesca; Vallone, Alfredo (2020-09-18). "Violence Against Healthcare Workers: A Worldwide Phenomenon With Serious Consequences". *Frontiers in Public Health*. **8**: 570459. doi:10.3389/fpubh.2020.570459. ISSN 2296-2565. PMC 7531183. PMID 33072706.
36. ^ a b Collins, James W.; Bell, Jennifer L. (June 11, 2012). "Slipping, Tripping, and Falling at Work". NIOSH: Workplace Safety and Health. Medscape and NIOSH. Archived from the original on December 3, 2012.
37. ^ Masterson, Elizabeth A.; Themann, Christa L.; Calvert, Geoffrey M. (2018-04-15). "Prevalence of Hearing Loss Among Noise-Exposed Workers Within the Health Care and Social Assistance Sector, 2003 to 2012". *Journal of*

Occupational and Environmental Medicine. **60** (4): 350–356.
doi:10.1097/JOM.0000000000001214. ISSN 1076-2752. PMID 29111986.
S2CID 4637417.

38. ^ Connor, Thomas H. (March 7, 2011). "Hazardous Drugs in Healthcare". *NIOSH: Workplace Safety and Health*. Medscape and NIOSH. Archived from the original on March 7, 2012.
39. ^ World Health Organization. *Women and health: today's evidence, tomorrow's agenda*. Archived 2012-12-25 at the Wayback Machine Geneva, 2009. Retrieved on March 9, 2011.
40. ^ Swanson, Naomi; Tisdale-Pardi, Julie; MacDonald, Leslie; Tiesman, Hope M. (13 May 2013). "Women's Health at Work". *National Institute for Occupational Safety and Health*. Archived from the original on 18 January 2015. Retrieved 21 January 2015.
41. ^ "Archived copy" (PDF). *Office of Management and Budget*. Retrieved 2009-03-06 – via *National Archives*.
42. ^ Government of Canada. 2011. *Canada's Economic Action Plan: Forging Loans for New Doctors and Nurses in Under-Served Rural and Remote Areas*. Ottawa, 22 March 2011. Retrieved 23 March 2011.
43. ^ Rockers P et al. *Determining Priority Retention Packages to Attract and Retain Health Workers in Rural and Remote Areas in Uganda*. Archived 2011-05-23 at the Wayback Machine CapacityPlus Project. February 2011.
44. ^ "The World Health Report 2006 - Working together for health". Geneva: WHO: World Health Organization. 2006. Archived from the original on 2011-02-28.
45. ^ Mefoh, Philip Chukwuemeka; Ude, Eze Nsi; Chukwuorji, JohBosco Chika (2019-01-02). "Age and burnout syndrome in nursing professionals: moderating role of emotion-focused coping". *Psychology, Health & Medicine*. **24** (1): 101–107. doi:10.1080/13548506.2018.1502457. ISSN 1354-8506. PMID 30095287. S2CID 51954488.
46. ^ Traynor, Kate (2003-09-15). "Staffing shortages plague nation's pharmacy schools". *American Journal of Health-System Pharmacy*. **60** (18): 1822–1824. doi:10.1093/ajhp/60.18.1822. ISSN 1079-2082. PMID 14521029.
47. ^ Leslie, G. D. (October 2008). "Critical Staffing shortage". *Australian Nursing Journal*. **16** (4): 16–17. doi:10.1016/s1036-7314(05)80033-5. ISSN 1036-7314. PMID 14692155.
48. ^ wiki.bmezzine.com --> Practicing Medicine. In turn citing Michigan laws

49. [^] **a b** CHAPTER 2004-256 Committee Substitute for Senate Bill No. 1118
Archived 2011-07-23 at the Wayback Machine State of Florida, Department
of State.

External links

[edit]

- World Health Organization: Health workers

- v

- t

- e

Health care

- Economics

- Equipment

- Guidelines

- Industry

- Philosophy

- Policy

- Providers

- Public health

- Ranking

- Reform

- System

- Medicine
- Nursing
- Pharmacy
- Professions**
 - Healthcare science
 - Dentistry
 - Allied health professions
 - Health information management
 - Assisted living
 - Clinic
 - Hospital
- Settings**
 - Nursing home
 - Medical school (Academic health science centre, Teaching hospital)
 - Pharmacy school
 - Supervised injection site
 - Acute
 - Chronic
 - End-of-life
 - Hospice
- Care**
 - Overutilization
 - Palliative
 - Primary
 - Self
 - Total
 - Bedside manner
- Skills / training**
 - Cultural competence
 - Diagnosis
 - Education
 - Universal precautions

Technology

- 3D bioprinting
- Artificial intelligence
- Connected health
- Digital health
- Electronic health records
- mHealth
- Nanomedicine
- Telemedicine
- Medical image computing and imaging informatics
- Artificial intelligence in healthcare
- Neuroinformatics in healthcare
- Behavior informatics in healthcare
- Computational biology in healthcare

Health informatics

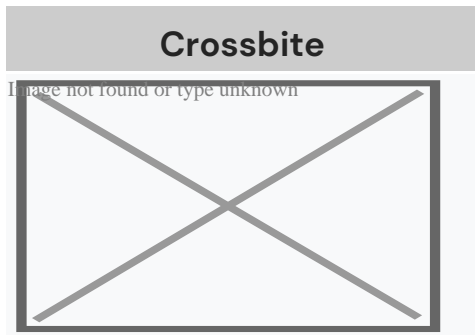
- Translational bioinformatics
- Translational medicine
- health information technology
- Telemedicine
- Public health informatics
- Health information management
- Consumer health informatics
- United States
 - reform debate in the United States
 - History of public health in the United States

By country

- United Kingdom
- Canada
- Australia
- New Zealand
- (Category Health care by country)

-  **Category** image not found or type unknown

About crossbite




Unilateral posterior crossbite

Specialty Orthodontics

In dentistry, **crossbite** is a form of malocclusion where a tooth (or teeth) has a more buccal or lingual position (that is, the tooth is either closer to the cheek or to the tongue) than its corresponding antagonist tooth in the upper or lower dental arch. In other words, crossbite is a lateral misalignment of the dental arches.^{[1][2]}

Anterior crossbite

[edit]



Class 1 with anterior crossbite

An anterior crossbite can be referred as negative overjet, and is typical of class III skeletal relations (prognathism).

Primary/mixed dentitions

[edit]

An anterior crossbite in a child with baby teeth or mixed dentition may happen due to either dental misalignment or skeletal misalignment. Dental causes may be due to displacement of one or two teeth, where skeletal causes involve either mandibular hyperplasia, maxillary hypoplasia or combination of both.

Dental crossbite

[edit]

An anterior crossbite due to dental component involves displacement of either maxillary central or lateral incisors lingual to their original erupting positions. This may happen due to delayed eruption of the primary teeth leading to permanent teeth moving lingual to their primary predecessors. This will lead to anterior crossbite where upon biting, upper teeth are behind the lower front teeth and may involve few or all frontal incisors. In this type of crossbite, the maxillary and mandibular proportions are normal to each other and to the cranial base. Another reason that may lead to a dental crossbite is crowding in the maxillary arch. Permanent teeth will tend to erupt lingual to the primary teeth in presence of crowding. Side-effects caused by dental crossbite can be increased recession on the buccal of lower incisors and higher chance of inflammation in the same area. Another term for an anterior crossbite due to dental interferences is *Pseudo Class III Crossbite or Malocclusion*.

Single tooth crossbite

[edit]

Single tooth crossbites can occur due to uneruption of a primary teeth in a timely manner which causes permanent tooth to erupt in a different eruption pattern which is lingual to the primary tooth.^[3] Single tooth crossbites are often fixed by using a finger-spring based appliances.^[4]^[5] This type of spring can be attached to a removable appliance which is used by patient every day to correct the tooth position.

Skeletal crossbite

[edit]

An anterior crossbite due to skeletal reasons will involve a deficient maxilla and a more hyperplastic or overgrown mandible. People with this type of crossbite will have dental compensation which involves proclined maxillary incisors and retroclined mandibular incisors. A proper diagnosis can be made by having a person bite into their centric relation will show mandibular incisors ahead of the maxillary incisors, which will show the skeletal discrepancy between the two jaws.^[6]

Posterior crossbite

[edit]

Bjork defined posterior crossbite as a malocclusion where the buccal cusps of canine, premolar and molar of upper teeth occlude lingually to the buccal cusps of canine, premolar and molar of lower teeth.^[7] Posterior crossbite is often correlated to a narrow maxilla and upper dental arch. A posterior crossbite can be

unilateral, bilateral, single-tooth or entire segment crossbite. Posterior crossbite has been reported to occur between 7–23% of the population.^{[8][9]} The most common type of posterior crossbite to occur is the unilateral crossbite which occurs in 80% to 97% of the posterior crossbite cases.^{[10][3]} Posterior crossbites also occur most commonly in primary and mixed dentition. This type of crossbite usually presents with a *functional shift of the mandible towards the side of the crossbite*. Posterior crossbite can occur due to either skeletal, dental or functional abnormalities. One of the common reasons for development of posterior crossbite is the size difference between maxilla and mandible, where maxilla is smaller than mandible.^[11] Posterior crossbite can result due to

- Upper Airway Obstruction where people with "adenoid faces" who have trouble breathing through their nose. They have an open bite malocclusion and present with development of posterior crossbite.^[12]
- Prolong digit or suckling habits which can lead to constriction of maxilla posteriorly^[13]
- Prolong pacifier use (beyond age 4)^[13]

Connections with TMD

[edit]

Unilateral posterior crossbite

[edit]

Unilateral crossbite involves one side of the arch. The most common cause of unilateral crossbite is a narrow maxillary dental arch. This can happen due to habits such as digit sucking, prolonged use of pacifier or upper airway obstruction. Due to the discrepancy between the maxillary and mandibular arch, neuromuscular guidance of the mandible causes mandible to shift towards the side of the crossbite.^[14] This is also known as Functional mandibular shift. This

shift can become structural if left untreated for a long time during growth, leading to skeletal asymmetries. Unilateral crossbites can present with following features in a child

- Lower midline deviation^[15] to the crossbite side
- Class 2 Subdivision relationships
- Temporomandibular disorders ^[16]

Treatment

[edit]

A child with posterior crossbite should be treated immediately if the child shifts their mandible on closing, which is often seen in a unilateral crossbite as mentioned above. The best age to treat a child with crossbite is in their mixed dentition when their palatal sutures have not fused to each other. Palatal expansion allows more space in an arch to relieve crowding and correct posterior crossbite. The correction can include any type of palatal expanders that will expand the palate which resolves the narrow constriction of the maxilla.^[9] There are several therapies that can be used to correct a posterior crossbite: braces, 'Z' spring or cantilever spring, quad helix, removable plates, clear aligner therapy, or a Delaire mask. The correct therapy should be decided by the orthodontist depending on the type and severity of the crossbite.

One of the keys in diagnosing the anterior crossbite due to skeletal vs dental causes is diagnosing a CR-CO shift in a patient. An adolescent presenting with anterior crossbite may be positioning their mandible forward into centric occlusion (CO) due to the dental interferences. Thus finding their occlusion in centric relation (CR) is key in diagnosis. For anterior crossbite, if their CO matches their CR then the patient truly has a skeletal component to their crossbite. If the CR shows a less severe class 3 malocclusion or teeth not in anterior crossbite, this may mean that their anterior crossbite results due to dental interferences.^[17]

Goal to treat unilateral crossbites should definitely include removal of occlusal interferences and elimination of the functional shift. Treating posterior crossbites early may help prevent the occurrence of Temporomandibular joint pathology.[¹⁸]

Unilateral crossbites can also be diagnosed and treated properly by using a Deprogramming splint. This splint has flat occlusal surface which causes the muscles to deprogram themselves and establish new sensory engrams. When the splint is removed, a proper centric relation bite can be diagnosed from the bite.[¹⁹]

Self-correction

[edit]

Literature states that very few crossbites tend to self-correct which often justify the treatment approach of correcting these bites as early as possible.[⁹] Only 0–9% of crossbites self-correct. Lindner et al. reported that 50% of crossbites were corrected in 76 four-year-old children.[²⁰]

See also

[edit]

- List of palatal expanders
- Palatal expansion
- Malocclusion

References

[edit]

1. ^ "Elsevier: Proffit: Contemporary Orthodontics · Welcome". *www.contemporaryorthodontics.com*. Retrieved 2016-12-11.
2. ^ Borzabadi-Farahani A, Borzabadi-Farahani A, Eslamipour F (October 2009). "Malocclusion and occlusal traits in an urban Iranian population. An

- epidemiological study of 11- to 14-year-old children". *European Journal of Orthodontics*. **31** (5): 477–84. doi:10.1093/ejo/cjp031. PMID 19477970.
3. ^ **a b** Kutin, George; Hawes, Roland R. (1969-11-01). "Posterior cross-bites in the deciduous and mixed dentitions". *American Journal of Orthodontics*. **56** (5): 491–504. doi:10.1016/0002-9416(69)90210-3. PMID 5261162.
 4. ^ Zietsman, S. T.; Visagé, W.; Coetzee, W. J. (2000-11-01). "Palatal finger springs in removable orthodontic appliances--an in vitro study". *South African Dental Journal*. **55** (11): 621–627. ISSN 1029-4864. PMID 12608226.
 5. ^ Ulusoy, Ayca Tuba; Bodrumlu, Ebru Hazar (2013-01-01). "Management of anterior dental crossbite with removable appliances". *Contemporary Clinical Dentistry*. **4** (2): 223–226. doi:10.4103/0976-237X.114855. ISSN 0976-237X. PMC 3757887. PMID 24015014.
 6. ^ Al-Hummayani, Fadia M. (2017-03-05). "Pseudo Class III malocclusion". *Saudi Medical Journal*. **37** (4): 450–456. doi:10.15537/smj.2016.4.13685. ISSN 0379-5284. PMC 4852025. PMID 27052290.
 7. ^ Bjoerk, A.; Krebs, A.; Solow, B. (1964-02-01). "A Method for Epidemiological Registration of Malocclusion". *Acta Odontologica Scandinavica*. **22**: 27–41. doi:10.3109/00016356408993963. ISSN 0001-6357. PMID 14158468.
 8. ^ Moyers, Robert E. (1988-01-01). *Handbook of orthodontics*. Year Book Medical Publishers. ISBN 9780815160038.
 9. ^ **a b c** Thilander, Birgit; Lennartsson, Bertil (2002-09-01). "A study of children with unilateral posterior crossbite, treated and untreated, in the deciduous dentition--occlusal and skeletal characteristics of significance in predicting the long-term outcome". *Journal of Orofacial Orthopedics*. **63** (5): 371–383. doi:10.1007/s00056-002-0210-6. ISSN 1434-5293. PMID 12297966. S2CID 21857769.
 10. ^ Thilander, Birgit; Wahlund, Sonja; Lennartsson, Bertil (1984-01-01). "The effect of early interceptive treatment in children with posterior cross-bite". *The European Journal of Orthodontics*. **6** (1): 25–34. doi:10.1093/ejo/6.1.25. ISSN 0141-5387. PMID 6583062.
 11. ^ Allen, David; Rebellato, Joe; Sheats, Rose; Ceron, Ana M. (2003-10-01). "Skeletal and dental contributions to posterior crossbites". *The Angle Orthodontist*. **73** (5): 515–524. ISSN 0003-3219. PMID 14580018.
 12. ^ Bresolin, D.; Shapiro, P. A.; Shapiro, G. G.; Chapko, M. K.; Dassel, S. (1983-04-01). "Mouth breathing in allergic children: its relationship to dentofacial development". *American Journal of Orthodontics*. **83** (4): 334–340. doi:10.1016/0002-9416(83)90229-4. ISSN 0002-9416. PMID 6573147.

13. ^ **a b** Ogaard, B.; Larsson, E.; Lindsten, R. (1994-08-01). "The effect of sucking habits, cohort, sex, intercanine arch widths, and breast or bottle feeding on posterior crossbite in Norwegian and Swedish 3-year-old children". *American Journal of Orthodontics and Dentofacial Orthopedics*. **106** (2): 161–166. doi:10.1016/S0889-5406(94)70034-6. ISSN 0889-5406. PMID 8059752.
14. ^ Piancino, Maria Grazia; Kyrkanides, Stephanos (2016-04-18). *Understanding Masticatory Function in Unilateral Crossbites*. John Wiley & Sons. ISBN 9781118971871.
15. ^ Brin, Ilana; Ben-Bassat, Yocheved; Blustein, Yoel; Ehrlich, Jacob; Hochman, Nira; Marmary, Yitzhak; Yaffe, Avinoam (1996-02-01). "Skeletal and functional effects of treatment for unilateral posterior crossbite". *American Journal of Orthodontics and Dentofacial Orthopedics*. **109** (2): 173–179. doi:10.1016/S0889-5406(96)70178-6. PMID 8638566.
16. ^ Pullinger, A. G.; Seligman, D. A.; Gornbein, J. A. (1993-06-01). "A multiple logistic regression analysis of the risk and relative odds of temporomandibular disorders as a function of common occlusal features". *Journal of Dental Research*. **72** (6): 968–979. doi:10.1177/00220345930720061301. ISSN 0022-0345. PMID 8496480. S2CID 25351006.
17. ^ COSTEA, CARMEN MARIA; BADEA, MÎNDRA EUGENIA; VASILACHE, SORIN; MESAROĂfâ€!Ă...Ă¼, MICHAELA (2016-01-01). "Effects of CO-CR discrepancy in daily orthodontic treatment planning". *Clujul Medical*. **89** (2): 279–286. doi:10.15386/cjmed-538. ISSN 1222-2119. PMC 4849388. PMID 27152081.
18. ^ Kennedy, David B.; Osepchook, Matthew (2005-09-01). "Unilateral posterior crossbite with mandibular shift: a review". *Journal (Canadian Dental Association)* . **71** (8): 569–573. ISSN 1488-2159. PMID 16202196.
19. ^ Nielsen, H. J.; Bakke, M.; Blixencrone-Møller, T. (1991-12-01). "[Functional and orthodontic treatment of a patient with an open bite craniomandibular disorder]". *Tandlaegebladet*. **95** (18): 877–881. ISSN 0039-9353. PMID 1817382.
20. ^ Lindner, A. (1989-10-01). "Longitudinal study on the effect of early interceptive treatment in 4-year-old children with unilateral cross-bite". *Scandinavian Journal of Dental Research*. **97** (5): 432–438. doi:10.1111/j.1600-0722.1989.tb01457.x. ISSN 0029-845X. PMID 2617141.

External links

[edit]

Classification

- ICD-10: K07.2 D
- ICD-9-CM:
524.27

- v
- t
- e

Orthodontics

Diagnosis

- Bolton analysis
- Cephalometric analysis
- Cephalometry
- Dentition analysis
- Failure of eruption of teeth
- Little's Irregularity Index
- Malocclusion
- Scissor bite
- Standard anatomical position
- Tooth ankylosis
- Tongue thrust

Conditions

- Overbite
- Overjet
- Open bite
- Crossbite
- Dental crowding
- Dental spacing
- Bimaxillary Protrusion
- Prognathism
- Retrognathism
- Maxillary hypoplasia
- Condylar hyperplasia
- Overeruption
- Mouth breathing
- Temporomandibular dysfunction

- ACCO appliance
- Archwire
- Activator appliance
- Braces
- Damon system
- Elastics
- Frankel appliance
- Invisalign
- Lingual arch
- Lip bumper
- Herbst Appliance
- List of orthodontic functional appliances

Appliances

- List of palatal expanders
- Lingual braces
- Headgear
- Orthodontic technology
- Orthodontic spacer
- Palatal lift prosthesis
- Palatal expander
- Quad helix
- Retainer
- SureSmile
- Self-ligating braces
- Splint activator
- Twin Block Appliance

Procedures

- Anchorage (orthodontics)
- Cantilever mechanics
- Fiberotomy
- Interproximal reduction
- Intrusion (orthodontics)
- Molar distalization
- SARPE
- Serial extraction
- Beta-titanium
- Nickel titanium
- Stainless steel

Materials

- TiMolium
- Elgiloy
- Ceramic
- Composite
- Dental elastics

- Edward Angle
- Spencer Atkinson
- Clifford Ballard
- Raymond Begg
- Hans Peter Bimler
- Samir Bishara
- Arne Björk
- Charles B. Bolton
- Holly Broadbent Sr.
- Allan G. Brodie
- Charles J. Burstone
- Peter Buschang
- Calvin Case
- Harold Chapman (Orthodontist)
- David Di Biase
- Jean Delaire
- Terry Dischinger
- William B. Downs
- John Nutting Farrar
- Rolf Frankel
- Sheldon Friel
- Thomas M. Graber
- Charles A. Hawley
- Reed Holdaway
- John Hooper (Orthodontist)
- Joseph Jarabak
- Harold Kesling
- Albert Ketcham
- Juri Kurol
- Craven Kurz
- Benno Lischer
- James A. McNamara
- Birte Melsen
- Robert Meyers

**Notable
contributors**

- American Association of Orthodontists
- American Board of Orthodontics
- British Orthodontic Society
- Organizations**
 - Canadian Association of Orthodontists
 - Indian Orthodontic Society
 - Italian Academy of Orthodontic Technology
 - Society for Orthodontic Dental Technology (Germany)
 - American Journal of Orthodontics and Dentofacial Orthopedics
- Journals**
 - The Angle Orthodontist
 - Journal of Orthodontics
- Institution**
 - Angle School of Orthodontia

- v
- t
- e

Dental disease involving the jaw

- General**
 - Jaw abnormality
 - malocclusion
 - Orthodontics
 - Gnathitis
- Size**
 - Micrognathism
 - Maxillary hypoplasia
 - Cherubism
- Maxilla and Mandible**
 - Congenital epulis
 - Torus mandibularis
 - Torus palatinus

Other

- Jaw and base of cranium
 - Prognathism
 - Retrognathism
- Dental arch
 - Crossbite
 - Overbite
- Temporomandibular joint disorder

Authority control databases: **National** Image not found or the unknown **Germany**
Edit this at Wikidata

Check our other pages :

- [How Orthodontics Connects With Periodontal Health](#)
- [Post Surgical Follow Ups With Multiple Specialists](#)
- [Building a Unified Strategy for Long Term Stability](#)

IQDENT – Ortodontska Klinika

Phone : +385953817015

City : Zagreb

State : Hrvatska

Zip : 10000

Address : IQDENT – Ortodontska Klinika

Company Website : <https://iqdent.hr/>

USEFUL LINKS

[Orthodontic treatment can help improve your child's smile](#)

[Orthodontic treatment for children](#)

[Sitemap](#)

[Privacy Policy](#)

[About Us](#)

Follow us