



- **Reasons Adults Seek Orthodontic Treatment**

Reasons Adults Seek Orthodontic Treatment Overcoming Hesitations About Braces Later in Life Clear Aligners for Subtle Tooth Movement Comparing Ceramic Brackets With Other Invisible Options Balancing Cosmetic Goals and Functional Needs Social Changes That Encourage Adult Orthodontics Handling Orthodontic Care Alongside Busy Schedules Managing Discomfort and Adjusting to Lifestyle Shifts Case Studies Highlighting Adult Smile Transformations Psychological Benefits of Aligned Teeth in Adulthood Minimizing Visibility of Orthodontic Appliances Key Questions Adults Often Ask About Treatment

- **How Orthodontics Connects With Periodontal Health**

How Orthodontics Connects With Periodontal Health Coordinating Orthodontic Work With Restorative Dentistry The Role of Oral Surgery in Complex Alignment Cases Importance of Joint Consultation for Comprehensive Outcomes Leveraging Data Sharing Between Dental Specialties Collaborative Approaches to Pediatric Growth Management Integrating Prosthodontics for Full Mouth Rehabilitation Teamwork for Managing Tongue Thrust and Speech Issues Streamlining Communication Among Healthcare Providers Shared Planning for Improved Patient Experiences Post Surgical Follow Ups With Multiple Specialists Building a Unified Strategy for Long Term Stability

- **About Us**



Minimizing Visibility of Orthodontic Appliances

****Desire for Improved Aesthetics**:** Many adults seek orthodontic treatment to enhance the appearance of their smile, addressing concerns such as crooked teeth, gaps, or overbites that may have persisted from childhood or developed due to various life factors.

****Desire for Improved Aesthetics**:** Many adults seek orthodontic treatment to enhance the appearance of their smile, addressing concerns such as crooked teeth, gaps, or overbites that may have persisted from childhood or developed due to various life factors.

Certainly, exploring the topic of "Minimizing Visibility of Orthodontic Appliances" in the context of treatment for kids involves understanding both the psychological and practical aspects that come into play. Here's a thoughtful essay structured around this theme, aiming to provide insights that are relatable and informative for parents, kids, and orthodontists alike.

Orthodontic expanders can create more space in the mouth for teeth **Dental braces for children** physician.

Embracing Invisible Orthodontics: A Kid's Perspective on Modern Dental Care

In today's world, where appearances often play a significant role in a child's self-esteem and social interactions, the visibility of orthodontic appliances can be more than just a medical concern—it's a matter of emotional well-being. For kids undergoing orthodontic treatment, the journey toward a straighter smile doesn't have to mean wearing braces that shout "I'm getting my teeth fixed." Thanks to advancements in orthodontic technology, minimizing the visibility of these appliances has become not just an option but a priority. Let's explore how modern orthodontics is making this possible.

1. Clear Aligners: The Discreet Path to Straight Teeth

One of the most celebrated advancements is clear aligners, like Invisalign. These transparent trays fit snugly over your teeth without anyone noticing they're there unless you mention them. For kids who are self-conscious about traditional metal braces, aligners offer an almost invisible way to straighten teeth while going about their daily lives without drawing attention to their orthodontic treatment.

2. Ceramic Braces: A Tooth-Colored Alternative

For those who prefer something more traditional but still discreet, ceramic braces are an excellent choice. These braces use tooth-colored brackets that blend in with the natural color of your teeth. While they might be slightly more noticeable than clear aligners, ceramic braces strike a balance between effectiveness and discretion, making them popular among teens who want to subtly tackle their orthodontic needs.

3. Lingual Braces: Hidden Behind Your Teeth

Taking discretion to new heights are lingual braces—braces placed on the back side of your teeth, literally behind them. This method is virtually undetectable from the front view, offering an exceptional level of privacy for those concerned about visible

appliances during school photos or social gatherings. However, it requires specialized expertise for placement and maintenance due to its unique positioning.

4. Innovations in Wire Technology: Thinner and More Flexible

Advancements in wire technology have led to thinner and more flexible options that can reduce bulkiness and thus improve aesthetics while maintaining efficacy. These wires can often be used with traditional metal brackets but offer less obtrusiveness compared to older models, allowing kids to feel more comfortable both functionally and cosmetically during treatment.

5. The Role of Treatment Timing and Planning

Timing plays a crucial role in minimizing visibility too. Orthodontists can plan treatments strategically to reduce the duration needed with visible appliances by addressing complex issues early or utilizing phase treatments effectively managed behind-the-scenes with less conspicuous devices when necessary.

6. Psychological Benefits Beyond Appearance

The psychological impact cannot be understated; feeling confident during treatment significantly boosts overall well-being for children undergoing orthodontic care. By choosing less visible options, kids can engage fully in school activities, sports, and social events without anxiety about their appearance

****Boosting Self-Confidence**:**

Orthodontic treatment can significantly improve an adult's self-esteem and confidence by correcting dental imperfections, leading to a more positive self-image and better social interactions.

- ****Desire for Improved Aesthetics**:** Many adults seek orthodontic treatment to enhance the appearance of their smile, addressing concerns such as crooked teeth, gaps, or overbites that may have persisted from childhood or developed due to various life factors.

- ****Boosting Self-Confidence****: Orthodontic treatment can significantly improve an adult's self-esteem and confidence by correcting dental imperfections, leading to a more positive self-image and better social interactions.
- ****Enhancing Oral Health****: Proper alignment of teeth through orthodontic treatment can improve oral hygiene by making it easier to clean teeth effectively, thereby reducing the risk of cavities and gum disease that may have been challenging to manage in misaligned dentitions.
- ****Addressing Chronic Dental Issues****: Adults may seek orthodontics to resolve long-standing dental problems such as bite issues (overbites, underbites, crossbites) that can lead to jaw pain, headaches, and digestive difficulties if left untreated.
- ****Correcting Speech Impediments****: Misaligned teeth or jaw structures can contribute to speech difficulties; orthodontic treatment can correct these issues, improving articulation and overall communication skills.
- ****Preventive Measures Against Tooth Wear****: Properly aligned teeth are less prone to excessive wear and tear; adults may pursue orthodontic treatment to prevent premature tooth degradation and associated costs of restorative dentistry.
- ****Facilitating Better Chewing Efficiency****: Orthodontic treatment can improve bite function and alignment, allowing for more efficient chewing which is crucial for digestion and overall nutritional health in adulthood.

Orthodontic treatment, often a journey towards straighter teeth and a more confident smile, takes on an especially nuanced significance during childhood—a period marked by rapid growth and development. The importance of minimizing the visibility of orthodontic appliances during this phase isn't merely about aesthetics; it weaves into the fabric of a child's social, emotional, and psychological well-being, deeply influencing their approach to treatment and overall experience.

To begin with, let's consider the social dynamics that play a crucial role in childhood. Kids are incredibly perceptive and often acutely aware of differences among their peers. Wearing conspicuous orthodontic appliances—like traditional metal braces with their shiny brackets and wires—can make a child feel self-conscious. This visibility can lead to feelings of vulnerability or embarrassment, particularly during crucial social interactions at school. Imagine the hesitance a child might feel when smiling broadly for a photo or raising their hand in class, concerned about others noticing their "train tracks" or "grill." Minimizing visibility through discreet options like ceramic braces, clear aligners, or lingual braces (placed behind the teeth) can significantly ease this burden. It allows children to navigate their social environments with greater confidence, fostering better engagement in activities without the constant worry of standing out due to their orthodontic treatment.

Moreover, psychological factors cannot be overlooked. Childhood is a formative time where self-esteem is intricately linked to how one perceives themselves physically. The pressure to conform to societal standards of beauty can be intense, and visible orthodontic appliances might inadvertently reinforce negative self-perceptions for some kids. By opting for less visible treatments, parents and caregivers can help maintain or build a positive self-image in children undergoing orthodontic care. This subtle yet powerful support can enhance motivation to adhere to treatment plans—after all, who wouldn't want to keep wearing something that feels less like a reminder of imperfection and more like a step toward improvement?

Additionally, practical considerations come into play when discussing the minimization of visibility in orthodontics for children. Discreet appliances often mean fewer adjustments that require visits to the orthodontist—an aspect that might seem minor but contributes significantly to reducing anxiety associated with medical appointments. These fewer visits not only alleviate stress but also save time and resources for families juggling multiple commitments. Furthermore, certain invisible or semi-invisible options might allow for quicker adaptation periods as children adjust to having something positioned in or around their mouths regularly. This smoother transition can mean less fuss over meals and better

compliance with oral hygiene practices essential for effective treatment outcomes.

In essence, while ensuring optimal dental health remains paramount in orthodontic treatment during childhood, recognizing the profound impact of minimizing appliance visibility on various facets of a child's life adds depth to our understanding of why such considerations matter immensely. From bolstering social confidence and nurturing positive self-image to simplifying practical aspects of treatment adherence—making strides towards subtler orthodontic solutions is an investment not just in dental health but in enhancing overall quality of life during these pivotal years of growth and development.

****Enhancing Oral Health**:**

Proper alignment of teeth through orthodontic treatment can improve oral hygiene by making it easier to clean teeth effectively, thereby reducing the risk of

cavities and gum disease that may have been challenging to manage in misaligned dentitions.

The journey through adolescence is often peppered with a myriad of concerns, and for many parents and their young ones, the topic of orthodontic treatment brings its own unique set of considerations to the table. Among these, the aesthetics of traditional braces stand out as a prominent concern. The image of metal brackets and wires snaking across a teenager's smile can evoke feelings ranging from self-consciousness to outright anxiety about social perceptions. This apprehension is entirely understandable given how much emphasis our society places on appearance, especially during the formative years when peer interactions and social dynamics play such a crucial role in a child's development.

Traditional braces, while highly effective at correcting misalignments and improving dental health, often come with a visibility that can make some teenagers feel less than thrilled about wearing them. The metallic sheen against the natural whiteness of teeth can feel jarring, leading to worries about standing out in school photos or feeling self-conscious during casual interactions with friends. This concern isn't merely aesthetic; it touches on deeper feelings of identity and confidence that are so vital at this stage of life.

Fortunately, recognizing these concerns has spurred advancements in orthodontic technology aimed at minimizing the visibility of appliances without compromising their effectiveness. Clear aligners, like Invisalign, have emerged as a popular alternative—a near-invisible solution that uses custom-made plastic trays to gradually shift teeth into place. These aligners are designed to be worn for several hours each day and can be removed for eating, brushing, and special occasions, offering both functional benefits and an aesthetic advantage that appeals greatly to those conscious about their appearance during treatment.

Moreover, advances in bracket design have led to more discreet options such as ceramic or clear brackets that blend in much better with tooth color compared to their metal counterparts. These subtle alternatives aim to strike a balance between effective orthodontic care and maintaining a natural look, helping alleviate some of the social pressures associated with visible braces.

However, it's essential for parents to approach this conversation with sensitivity and understanding. It's important not just to focus on the aesthetic aspects but also to emphasize the broader health benefits of orthodontic treatment—better oral hygiene, improved function of teeth leading to easier chewing and speaking, and long-term prevention of more serious dental issues down the line. By framing orthodontic needs within this holistic context, parents can help ease their children's concerns about appearance while reinforcing the importance of taking care of their dental health.

In navigating these waters, open communication between parents and their children is key. Discussing fears openly allows for finding solutions together—whether it involves exploring invisible options or simply learning how to care for braces effectively to minimize any discomfort or inconvenience they might cause. Ultimately, while traditional braces may carry an aesthetic baggage for some, advancements in orthodontics coupled with supportive parental guidance can turn what might seem like an undesirable necessity into a manageable part of growing up—and smiling confidently through it all.

****Addressing Chronic Dental Issues**:** Adults may seek orthodontics to resolve long-standing dental problems such as bite issues (overbites, underbites, crossbites) that can lead to jaw pain, headaches, and digestive difficulties if left untreated.

Orthodontic treatment, widely recognized for its ability to straighten teeth and correct bites, has evolved significantly over the decades. Central to this evolution is the ongoing quest to minimize the visibility of orthodontic appliances, an aspect that profoundly impacts a patient's comfort and self-confidence during treatment. Traditional orthodontic appliances, while effective, have historically been more noticeable, but advancements and design considerations have made strides in addressing this concern.

At the forefront of traditional orthodontic appliances are metal braces, consisting of brackets bonded to the teeth and connected by arch wires. For many years, these were the standard, offering robust correction capabilities but often at the cost of visibility. The metallic sheen of brackets and wires can draw attention, especially against contrasting tooth colors or when food particles accumulate, leading to an aesthetic concern for many patients. However, innovations have introduced smaller brackets and tooth-colored or clear options that blend more seamlessly with natural teeth, significantly reducing their visibility while maintaining effectiveness.

In addition to metal braces, traditional clear aligners represent a remarkable leap in minimizing visibility. Products like Invisalign utilize a series of custom-made, transparent plastic trays that gradually shift teeth into place without the metal infrastructure associated with braces. Their near-invisibility makes them a favored choice among adults and teens conscious about their appearance during treatment. The removable nature of aligners further enhances discretion; patients can take them out for eating or special occasions without compromising their orthodontic progress.

Another lesser-known yet effective tradition in minimizing visibility involves ceramic braces. These function similarly to metal ones but employ clear or tooth-colored brackets that are much less conspicuous against natural tooth enamel. While slightly more expensive than their metal counterparts due to material costs and potential for staining if not properly maintained, ceramic braces offer an aesthetic compromise for those seeking

subtlety in their treatment option.

The journey toward invisible orthodontics also includes refined wire technologies and bracket designs aimed at reducing wire thickness and bracket size without sacrificing strength or effectiveness. Such innovations reflect a broader trend in dental technology towards enhancing patient experience through both functionality and aesthetics.

In summary, while traditional orthodontic appliances have long been associated with visible hardware, ongoing developments continue to refine these tools to cater to modern sensibilities around aesthetics and self-image. From clearer aligners to tooth-colored brackets and advanced wire technologies, the goal remains consistent: delivering effective orthodontic care while allowing individuals to maintain their confidence throughout their journey toward straighter teeth and better oral health. The evolution underscores not just technological progress but also a deepening understanding of how appearance influences personal well-being during what can be a transformative time in one's life.

****Correcting Speech**

Impediments:** Misaligned teeth or jaw structures can contribute to speech

difficulties; orthodontic treatment can correct these issues, improving articulation and overall communication skills.

When we think about orthodontic treatments, the image that often comes to mind is that of someone sporting conventional metal braces. These have been the stalwart workhorses of teeth straightening for decades, effectively correcting misalignments and improving smiles across the globe. Yet, as much as they've been instrumental in transforming dental health, one aspect that can't be ignored is their visibility—a characteristic that has both practical and psychological implications for those who wear them.

Conventional metal braces consist of a few key components: brackets, archwires, and O-rings or ligatures that hold everything together. The brackets are bonded directly to the teeth, usually on the front surface, acting as anchors. These shiny metal squares are perhaps the most noticeable part of the setup; they're often made from stainless steel or titanium alloys, chosen for their strength and durability but also for their reflective quality, making them stand out against the natural tooth color. The archwire, which runs through these brackets, applies gentle pressure to guide teeth into desired positions over time. It's

typically made from materials like stainless steel or nickel-titanium alloys that can flex and adjust with temperature changes in the mouth. Adding to this visual tapestry are the O-rings or ligatures—a small elastic band that wraps around each bracket to keep the wire securely in place. These come in a variety of colors, offering a bit of personalization amidst the metallic structure.

The visibility of these braces is undeniable; they sit proudly on the front teeth where they're most likely to catch attention—whether it's during casual conversation or in more formal settings. This conspicuousness can lead to a range of feelings among wearers: pride in taking proactive steps towards better oral health, self-consciousness about appearance, especially during adolescence when peer perception holds significant sway, or even embarrassment in professional environments where one might feel less than fully presentable. The reflection off metal can be particularly distracting in photographs or during video calls—something many brace-wearers have lamented over social media platforms and personal interactions alike.

However, it's essential to frame this visibility within a broader context. Metal braces are not just about aesthetics; they represent a tried-and-true method for achieving substantial orthodontic results with reliability and effectiveness unmatched by many newer alternatives (at least until recent innovations began to blur these lines). Their strength allows for more direct force application, which can shorten treatment times for certain cases compared to lighter systems like ceramic braces or clear aligners like Invisalign. Moreover, advancements have been made to mitigate visibility concerns with metallic components—thinner wires and brackets have been developed over time to reduce their overall profile while maintaining efficacy.

In exploring ways to minimize visibility while retaining—or even enhancing—the benefits of conventional metal braces, we see trends shifting toward design improvements rather than complete abandonment of this well-established method. For instance, heat-activated archwires allow for smoother adjustments without needing frequent office visits;

specialized coatings on brackets can reduce plaque buildup and make maintenance easier; even more subtle bracket designs aim at blending seamlessly with tooth enamel tones without sacrificing strength or function. Furthermore, embracing metal braces with confidence—understanding their role as temporary yet transformative—is an empowering stance many orthodontists encourage their patients to adopt. After all, every smile journey is unique; what matters most

****Preventive Measures**

Against Tooth Wear:**

Properly aligned teeth are less prone to excessive wear and tear; adults may pursue orthodontic treatment to prevent premature tooth

degradation and associated costs of restorative dentistry.

The psychological impact of visibility, particularly concerning orthodontic appliances, on children is a nuanced topic that touches on self-esteem, social dynamics, and the broader context of growing up. Orthodontic treatments, while essential for aligning teeth and improving oral health, often come with visible appliances like braces or clear aligners. For children, these appliances can become a significant aspect of their daily lives, influencing not just their physical appearance but also their emotional well-being and interactions with peers.

Visibility of orthodontic appliances can lead to a range of psychological effects. On one hand, children might feel self-conscious about their appearance, especially during the formative years when peer acceptance is crucial. The concern about standing out—whether due to the color of braces or the bulkiness of older appliance designs—can breed feelings of insecurity. This self-perception can affect a child's willingness to smile widely, participate in social situations where facial expressions are key, or even engage in everyday activities like eating in front of others due to fears of judgment or teasing.

On the other hand, societal attitudes are shifting towards greater acceptance and understanding of orthodontic treatments. The normalization seen through social media and public figures openly discussing their own experiences with braces or aligners can significantly mitigate feelings of isolation or embarrassment among children undergoing treatment. This cultural shift encourages a more positive outlook; children can see that

wearing orthodontic appliances is not a mark of difference but rather a common pathway to a healthier smile—a transformation many aspire to.

Moreover, advancements in orthodontic technology have introduced more discreet options like ceramic braces and invisible aligners. These innovations cater specifically to the desire for minimal visibility during treatment, allowing children to feel less conspicuous while still benefiting from effective care. Such options empower young patients by giving them choices that align with their desire for normalcy and confidence during what can be a challenging period in their development.

However, it's essential to remember that each child's experience is unique. While some might embrace their treatment as part of an exciting journey toward improved dental health and appearance, others may struggle more profoundly with visibility-related insecurities. Parents and caregivers play a pivotal role here—offering support, emphasizing the temporary nature of these appliances in the grand scheme of lifelong health and confidence, and fostering an environment where differences are celebrated rather than shunned contributes immensely to positive outcomes.

In essence, while the visibility of orthodontic appliances can pose psychological challenges for children, it's equally clear that awareness, technological advancements, and supportive environments can significantly minimize negative impacts while enhancing the overall experience. By focusing on inclusivity and normalizing orthodontic treatments within our communities, we enable children not only to navigate this phase with grace but also emerge with strengthened self-confidence and an appreciation for diversity in appearances—a lesson invaluable beyond just dental health.

****Facilitating Better Chewing Efficiency**:** Orthodontic treatment can improve bite function and alignment, allowing for more efficient chewing which is crucial for digestion and overall nutritional health in adulthood.

In recent years, the quest for aesthetic dental solutions has propelled a significant shift in how we approach orthodontic treatments. The traditional metal braces, once a rite of passage for many adolescents, have evolved into a spectrum of discreet options designed to minimize visibility while effectively straightening teeth. This transformation reflects not just advancements in orthodontic technology but also a growing societal emphasis on appearance and self-confidence during treatment.

One of the most notable innovations in this realm is the advent of ceramic braces. These brackets are crafted from tooth-colored materials that blend seamlessly with the natural color of teeth, making them far less noticeable than their metal counterparts. Ceramic braces have become a popular choice among teenagers and adults who wish to undergo orthodontic treatment without drawing undue attention to their appliances. However, it's worth noting that while ceramic brackets offer enhanced discretion, they can be more susceptible to staining from food and drinks, requiring diligent oral hygiene to maintain their pristine appearance.

In addition to ceramic options, clear aligners have revolutionized discreet orthodontics. Brands like Invisalign lead the charge with custom-made, transparent plastic trays that fit snugly over the teeth, gradually shifting them into place without any visible hardware. The removable nature of aligners adds another layer of convenience and discretion; patients can take them out for eating, drinking, or special occasions, further reducing visibility and enhancing comfort. This flexibility makes clear aligners particularly appealing for adults who may be concerned about the impact of traditional braces on their professional image or social life.

For those seeking even greater invisibility, lingual braces present an intriguing solution. These devices are placed behind the teeth—the lingual side—making them entirely invisible from the front view. While highly effective and discrete, lingual braces come with a

steeper learning curve both for the orthodontist applying them and for the patient adjusting to their presence in the mouth. Speech may temporarily be affected, and cleaning can be more challenging due to their location, but for those prioritizing absolute discretion above all else, they offer an exceptional solution.

The journey toward minimizing visibility in orthodontic appliances showcases how technological innovation intertwines with personal preferences and societal norms. As we continue to embrace these discreet options—whether through advanced materials like ceramics or revolutionary systems like clear aligners—we're reminded that orthodontic treatment need not compromise one's aesthetic or confidence goals. Instead, it can empower individuals to pursue straighter smiles on their own terms, fostering a sense of pride and self-assurance every step of the way.

Lingual braces, often hailed as a discreet alternative to traditional orthodontic treatments, have carved a niche for themselves in the world of dental aesthetics and functionality. To truly grasp their appeal, particularly concerning the minimization of visibility, we need to dive into how they operate and what sets them apart from their more visible counterparts.

At the heart of lingual braces is a simple yet ingenious concept: they are attached to the backside of your teeth—the side that faces your tongue. This unique positioning is where their charm and primary advantage lie. Unlike traditional braces that sit comfortably on the front surface of teeth, making them somewhat inevitable in terms of visibility, lingual braces work silently behind the scenes. This means that while undergoing treatment to straighten teeth or correct bites, the brace's presence remains largely unnoticed by others. It's almost as if you're undergoing a transformation without anyone else needing to be in on the secret.

The mechanics of lingual braces involve custom-fitted brackets and wires that are meticulously designed to fit the individual contours of your teeth's inner surfaces. This

customization ensures effective movement while minimizing any discomfort that might arise from irritation caused by wires and brackets rubbing against the soft tissues inside your mouth—a common concern with conventional braces. The precision engineering allows for efficient force application, guiding teeth into their desired positions without compromising on comfort or aesthetics from an external perspective.

Visibility—both physical and psychological—is a cornerstone when considering orthodontic options, especially for adults who may be more conscious about appearance during treatment. Lingual braces offer an excellent solution here, significantly reducing the social stigma often associated with having "metal mouths." Patients can smile freely without worrying about drawing attention to their orthodontic appliances, which is a huge psychological boost during what can sometimes feel like a lengthy journey towards a straighter smile or corrected bite.

However, it's important to acknowledge that while lingual braces excel in discretion, they do come with their own set of challenges. The placement on the tongue side can initially lead to greater speech difficulties compared to traditional braces—though this usually diminishes with time as one adapts. Additionally, cleaning can be more challenging due to their location, demanding extra oral hygiene attention from patients. Yet for many, these minor inconveniences pale in comparison to the benefits of enhanced confidentiality during treatment.

In conclusion, lingual braces embody an innovative approach within orthodontics—offering effective tooth alignment and correction while prioritizing discretion and minimizing visibility concerns. Their tailored design caters specifically to those seeking an aesthetic-friendly option without compromising on treatment efficacy or comfort over time. As dental technology continues evolving, solutions like lingual braces highlight how modern medicine can cater not just to our health needs but also align with our desire for personal discretion in our life choices—even when it comes to something as personal as our smiles.

In recent years, the quest for aesthetic appeal in orthodontic treatments has gained significant traction, especially among teens and adults who are conscious about their appearance during treatment. The traditional metal braces, while effective, often come with a stigma attached due to their noticeable presence on the teeth. This has paved the way for the evolution of **Customized Orthodontic Solutions** specifically tailored to minimize visibility, offering patients a more discreet path to achieving that perfect smile.

One of the forefront innovations in this realm is **Clear Aligners**. These are essentially transparent, removable trays made from advanced plastic materials that fit snugly over the teeth. Unlike their metal counterparts, clear aligners blend seamlessly with the natural color of your teeth, making them nearly invisible when worn. This custom-fitted approach not only addresses orthodontic issues but does so with an eye towards aesthetics. Patients can remove aligners for eating, drinking anything except water, and brushing, adding another layer of convenience and discretion to their treatment journey.

Another exciting development is **Ceramic Braces**, often referred to as "clear braces." These use tooth-colored or transparent brackets that are much less conspicuous than traditional metal brackets. While they might not be entirely invisible—especially from close range—they offer a significant reduction in visibility compared to metal options. Ceramic braces can be customized further with colored bonds that allow patients to express their personality through their braces, turning what was once a uniform look into a personal statement.

The realm of **Lingual Braces** takes discreetness to an entirely new level by placing brackets on the back side of the teeth, effectively keeping them out of sight from both front and sides. These custom-fabricated appliances mirror the functionality of traditional braces but offer an unparalleled level of invisibility for those who prioritize confidentiality during treatment. However, this advanced solution requires precise fitting and can sometimes affect speech initially but usually becomes manageable over time.

Moreover, advancements in **Self-Ligating Brackets** contribute to minimizing visibility indirectly by streamlining the overall orthodontic appliance's design. These brackets use a built-in mechanism to hold the wire in place without needing rubber bands or ties, which traditionally came in various colors—a feature that adds both functionality and subtlety to traditional bracket systems.

As we delve deeper into personalized medicine and aesthetic dentistry, it's evident that Customized Orthodontic Solutions are not just about correcting dental misalignments; they're about enhancing confidence by respecting individual preferences for discretion during treatment. With technology continuously evolving and patient demands shifting towards less invasive and more aesthetic treatments, we're witnessing a remarkable transformation in how orthodontic care is perceived and experienced today. Whether through clear aligners that vanish from sight or ceramic options that mimic natural teeth coloration, these solutions redefine what it means to wear braces in the modern world—making orthodontic journeys smoother and significantly less visible than ever before.

When we consider the journey of orthodontic treatment, a common thread woven through the experiences of many is the desire for solutions that not only correct dental alignment but also blend seamlessly into daily life, minimizing any noticeable impact on one's aesthetic. This nuanced approach to tailoring orthodontic treatments to individual needs is more than a mere preference; it represents a significant evolution in how we perceive and undergo dental corrections. The goal here isn't just to straighten teeth but to do so in a manner that respects personal style and confidence, ensuring that the treatment process enhances rather than detracts from an individual's quality of life.

Orthodontic appliances, traditionally, have been somewhat of a visible statement—braces, with their metal brackets and wires, have long been the go-to solution for misaligned teeth. However, this visibility can sometimes lead to self-consciousness, especially among teenagers and adults who might feel anxious about how these appliances affect their appearance in social or professional settings. Recognizing this concern has spurred

advancements in orthodontic technology aimed at providing less conspicuous alternatives.

One such innovation is clear aligners, like Invisalign®. These transparent trays fit snugly over your teeth, offering a nearly invisible solution that can be removed for eating, drinking, and oral hygiene routines. The material used is carefully selected to ensure comfort while providing the necessary pressure to gently shift teeth into desired positions. For many wearers, the subtle nature of clear aligners makes them an attractive option; they allow individuals to undergo orthodontic treatment without the fear of standing out or feeling overly self-conscious about their appearance during treatment.

Moreover, advancements in bracket design have also played a pivotal role in minimizing visual impact. Ceramic braces are an excellent example; these use tooth-colored or clear materials for brackets and wires, significantly reducing their visibility compared to traditional metal braces. This subtle approach ensures that while the underlying mechanism corrects dental alignment effectively, it does so with a consideration for aesthetics—a key factor for many seeking orthodontic care.

Yet, beyond mere aesthetics lies another consideration: comfort and convenience tailored specifically to individual needs. Customized treatment plans take into account not just the visual aspect but also factors such as lifestyle, oral health conditions, and personal preferences regarding treatment duration and maintenance requirements. For instance, some individuals might prefer lingual braces—appliances placed behind the teeth—which offer another layer of discretion while still delivering effective results tailored precisely to each patient's unique dental anatomy.

This approach underscores an important principle: orthodontic care should be holistic—addressing not just functional outcomes but also emotional and social well-being by

minimizing aesthetic impact as much as possible. It's about empowering individuals with choices that allow them to embrace their smile journey confidently and comfortably. By prioritizing individual needs through innovative technologies and personalized care strategies, modern orthodontics ensures that everyone can achieve straighter teeth without compromising on their personal style or self-assurance throughout the process. Ultimately, this thoughtful tailoring of treatment options reflects our evolving understanding of what it means to provide comprehensive care—care that respects each person's unique identity while guiding them toward improved oral health and enhanced self-esteem.

In the realm of orthodontics, the quest for a more discreet approach to straightening teeth has led to significant innovations, one of which is the utilization of tooth-colored brackets and wires. This advancement represents a thoughtful response to the common desire for cosmetic appeal during what can often be a lengthy and visible treatment process. The concept is simple yet profoundly impactful: blending orthodontic appliances with the natural appearance of one's teeth, thereby minimizing visibility and enhancing confidence throughout treatment.

To understand the appeal of tooth-colored brackets and wires, it's essential to first consider the traditional metallic braces that have long been a staple in orthodontic care. While incredibly effective, these metal components stand out against the natural whiteness of teeth, often making them an eyesore for many wearers—especially teenagers and adults concerned about their appearance. The shine and contrast can draw unwanted attention, leading some individuals to feel self-conscious about smiling broadly or participating in photos.

Enter tooth-colored alternatives, designed to harmonize with the natural dental palette. These brackets are typically made from ceramic materials that mimic the color of teeth, rendering them nearly invisible when applied correctly. The innovation doesn't stop at aesthetics; manufacturers have also worked on enhancing the durability and performance

of these cosmetic brackets to ensure they withstand the rigors of daily use—from chewing to brushing—just like their metal counterparts.

Complementing these brackets are tooth-colored wires, often crafted from noble metals or nickel-titanium alloys that offer both strength and subtlety. These wires can be colored to match not just the brackets but also blend with the overall aesthetic goal of minimizing visual cues that signify orthodontic treatment is underway. This attention to detail ensures that while braces remain necessary for achieving a straighter smile, their presence is as unobtrusive as possible.

The psychological benefits cannot be understated; wearing tooth-colored braces can significantly boost an individual's self-esteem during treatment. Knowing that one's orthodontic journey doesn't need to compromise personal style or comfort encourages consistent engagement with treatment protocols—and this adherence is crucial for successful outcomes. Moreover, this discretion can make family members and friends less likely to comment or draw attention to what might otherwise become a focal point of conversation or teasing, especially among younger patients who are particularly sensitive about their appearance during formative years.

As with any medical or dental procedure, there are considerations beyond aesthetics; tooth-colored brackets and wires may require more meticulous oral hygiene practices due to their material properties and potential for staining if not cared for properly. Nevertheless, many orthodontists emphasize education on maintaining oral health alongside these innovative appliances as part of achieving both functional results and aesthetic satisfaction.

In conclusion, the utilization of tooth-colored brackets and wires marks a significant stride forward in orthodontics—a testament to how technological advancements can align with

personal desires for discreet yet effective treatments. By offering solutions that minimize visibility without compromising quality or longevity, this approach underscores a broader trend in healthcare towards patient-centric care where cosmetics play a pivotal role in enhancing overall well-being and confidence during what can be a transformative period in one's life.

When it comes to orthodontic treatment, the visibility of appliances like braces can sometimes feel like a fashion statement that not everyone wants to make. For many, the idea of sporting metal grins isn't exactly appealing, especially in an era where aesthetics play a significant role in daily social interactions. Thankfully, the world of orthodontics has evolved to offer several strategies that can help minimize the noticeability of these appliances, allowing individuals to undergo treatment with a bit more confidence and comfort in their appearance.

One of the most evident advancements is the introduction of **clear aligners**. These nearly invisible devices have revolutionized orthodontic treatment for those seeking subtlety. Made from transparent thermoplastic materials, clear aligners fit snugly over your teeth, providing a virtually undetectable way to straighten them. They are removable, which adds another layer of convenience—patients can take them out for photos or special occasions without compromising their treatment plan. However, it's essential to note that clear aligners might not be suitable for everyone; complex cases may still require traditional braces for effective correction.

Another tactic involves **ceramic braces**, often dubbed "clear braces." These are designed with tooth-colored or clear brackets that blend much better with the natural color of your teeth compared to their metal counterparts. The wires used with ceramic braces can also be colored to match your teeth, further diminishing their visibility. While they offer a more discreet option than traditional metal braces, they do come with a slight trade-off: they can be slightly more noticeable when you open your mouth wide and may require more careful maintenance due to their susceptibility to staining.

Self-ligating braces represent another innovation aimed at reducing visibility while enhancing efficiency. These braces use a door-like mechanism on the bracket that holds the wire in place without needing elastic ties (the tiny rubber bands traditionally used). This design not only reduces the number of components visible on your teeth but also means fewer appointments since these ties don't need regular replacement—a win-win for both aesthetics and convenience.

Additionally, **lingual braces** provide an intriguing solution by placing brackets on the back side of your teeth—the tongue side—making them completely invisible from the front. This option is ideal for those who prioritize discretion above all else but comes with its own set of challenges: it requires specialized expertise for placement and adjustment and might initially cause more speech difficulty compared to other types due to its location.

Lastly, let's consider **timing and placement** as strategic elements in minimizing visibility. Orthodontists might opt for installing brackets on less conspicuous teeth first or choose specific times during treatment when appliances are less likely to draw attention—like positioning retainers or using temporary anchorage devices (TADs) strategically placed out of sight when possible.

In embracing these strategies—whether through clear aligners, ceramic braces, self-ligating systems, lingual options, or thoughtful treatment planning—it's clear that modern orthodontics offers pathways for patients to achieve straighter smiles without necessarily broadcasting their treatment journey visually. With these advancements, individuals can navigate their orthodontic paths with greater ease and confidence in how they present themselves during this transformative time.

When we delve into the realm of orthodontics, the goal often extends beyond merely aligning teeth to achieving an aesthetic outcome that harmonizes with the individual's natural appearance. The visibility of orthodontic appliances has long been a concern for

patients, influencing their comfort, self-esteem, and willingness to undergo treatment. Thus, the quest for techniques that minimize the visibility of these appliances has become a pivotal focus in modern orthodontic practice. This essay explores several strategies employed by orthodontists to ensure that the hardware used in correction is as discreet as possible, allowing individuals to undergo treatment with confidence and without undue attention to their dental fixtures.

One of the foremost advancements in this area is the development and widespread adoption of clear aligners, most notably brands like Invisalign. These virtually invisible trays are customized to fit snugly over the teeth, gradually shifting them into desired positions without the metal wires and brackets associated with traditional braces. Clear aligners not only reduce visibility but also offer a level of comfort since they are made from smooth plastic and do not irritate oral tissues as metal components might. Their removability further enhances discretion; patients can take them out for eating, drinking (except water), and cleaning, allowing for a greater sense of normalcy in daily life.

Another technique gaining traction is lingual braces, an option that places braces on the backside of teeth—effectively hiding them from view when smiling or speaking. This method requires specialized expertise due to its complexity in application and adjustment but offers a significant aesthetic advantage for those who prioritize invisibility. Lingual braces have advanced significantly with technological innovations, including customized brackets and wires tailored precisely to each patient's dental structure, thereby improving both effectiveness and comfort while maintaining their discreet positioning.

Moreover, advancements in bracket design have contributed immensely to minimizing visibility. Self-ligating brackets represent one such innovation; these brackets eliminate the need for elastic ties (often colored) that hold wires in place. By doing so, they reduce visual clutter around the teeth and offer a sleeker appearance compared to traditional

metal brackets. Additionally, tooth-colored or clear ceramic brackets have become popular substitutes for their metallic counterparts because they blend more seamlessly with tooth enamel. These options cater specifically to individuals seeking subtler orthodontic solutions without compromising on efficacy.

The realm of temporary anchorage devices (TADs) also plays a role in enhancing discretion within orthodontic treatments. While not exclusively aimed at reducing appliance visibility, certain types can be placed buccally (on the cheek side of teeth) or palatally (on the roof of the mouth), thus avoiding conspicuous front placements that might detract from aesthetics during treatment phases requiring extra anchorage support.

Finally, it's crucial to acknowledge that while these techniques significantly diminish visible hardware, patient education remains paramount. Understanding how these options work and what outcomes they entail empowers patients to make informed decisions aligned with their lifestyle needs and aesthetic preferences regarding orthodontic care. As technology continues evolving alongside growing demand for less intrusive treatments, we can expect further innovations aimed at making orthodontic care even more discreet and patient-friendly than ever before.

In conclusion, minimizing visible hardware in orthodontic treatments is not just about applying cutting-edge technologies but also understanding patient needs deeply—where functionality meets aesthetics seamlessly. Through clear aligners, lingual braces, innovative bracket designs, strategic

In recent years, the world of orthodontics has seen a remarkable evolution, particularly in the design and materials used for orthodontic appliances. The common goal? To make these essential tools for aligning teeth less conspicuous, enhancing both comfort and confidence for wearers. This shift towards minimizing visibility is driven not just by

aesthetic desires but also by a deeper understanding of how appearance can impact self-esteem, especially among teenagers and adults who might feel self-conscious about traditional metal braces.

The advancement in materials science has been pivotal in this transformation. Innovative materials like ceramic and clear polymers have taken center stage, offering a more discreet alternative to their metal counterparts. Ceramic braces, often referred to as "clear braces," are crafted from tooth-colored or transparent materials that blend seamlessly with the natural color of teeth. This subtle integration means that from a distance, it's often challenging to discern whether someone is undergoing orthodontic treatment at all—a significant leap from the shiny metal brackets of yesteryear.

Taking it a step further, advancements have led to the development of virtually invisible options such as lingual braces. These are placed on the back surface of the teeth, effectively hiding them from view when one smiles or talks. The precision required to apply these braces is higher than with traditional models, but for those seeking an almost invisible solution, they represent the pinnacle of discretion in orthodontic care.

Moreover, clear aligners like Invisalign have revolutionized the field with their virtually invisible design. These custom-made plastic trays fit snugly over the teeth and can be removed for eating and cleaning, offering not only a discreet treatment option but also greater convenience compared to fixed appliances. The material used is smooth and comfortable against the gums and cheeks, reducing irritation that can sometimes accompany metal wires and brackets.

Beyond aesthetics, these advanced materials are engineered for durability and effectiveness. They must withstand daily use—chewing, speaking—and adhere well to dental structures without compromising on strength or longevity. Research continues into

enhancing these properties while maintaining their inconspicuous nature, ensuring that patients can achieve their orthodontic goals without feeling defined by their appliance choice.

As society increasingly values individual expression and comfort alongside health considerations, the trend towards minimizing visibility in orthodontic appliances reflects broader shifts in personal aesthetics and psychological well-being. For many individuals contemplating orthodontic treatment, this evolution means they can pursue straighter teeth with renewed confidence—smiling openly without worrying about drawing attention to their dental work. It's a testament to how technological progress isn't just about what's new or efficient; it's equally about enhancing quality of life in ways that resonate deeply with personal values and societal norms around beauty and self-expression.

Maintaining oral hygiene without compromising aesthetics is a balancing act many orthodontic patients navigate daily, especially as they seek to minimize the visibility of their orthodontic appliances. This journey, while fraught with challenges, is fundamentally about integrating practical dental care routines with a desire for discreetness and confidence in one's smile.

Orthodontic appliances, whether traditional metal braces or the more modern clear aligners like Invisalign, serve a crucial role in correcting tooth alignment and improving bite function. However, their presence can sometimes feel like a constant reminder of one's orthodontic journey, potentially impacting self-esteem and social interactions. The quest to maintain oral hygiene while keeping these devices as unobtrusive as possible becomes paramount.

To start with, let's address the basics of oral hygiene that remain unchanged regardless of the type of orthodontic appliance: brushing and flossing are non-negotiable. For those with traditional braces, a soft-bristled toothbrush and fluoride toothpaste are essential

tools. The technique here involves brushing gently around each bracket and wire to dislodge food particles and plaque that could lead to decay or gum disease. For individuals using clear aligners, the process is slightly different yet equally important; aligners should be removed for at least 12 hours daily, including during meals when thorough brushing becomes feasible without the hindrance of fixed appliances.

The aesthetics aspect comes into play primarily with visibility. Clear aligners have revolutionized this area by offering virtually invisible treatment options—aligners made from transparent plastic that fit over the teeth seamlessly. Yet even these subtle devices require meticulous care; they must be cleaned regularly to avoid staining and maintain their clarity, alongside rigorous oral hygiene practices to ensure no residual plaque remains hidden where it could harm teeth and gums.

For those who might find the physical presence of braces more noticeable, there are additional strategies to consider: tongue guards can help reduce irritation inside the mouth while also helping maintain an immaculate appearance by discouraging harmful habits like tongue thrusting which can affect alignment progress indirectly. Moreover, choosing foods wisely can make a significant difference; avoiding hard or sticky items not only protects the appliances but also keeps teeth cleaner between brushings, contributing subtly to overall aesthetics.

In essence, minimizing the visibility of orthodontic appliances while maintaining stellar oral hygiene boils down to commitment—commitment to daily cleaning routines tailored to individual needs, careful selection of dental products suited for orthodontic wearers, and perhaps even embracing certain lifestyle adjustments that support both health and appearance goals. It's about finding that sweet spot where functionality meets discretion—a place where one can confidently smile knowing both their teeth are on track for improvement and their aesthetics remain unmarred by their orthodontic journey. Balancing these aspects requires patience and diligence but ultimately paves the way for

not just a healthy smile but also a radiant confidence throughout the entirety of one's treatment experience.

Keeping orthodontic appliances clean while ensuring they blend seamlessly with your natural smile is a balancing act that many wearers navigate with grace and diligence. Orthodontic treatments, whether through traditional braces, clear aligners, or other appliances, are pivotal in achieving that perfect smile we all dream of. However, the journey doesn't just end with the mechanics of straightening teeth; it extends into the maintenance realm, where both functionality and aesthetics meet. Here are some human-centric tips to keep your orthodontic appliances clean without sacrificing that natural look you've worked so hard to maintain.

Embracing the Essentials of Cleanliness:

First and foremost, understanding that cleanliness is paramount cannot be overstated. Whether you're sporting metal braces or the nearly invisible Invisalign aligners, bacteria and food particles can easily accumulate in the tiny crevices and surfaces these appliances present. Regular brushing and flossing become not just routines but rituals that ensure your oral health remains pristine and your appliances free from stains and plaque buildup. A soft-bristled toothbrush dedicated to your oral appliance can gently scrub away without risking damage to your teeth or brackets. For those with aligners, removing them for thorough brushing and flossing after every meal is a must—a small investment of time that pays dividends in both oral health and aesthetic appeal.

The Art of Flossing:

Flossing might seem like a mundane task, but when it comes to orthodontic care, it's an art form. Traditional floss can be challenging to maneuver around wires and brackets;

hence, investing in specialized orthodontic floss or a water flosser can make this task less daunting while maintaining discretion. These tools allow for effective cleaning without the bulkiness often associated with traditional floss, ensuring you tackle those hard-to-reach areas effectively without drawing unnecessary attention to your appliance.

Choosing Colors Wisely:

For those who opt for colorful brackets or aligners as a way to express their personality during treatment, there's an added layer of consideration: choosing colors that complement your natural teeth tone can help minimize visibility. Clear or tooth-colored options often blend better than brighter hues, allowing you to showcase your unique style while keeping the focus on your naturally radiant smile rather than the hardware holding it together.

Regular Professional Check-ups:

No matter how diligent you are with at-home care, regular check-ups with your orthodontist are essential. These visits aren't just about tweaking wires or adjusting fit; they provide an opportunity for a thorough cleaning by professionals who can reach areas you might miss. Your orthodontist will also offer personalized advice tailored to your specific appliance type and oral health needs—another reason why these appointments are invaluable throughout your treatment journey.

Mindful Eating Habits:

Lastly, being mindful of what you consume plays a crucial role in keeping appliances clean and looking natural. Avoiding sticky, stain-causing foods like candy or dark sodas isn't just about preserving the appearance of braces or aligners—it's also about safeguarding your teeth from unnecessary damage during treatment. Opt for foods that are easy on both appliances and enamel; fresh fruits and vegetables (cut into manageable pieces), lean proteins, are not only nutritious but also kinder to both your orthodontic hardware and natural smile goals.

In sum, maintaining the cleanliness of orthodontic

The significance of oral hygiene in the realm of orthodontic treatment extends far beyond mere dental health; it's a pivotal factor that intertwines with the effectiveness of treatment and the aesthetic outcome, particularly when it comes to minimizing the visibility of orthodontic appliances. Let's delve into why maintaining impeccable oral hygiene is not just a recommendation but a cornerstone for those embarking on the journey to a straighter smile.

Firstly, let's consider the fundamental purpose of orthodontic appliances—braces, aligners, and other such devices are meticulously designed to correct tooth positioning and improve bite alignment. However, their efficacy hinges greatly on the condition of the teeth and gums they're working on. When plaque and food particles linger around braces or aligners, they create an environment ripe for decay and gum disease. This not only jeopardizes the health of your teeth but can also delay treatment progress. For instance, if gum disease progresses unchecked, it can lead to inflammation and bone loss, complicating the orthodontist's ability to achieve desired results efficiently. Hence, regular brushing, flossing, and professional cleanings become indispensable allies in ensuring that your teeth remain healthy throughout the treatment period.

Moreover, let's not overlook the aesthetic aspect—a crucial consideration for many undergoing orthodontic treatment. Visible food debris or unsightly plaque accumulation around braces or aligners can detract from the overall appearance one hopes to achieve with straightened teeth. In an era where aesthetics play a significant role in personal presentation, maintaining a clean mouth becomes as much about feeling confident as it is about oral health. Clear aligners have made strides in minimizing visibility compared to traditional metal braces; however, their effectiveness can be undermined by poor oral hygiene practices. A well-maintained mouth not only supports the functional goals of orthodontics but also enhances the cosmetic outcome by ensuring that aligners remain transparent and unmarred by stains or deposits.

Additionally, proper oral hygiene fosters better breath and comfort during treatment. Nobody wants to struggle with bad breath or irritation caused by neglected oral care while already adapting to the physical presence of orthodontic appliances in their mouths. Regular cleaning helps maintain fresh breath and reduces discomfort from irritated gums or sores that could arise from poor maintenance around brackets or wires.

In essence, taking care of one's oral hygiene during orthodontic treatment isn't merely about preventing cavities or gum disease—it's about maximizing treatment success while achieving an appealing result that one can proudly showcase post-treatment. By diligently practicing good oral hygiene habits—brushing thoroughly around appliances, using floss threaders or interdental brushes regularly, scheduling routine dental check-ups—patients set themselves up for a smoother journey toward their goal: not just healthier teeth but a confident smile that radiates care and attention at every glance. As we navigate this path towards straighter teeth and improved bites, let us remember that our commitment to cleanliness is as vital as our commitment to wearing those braces or aligners with pride.

When we think about orthodontic treatments, the immediate focus often falls on the journey to achieving that perfect smile—straightening teeth, correcting bites, and enhancing overall dental health. However, an equally important aspect of orthodontic care

that deserves attention is the long-term considerations and follow-up care, especially concerning minimizing the visibility of orthodontic appliances. This part of treatment isn't just about achieving a desirable aesthetic during the active phase of braces or aligners; it's also about ensuring comfort, maintaining oral hygiene, and preserving the results over time.

The quest to minimize the visibility of orthodontic appliances has evolved significantly with advancements in technology and materials. Traditional metal braces, once the standard, are now joined by more discreet options like ceramic braces and clear aligners such as Invisalign. These alternatives aim not only to straighten teeth effectively but also to blend into one's natural smile as much as possible. Ceramic braces use tooth-colored brackets that are less noticeable than their metal counterparts, while clear aligners offer a virtually invisible way to move teeth, making them a favorite among adults and teens concerned about their appearance during treatment.

However, beyond aesthetics lies a practical consideration: comfort and oral hygiene. Visibility isn't just about how much others can see; it's also about how easily one can maintain their oral hygiene without interference from bulky or prominent fixtures in their mouth. For instance, clear aligners can be removed for eating and brushing, which not only makes daily oral care easier but also reduces food trapping areas that could lead to plaque buildup—a concern with traditional braces where certain areas might be harder to clean due to their design.

Long-term considerations extend into post-treatment phases as well. After removing braces or completing an aligner therapy, retainers become essential to maintain the newly achieved alignment. These devices are often custom-made to fit comfortably in your mouth without drawing undue attention, ensuring that the hard work done during active treatment isn't undone over time due to natural tooth movement or growth changes. The choice between fixed (permanent) retainers bonded behind the teeth and removable

ones offers flexibility based on individual needs and preferences regarding visibility and convenience.

Moreover, following through with regular dental check-ups becomes crucial post-treatment not just for monitoring overall dental health but also for ensuring that any adjustments needed for retainers or addressing any unforeseen shifts in tooth alignment are handled promptly. Dentists play a pivotal role here by guiding patients through this maintenance phase with tailored advice on caring for their smiles long after active orthodontic treatment has concluded.

In essence, minimizing the visibility of orthodontic appliances is not merely a matter of personal preference but encompasses broader implications for comfort, functionality during treatment, ease of maintenance afterward, and long-term retention of results. As we continue striding forward in orthodontics with innovative solutions aimed at improving both aesthetics and patient experience, it's heartening to see how these developments contribute significantly towards making orthodontic treatments more inclusive—catering not just to those seeking transformation but also those who value discretion alongside dental health improvements. The journey toward a confident smile remains holistic when considering every detail—including how unobtrusive our path towards it can be.

Transitioning from active orthodontic treatment to the more discreet realm of retainers is a significant milestone in one's journey towards a straighter smile and improved oral health. This phase, often less dramatic than the initial brace-wearing period, holds its own subtleties and considerations, especially when it comes to minimizing visibility—a key concern for many who have invested time and effort into their orthodontic journey.

Active treatment with braces, whether traditional metal ones or the more contemporary clear aligners, often commands attention. The metallic brackets and wires or the nearly invisible but still noticeable aligner trays can be a focal point, sometimes leading to self-

consciousness among wearers. However, as treatment progresses towards its conclusion, the focus shifts from correction to conservation—preserving that hard-earned alignment while keeping the spotlight as low as possible.

Enter retainers: the unsung heroes of orthodontic maintenance. These devices come in various forms—fixed (permanent) or removable—and are designed with both functionality and discretion in mind. For those aiming to minimize visibility post-treatment, removable retainers often present an attractive option. Crafted from transparent materials like thermoplastic or thin wires that blend with the natural tones of the mouth, these retainers can be nearly imperceptible when worn. Their design allows for easy removal during meals and cleaning, offering convenience without sacrificing aesthetics—a crucial factor for individuals concerned about how their orthodontic appliances reflect on their appearance in social or professional settings.

However, it's important to understand that even these discreet retainers require diligent use to maintain the results achieved during active treatment. Wearing them as prescribed—often nightly—is essential not just for preserving alignment but also for ensuring that any subtle shifts in tooth position are corrected before they become more pronounced issues. This commitment might seem like an afterthought compared to the bustle of active treatment, but it's a critical step that ensures longevity of results without needing further interventions down the line.

Moreover, embracing this transition involves educating oneself about retainer care—how to clean them properly to prevent staining or bacterial buildup and how to store them safely when not in use—to ensure they remain effective and visually unobtrusive over time. It's a small investment of daily attention that pays off significantly in maintaining confidence and oral health long after braces have been removed.

In essence, moving from active orthodontic treatment to retainers is not merely a shift in appliances but a thoughtful continuation of one's commitment to personal improvement and aesthetic preferences. By choosing discreet options like transparent removable retainers and adhering to recommended care practices, individuals can enjoy their newly aligned smiles without compromise on privacy or style—embodying a seamless blend of functionality and subtlety in their journey towards lasting oral beauty.

Keeping Aesthetic Considerations in Mind: The Art of Post-Treatment Care for Orthodontic Appliances

In today's world, where a smile can light up a room and first impressions matter more than ever, the journey through orthodontic treatment isn't just about achieving straight teeth; it's equally about maintaining that radiant smile with minimal visibility of the appliances used to get there. As we wrap up our orthodontic journeys, whether with braces, clear aligners, or other appliances, the focus shifts towards post-treatment care that ensures our hard-earned results last without drawing unwanted attention to the mechanics that made it possible. This delicate balance between functionality and aesthetics in post-treatment care is crucial for those aiming to enjoy lasting results without relapse into visibility concerns.

Firstly, understanding that aesthetics play a pivotal role in our self-perception and confidence is key. Orthodontic treatments are not merely corrective but also transformative, aiming to enhance one's smile and overall facial aesthetics. Thus, during the post-treatment phase, maintaining this aesthetic integrity is paramount. This involves careful consideration of how we handle and wear any residual appliances like retainers or night guards that might be necessary to preserve the new alignment of our teeth. Choosing retainers that are discreet—perhaps opting for clear aligner retainers instead of metal wire ones—can significantly contribute to keeping the aesthetic appeal of our smiles intact.

Moreover, daily oral hygiene practices take on an even greater importance post-treatment. Not only do they maintain oral health but also ensure that any remaining appliances remain clean and less noticeable. Using toothpastes and mouthwashes that do not discolor or affect the appearance of clear aligners or other aesthetic appliances is wise. Regular dental check-ups become essential not just for professional cleanings but also for timely adjustments or replacements of any worn-out components of our orthodontic setup, ensuring they continue to serve their purpose without compromising on looks.

Additionally, lifestyle choices play a significant role in this intricate dance between function and form. Avoiding habits such as biting nails or using teeth as tools can prevent unnecessary wear on retainers or aligners while keeping your smile looking pristine. Moreover, being mindful when choosing foods can protect both your teeth and any visible orthodontic components from stains or damage, thus preserving both function and aesthetic appeal over time.

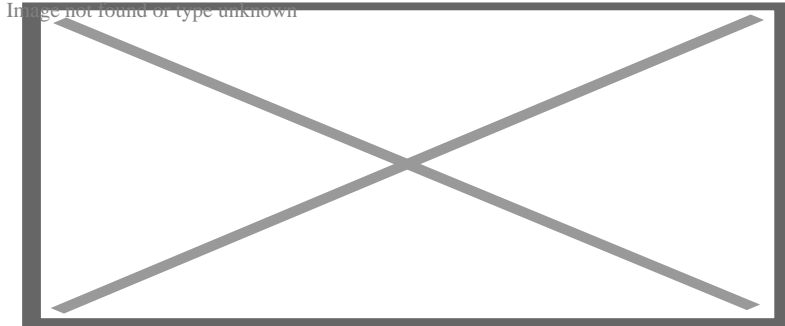
In essence, the journey doesn't end with the removal of braces or the final adjustment of aligners; rather, it transforms into a commitment to maintenance that respects both the science behind orthodontics and our personal desire for an enduringly beautiful smile. By thoughtfully integrating aesthetic considerations into post-treatment care routines—from selecting appropriate retainers to practicing diligent oral hygiene—we ensure that our transformation stands the test of time gracefully. It's about embracing an ongoing process where every conscious choice contributes to a lasting result: a confident smile unmarred by visibility concerns—a true testament to how thoughtful care extends beyond mere treatment into a lifestyle choice celebrating beauty and health harmoniously intertwined.

About dental braces

This article **needs additional citations for verification**. Please help improve this article by adding citations to reliable sources. Unsourced material may be challenged and removed.



Find sources: "Dental braces" – news · newspapers · books · scholar · JSTOR (August 2016) *(Learn how and when to remove this message)*



Dental braces

Dental braces (also known as **orthodontic braces**, or simply **braces**) are devices used in orthodontics that align and straighten teeth and help position them with regard to a person's bite, while also aiming to improve dental health. They are often used to correct underbites, as well as malocclusions, overbites, open bites, gaps, deep bites, cross bites, crooked teeth, and various other flaws of the teeth and jaw. Braces can be either cosmetic or structural. Dental braces are often used in conjunction with other orthodontic appliances to help widen the palate or jaws and to otherwise assist in shaping the teeth and jaws.

Process


[edit]

The application of braces moves the teeth as a result of force and pressure on the teeth. Traditionally, four basic elements are used: brackets, bonding material, arch wire, and ligature elastic (also called an "O-ring"). The teeth move when the arch wire puts pressure on the brackets and teeth. Sometimes springs or rubber bands are used to put more force in a specific direction.^[1]


Braces apply constant pressure which, over time, moves teeth into the desired positions. The process loosens the tooth after which new bone grows to support the tooth in its new position. This is called bone remodelling. Bone remodelling is a biomechanical process responsible for making bones stronger in response to sustained load-bearing activity and weaker in the absence of carrying a load. Bones are made of cells called osteoclasts and osteoblasts. Two different kinds of bone resorption are possible: direct resorption, which starts from the lining cells of the alveolar bone, and indirect or retrograde resorption, which occurs when the periodontal ligament has been subjected to an excessive amount and duration of compressive stress.^[2] Another important factor associated with tooth movement is bone deposition. Bone deposition occurs in the distracted periodontal ligament. Without bone deposition, the tooth will loosen, and voids will occur distal to the direction of tooth movement.^[3]

Types

[edit]



"Clear" braces




Upper and Lower Jaw Functional Expanders

- **Traditional metal wired braces** (also known as "train track braces") are stainless-steel and are sometimes used in combination with titanium. Traditional metal braces are the most common type of braces.^[4] These braces have a metal bracket with elastic ties (also known as rubber bands) holding the wire onto the metal brackets. The second-most common type of braces is self-ligating braces, which have a built-in system to secure the archwire to the brackets and do not require elastic ties. Instead, the wire goes through the bracket. Often with this type of braces, treatment time is reduced, there is less pain on the teeth, and fewer adjustments are required than with traditional braces.
- **Gold-plated stainless steel** braces are often employed for patients allergic to nickel (a basic and important component of stainless steel), but may also be chosen for aesthetic reasons.
- **Lingual braces** are a cosmetic alternative in which custom-made braces are bonded to the back of the teeth making them externally invisible.
- **Titanium braces** resemble stainless-steel braces but are lighter and just as strong. People with allergies to nickel in steel often choose titanium braces, but they are more expensive than stainless steel braces.
- **Customized orthodontic treatment systems** combine high technology including 3-D imaging, treatment planning software and a robot to custom bend the wire. Customized systems such as this offer faster treatment times and more efficient results.^[5]
- **Progressive, clear removable aligners** may be used to gradually move teeth into their final positions. Aligners are generally not used for complex orthodontic cases, such as when extractions, jaw surgery, or palate expansion are necessary.^{[medical [6]}

Fitting procedure

[edit]



A patient's teeth are prepared for the application of braces.


Orthodontic services may be provided by any licensed dentist trained in orthodontics. In North America, most orthodontic treatment is done by orthodontists, who are dentists in the diagnosis and treatment of *malocclusions*—malalignments of the teeth, jaws, or both. A dentist must complete 2–3 years of additional post-doctoral training to earn a specialty certificate in orthodontics. There are many general practitioners who also provide orthodontic services.

The first step is to determine whether braces are suitable for the patient. The doctor consults with the patient and inspects the teeth visually. If braces are appropriate, a records appointment is set up where X-rays, moulds, and impressions are made. These records are analyzed to determine the problems and the proper course of action. The use of digital models is rapidly increasing in the orthodontic industry. Digital treatment starts with the creation of a three-dimensional digital model of the patient's arches. This model is produced by laser-scanning plaster models created using dental impressions. Computer-automated treatment simulation has the ability to automatically separate the gums and teeth from one another and can handle malocclusions well; this software enables clinicians to ensure, in a virtual setting, that the selected treatment will produce the optimal outcome, with minimal user input.¹*medical cita*

Typical treatment times vary from six months to two and a half years depending on the complexity and types of problems. Orthognathic surgery may be required in extreme cases. About 2 weeks before the braces are applied, orthodontic spacers may be required to spread apart back teeth in order to create enough space for the bands.

Teeth to be braced will have an adhesive applied to help the cement bond to the surface of the tooth. In most cases, the teeth will be banded and then brackets will be added. A bracket will be applied with dental cement, and then cured with light until hardened. This process usually takes a few seconds per tooth. If required, orthodontic spacers may be inserted between the molars to make room for molar bands to be placed at a later date. Molar bands are required to ensure brackets will stick. Bands are also utilized when dental fillings or other dental works make securing a bracket to a tooth infeasible. Orthodontic tubes (stainless steel tubes that allow wires to pass through them), also known as molar tubes, are directly bonded to molar teeth either by a chemical curing or a light curing adhesive. Usually, molar tubes are directly welded to bands, which is a metal ring that fits onto the molar tooth. Directly bonded molar tubes are associated with a higher failure rate when compared to molar bands cemented with glass ionomer cement. Failure of orthodontic brackets, bonded tubes or bands will increase the overall treatment time for the patient. There is evidence suggesting that there is less enamel decalcification associated with molar bands cemented with glass ionomer cement compared with orthodontic tubes directly cemented to molars using a light cured adhesive. Further evidence is needed to withdraw a more robust conclusion due to limited data.^[7]

An archwire will be threaded between the brackets and affixed with elastic or metal ligatures. Ligatures are available in a wide variety of colours, and the patient can choose which colour they like. Arch wires are bent, shaped, and tightened frequently to achieve the desired results.



Dental braces, with a transparent power chain, removed after completion of treatment.

Modern orthodontics makes frequent use of nickel–titanium archwires and temperature–sensitive materials. When cold, the archwire is limp and flexible, easily threaded between brackets of any configuration. Once heated to body temperature, the arch wire will stiffen and seek to retain its shape, creating constant light force on the teeth.


Brackets with hooks can be placed, or hooks can be created and affixed to the arch wire to affix rubber bands. The placement and configuration of the rubber bands will depend on the course of treatment and the individual patient. Rubber bands are made in different diameters, colours, sizes, and strengths. They are also typically available in two versions: Coloured or clear/opaque.

The fitting process can vary between different types of braces, though there are similarities such as the initial steps of moulding the teeth before application. For example, with clear braces, impressions of a patient's teeth are evaluated to create a series of trays, which fit to the patient's mouth almost like a protective mouthpiece. With some forms of braces, the brackets are placed in a special form that is customized to the patient's mouth, drastically reducing the application time.

In many cases, there is insufficient space in the mouth for all the teeth to fit properly. There are two main procedures to make room in these cases. One is extraction: teeth are removed to create more space. The second is expansion, in which the palate or arch is made larger by using a palatal expander. Expanders can be used with both children and adults. Since the bones of adults are already fused, expanding the palate is not possible without surgery to separate them. An expander can be used on an adult without surgery but would be used to expand the dental arch, and not the palate.

Sometimes children and teenage patients, and occasionally adults, are required to wear a headgear appliance as part of the primary treatment phase to keep certain teeth from moving (for more detail on headgear and facemask appliances see Orthodontic headgear). When braces put pressure on one's teeth, the periodontal membrane stretches on one side and is compressed on the other. This movement needs to be done slowly or otherwise, the patient risks losing their teeth. This is why

braces are worn as long as they are and adjustments are only made every so often.



Young Colombian man during an adjustment visit for his orthodontics

Braces are typically adjusted every three to six weeks. This helps shift the teeth into the correct position. When they get adjusted, the orthodontist removes the coloured or metal ligatures keeping the arch wire in place. The arch wire is then removed and may be replaced or modified. When the archwire has been placed back into the mouth, the patient may choose a colour for the new elastic ligatures, which are then affixed to the metal brackets. The adjusting process may cause some discomfort to the patient, which is normal.

Post-treatment

[edit]


Patients may need post-orthodontic surgery, such as a fiberotomy or alternatively a gum lift, to prepare their teeth for retainer use and improve the gumline contours after the braces come off. After braces treatment, patients can use a transparent plate to keep the teeth in alignment for a certain period of time. After treatment, patients usually use transparent plates for 6 months. In patients with long and difficult treatment, a fixative wire is attached to the back of the teeth to prevent the teeth from

returning to their original state.[⁸]

Retainers

[edit]

Main article: Retainer (orthodontic device)



Hawley retainers are the most common type of retainers. This picture shows retainers for the top (right) and bottom (left) of the mouth.

In order to prevent the teeth from moving back to their original position, retainers are worn once the treatment is complete. Retainers help in maintaining and stabilizing the position of teeth long enough to permit the reorganization of the supporting structures after the active phase of orthodontic therapy. If the patient does not wear the retainer appropriately and/or for the right amount of time, the teeth may move towards their previous position. For regular braces, Hawley retainers are used. They are made of metal hooks that surround the teeth and are enclosed by an acrylic plate shaped to fit the patient's palate. For Clear Removable braces, an Essix retainer is used. This is similar to the original aligner; it is a clear plastic tray that is firmly fitted to the teeth and stays in place without a plate fitted to the palate. There is also a bonded retainer where a wire is permanently bonded to the lingual side of the teeth, usually the lower teeth only.


Headgear

[edit]

Main article: Orthodontic headgear

Headgear needs to be worn between 12 and 22 hours each day to be effective in correcting the overbite, typically for 12 to 18 months depending on the severity of the overbite, how much it is worn and what growth stage the patient is in. Typically the prescribed daily wear time will be between 14 and 16 hours a day and is frequently used as a post-primary treatment phase to maintain the position of the jaw and arch. Headgear can be used during the night while the patient sleeps.^[9] *[better source needed]*

Orthodontic headgear usually consists of three major components:



Full orthodontic headgear with head cap, fitting straps, facebow and elastics

1. Facebow: the facebow (or J-Hooks) is fitted with a metal arch onto headgear tubes attached to the rear upper and lower molars. This facebow then extends out of the mouth and around the patient's face. J-Hooks are different in that they hook into the patient's mouth and attach directly to the brace (see photo for an example of J-Hooks).
2. Head cap: the head cap typically consists of one or a number of straps fitting around the patient's head. This is attached with elastic bands or springs to the facebow. Additional straps and attachments are used to ensure comfort and safety (see photo).
3. Attachment: typically consisting of rubber bands, elastics, or springs—joins the facebow or J-Hooks and the head cap together, providing the force to move the

upper teeth, jaw backwards.

The headgear application is one of the most useful appliances available to the orthodontist when looking to correct a Class II malocclusion. See more details in the section Orthodontic headgear.

Pre-finisher

[edit]

The pre-finisher is moulded to the patient's teeth by use of extreme pressure on the appliance by the person's jaw. The product is then worn a certain amount of time with the user applying force to the appliance in their mouth for 10 to 15 seconds at a time. The goal of the process is to increase the exercise time in applying the force to the appliance. If a person's teeth are not ready for a proper retainer the orthodontist may prescribe the use of a preformed finishing appliance such as the pre-finisher. This appliance fixes gaps between the teeth, small spaces between the upper and lower jaw, and other minor problems.

Complications and risks

[edit]

A group of dental researchers, Fatma Boke, Cagri Gazioglu, Selvi Akkaya, and Murat Akkaya, conducted a study titled "Relationship between orthodontic treatment and gingival health." The results indicated that some orthodontist treatments result in gingivitis, also known as gum disease. The researchers concluded that functional appliances used to harness natural forces (such as improving the alignment of bites) do not usually have major effects on the gum after treatment.^[10] However, fixed appliances such as braces, which most people get, can result in visible plaque, visible inflammation, and gum recession in a majority of the patients. The formation of plaques around the teeth of patients with braces is almost inevitable regardless of plaque control and can result in mild gingivitis. But if someone with braces does not clean

their teeth carefully, plaques will form, leading to more severe gingivitis and gum recession.

Experiencing some pain following fitting and activation of fixed orthodontic braces is very common and several methods have been suggested to tackle this^{[11][12]} Pain associated with orthodontic treatment increases in proportion to the amount of force that is applied to the teeth. When a force is applied to a tooth via a brace, there is a reduction in the blood supply to the fibres that attach the tooth to the surrounding bone. This reduction in blood supply results in inflammation and the release of several chemical factors, which stimulate the pain response. Orthodontic pain can be managed using pharmacological interventions, which involve the use of analgesics applied locally or systemically. These analgesics are divided into four main categories, including opioids, non-steroidal anti-inflammatory drugs (NSAIDs), paracetamol and local anesthesia. The first three of these analgesics are commonly taken systemically to reduce orthodontic pain.^[13]

A Cochrane Review in 2017 evaluated the pharmacological interventions for pain relief during orthodontic treatment. The study concluded that there was moderate-quality evidence that analgesics reduce the pain associated with orthodontic treatment. However, due to a lack of evidence, it was unclear whether systemic NSAIDs were more effective than paracetamol, and whether topical NSAIDs were more effective than local anaesthesia in the reduction of pain associated with orthodontic treatment. More high-quality research is required to investigate these particular comparisons.^[13]


The dental displacement obtained with the orthodontic appliance determines in most cases some degree of root resorption. Only in a few cases is this side effect large enough to be considered real clinical damage to the tooth. In rare cases, the teeth may fall out or have to be extracted due to root resorption.^{[14][15]}

History

[edit]

Ancient

[edit]




Old Braces at a museum in Jbeil, Lebanon

According to scholars and historians, braces date back to ancient times. Around 400–300 BC, Hippocrates and Aristotle contemplated ways to straighten teeth and fix various dental conditions. Archaeologists have discovered numerous mummified ancient individuals with what appear to be metal bands wrapped around their teeth. Catgut, a type of cord made from the natural fibres of an animal's intestines, performed a similar role to today's orthodontic wire in closing gaps in the teeth and mouth.^[16]

The Etruscans buried their dead with dental appliances in place to maintain space and prevent the collapse of the teeth during the afterlife. A Roman tomb was found with a number of teeth bound with gold wire documented as a ligature wire, a small elastic wire that is used to affix the arch wire to the bracket. Even Cleopatra wore a pair. Roman philosopher and physician Aulus Cornelius Celsus first recorded the treatment of teeth by finger pressure. Unfortunately, due to a lack of evidence, poor preservation of bodies, and primitive technology, little research was carried out on dental braces until around the 17th century, although dentistry was making great advancements as a profession by then.^[citation needed]

18th century

[edit]



Portrait of Fauchard from his 1728 edition of *"The Surgical Dentist"*.

Orthodontics truly began developing in the 18th and 19th centuries. In 1669, French dentist Pierre Fauchard, who is often credited with inventing modern orthodontics, published a book entitled *"The Surgeon Dentist"* on methods of straightening teeth. Fauchard, in his practice, used a device called a "Bandeau", a horseshoe-shaped piece of iron that helped expand the palate. In 1754, another French dentist, Louis Bourdet, dentist to the King of France, followed Fauchard's book with *The Dentist's Art*, which also dedicated a chapter to tooth alignment and application. He perfected the "Bandeau" and was the first dentist on record to recommend extraction of the premolar teeth to alleviate crowding and improve jaw growth.

19th century

[edit]

Although teeth and palate straightening and/or pulling were used to improve the alignment of remaining teeth and had been practised since early times, orthodontics, as a science of its own, did not really exist until the mid-19th century. Several important dentists helped to advance dental braces with specific instruments and tools that allowed braces to be improved.

In 1819, Christophe François Delabarre introduced the wire crib, which marked the birth of contemporary orthodontics, and gum elastics were first employed by Maynard in 1843. Tucker was the first to cut rubber bands from rubber tubing in 1850. Dentist, writer, artist, and sculptor Norman William Kingsley in 1858 wrote the first article on orthodontics and in 1880, his book, *Treatise on Oral Deformities*, was published. A dentist named John Nutting Farrar is credited for writing two volumes entitled, *A Treatise on the Irregularities of the Teeth and Their Corrections* and was the first to suggest the use of mild force at timed intervals to move teeth.

20th century

[edit]


In the early 20th century, Edward Angle devised the first simple classification system for malocclusions, such as Class I, Class II, and so on. His classification system is still used today as a way for dentists to describe how crooked teeth are, what way teeth are pointing, and how teeth fit together. Angle contributed greatly to the design of orthodontic and dental appliances, making many simplifications. He founded the first school and college of orthodontics, organized the American Society of Orthodontia in 1901 which became the American Association of Orthodontists (AAO) in the 1930s, and founded the first orthodontic journal in 1907. Other innovations in orthodontics in the late 19th and early 20th centuries included the first textbook on orthodontics for children, published by J.J. Guilford in 1889, and the use of rubber elastics, pioneered by Calvin S. Case, along with Henry Albert Baker.

Today, space age wires (also known as dental arch wires) are used to tighten braces. In 1959, the Naval Ordnance Laboratory created an alloy of nickel and titanium called Nitinol. NASA further studied the material's physical properties^[17] In 1979, Dr. George Andreasen developed a new method of fixing braces with the use of the Nitinol wires based on their superelasticity. Andreasen used the wire on some patients and later found out that he could use it for the entire treatment. Andreasen then began using the nitinol wires for all his treatments and as a result, dental doctor visits were reduced, the cost of dental treatment was reduced, and patients reported less

discomfort.

See also

[edit]

- o  [Medicine portal](#) Image from column of type unknown
- o Mandibular advancement splint
- o Oral and maxillofacial surgery
- o Orthognathic surgery
- o Prosthodontics
- o Trismus
- o Dental implant

References

[edit]

1. ^ *"Dental Braces and Retainers"*. *WebMD*. Retrieved 2020-10-30.
2. ^ *Robling, Alexander G.; Castillo, Alesha B.; Turner, Charles H. (2006). "Biomechanical and Molecular Regulation of Bone Remodeling". *Annual Review of Biomedical Engineering*. **8**: 455–498. doi:10.1146/annurev.bioeng.8.061505.095721. PMID 16834564.*
3. ^ *Toledo SR, Oliveira ID, Okamoto OK, Zago MA, de Seixas Alves MT, Filho RJ, et al. (September 2010). "Bone deposition, bone resorption, and osteosarcoma". *Journal of Orthopaedic Research*. **28** (9): 1142–1148. doi:10.1002/jor.21120. PMID 20225287. S2CID 22660771.*
4. ^ *"Metal Braces for Teeth: Braces Types, Treatment, Cost in India"*. *Clove Dental*. Retrieved 2025-02-06.
5. ^ *Saxe, Alana K.; Louie, Lenore J.; Mah, James (2010). "Efficiency and effectiveness of SureSmile". *World Journal of Orthodontics*. **11** (1): 16–22. PMID 20209172.*
6. ^ *Tamer, Ąfâ€žĄ°pek (December 2019). "Orthodontic Treatment with Clear Aligners and The Scientific Reality Behind Their Marketing: A Literature Review". *Turkish Journal of Orthodontics*. **32** (4): 241–246. doi:10.5152/TurkJOrthod.2019.18083. PMC 7018497. PMID 32110470.*
7. ^ *Millett DT, Mandall NA, Mattick RC, Hickman J, Glenny AM (February 2017). "Adhesives for bonded molar tubes during fixed brace treatment". *The Cochrane Database of Systematic Reviews*. **2** (3): CD008236. doi:10.1002/14651858.cd008236.pub3. PMC 6464028. PMID 28230910.*

8. ^ Rubie J Patrick (2017). "What About Teeth After Braces?" 2017 – "Health Journal Article" Toothcost Archived 2021-10-18 at the Wayback Machine
9. ^ Naten, Joshua. "Braces Headgear (Treatments)". toothcost.com. Archived from the original on 19 October 2021.
10. ^ Boke, Fatma; Gazioglu, Cagri; Akkaya, Sevil; Akkaya, Murat (2014). "Relationship between orthodontic treatment and gingival health: A retrospective study". *European Journal of Dentistry*. **8** (3): 373–380. doi:10.4103/1305-7456.137651. ISSN 1305-7456. PMC 4144137. PMID 25202219.
11. ^ Eslamian L, Borzabadi-Farahani A, Hassanzadeh-Azhiri A, Badiie MR, Fekrazad R (March 2014). "The effect of 810-nm low-level laser therapy on pain caused by orthodontic elastomeric separators". *Lasers in Medical Science*. **29** (2): 559–64. doi:10.1007/s10103-012-1258-1. PMID 23334785. S2CID 25416518.
12. ^ Eslamian L, Borzabadi-Farahani A, Edini HZ, Badiie MR, Lynch E, Mortazavi A (September 2013). "The analgesic effect of benzocaine mucoadhesive patches on orthodontic pain caused by elastomeric separators, a preliminary study". *Acta Odontologica Scandinavica*. **71** (5): 1168–73. doi:10.3109/00016357.2012.757358. PMID 23301559. S2CID 22561192.
13. ^ **a b** Monk AB, Harrison JE, Worthington HV, Teague A (November 2017). "Pharmacological interventions for pain relief during orthodontic treatment". *The Cochrane Database of Systematic Reviews*. **11** (12): CD003976. doi:10.1002/14651858.cd003976.pub2. PMC 6486038. PMID 29182798.
14. ^ Artun J, Smale I, Behbehani F, Doppel D, Van't Hof M, Kuijpers-Jagtman AM (November 2005). "Apical root resorption six and 12 months after initiation of fixed orthodontic appliance therapy". *The Angle Orthodontist*. **75** (6): 919–26. PMID 16448232.
15. ^ Mavragani M, Vergari A, Selliseth NJ, Bøe OE, Wisth PL (December 2000). "A radiographic comparison of apical root resorption after orthodontic treatment with a standard edgewise and a straight-wire edgewise technique". *European Journal of Orthodontics*. **22** (6): 665–74. doi:10.1093/ejo/22.6.665. PMID 11212602.
16. ^ Wahl N (February 2005). "Orthodontics in 3 millennia. Chapter 1: Antiquity to the mid-19th century". *American Journal of Orthodontics and Dentofacial Orthopedics*. **127** (2): 255–9. doi:10.1016/j.ajodo.2004.11.013. PMID 15750547.
17. ^ "NASA Technical Reports Server (NTRS)". Spinoff 1979. February 1979. Retrieved 2021-03-02.

External links

[edit]

- Useful Resources: FAQ and Downloadable eBooks at Orthodontics Australia
- Orthos Explain: Treatment Options at Orthodontics Australia

- o  Media related to Dental braces at Wikimedia Commons

- o v
- o t
- o e

Orthodontics

- o Bolton analysis
- o Cephalometric analysis
- o Cephalometry
- o Dentition analysis
- o Failure of eruption of teeth
- Diagnosis**
 - o Little's Irregularity Index
 - o Malocclusion
 - o Scissor bite
 - o Standard anatomical position
 - o Tooth ankylosis
 - o Tongue thrust
 - o Overbite
 - o Overjet
 - o Open bite
 - o Crossbite
 - o Dental crowding
 - o Dental spacing
- Conditions**
 - o Bimaxillary Protrusion
 - o Prognathism
 - o Retrognathism
 - o Maxillary hypoplasia
 - o Condylar hyperplasia
 - o Overeruption
 - o Mouth breathing
 - o Temporomandibular dysfunction

- ACCO appliance
- Archwire
- Activator appliance
- Braces
- Damon system
- Elastics
- Frankel appliance
- Invisalign
- Lingual arch
- Lip bumper
- Herbst Appliance
- List of orthodontic functional appliances
- List of palatal expanders
- Lingual braces
- Headgear
- Orthodontic technology
- Orthodontic spacer
- Palatal lift prosthesis
- Palatal expander
- Quad helix
- Retainer
- SureSmile
- Self-ligating braces
- Splint activator
- Twin Block Appliance

Appliances

Procedures

- Anchorage (orthodontics)
- Cantilever mechanics
- Fiberotomy
- Interproximal reduction
- Intrusion (orthodontics)
- Molar distalization
- SARPE
- Serial extraction
- Beta-titanium
- Nickel titanium
- Stainless steel

Materials

- TiMolium
- Elgiloy
- Ceramic
- Composite
- Dental elastics

- Edward Angle
- Spencer Atkinson
- Clifford Ballard
- Raymond Begg
- Hans Peter Bimler
- Samir Bishara
- Arne Björk
- Charles B. Bolton
- Holly Broadbent Sr.
- Allan G. Brodie
- Charles J. Burstone
- Peter Buschang
- Calvin Case
- Harold Chapman (Orthodontist)
- David Di Biase
- Jean Delaire
- Terry Dischinger
- William B. Downs
- John Nutting Farrar
- Rolf Frankel
- Sheldon Friel
- Thomas M. Graber
- Charles A. Hawley
- Reed Holdaway
- John Hooper (Orthodontist)
- Joseph Jarabak
- Harold Kesling
- Albert Ketcham
- Juri Kuroi
- Craven Kurz
- Benno Lischer
- James A. McNamara
- Birte Melsen
- Robert Moyers
- Hayes Nance

**Notable
contributors**

- American Association of Orthodontists
- American Board of Orthodontics
- British Orthodontic Society
- Organizations**
 - Canadian Association of Orthodontists
 - Indian Orthodontic Society
 - Italian Academy of Orthodontic Technology
 - Society for Orthodontic Dental Technology (Germany)
 - American Journal of Orthodontics and Dentofacial Orthopedics
- Journals**
 - The Angle Orthodontist
 - Journal of Orthodontics
- Institution**
 - Angle School of Orthodontia

- Germany
- United States

Authority control databases: National Image not found. Type: unknown **France**
Edit this at Wikidata

- BnF data
- Israel

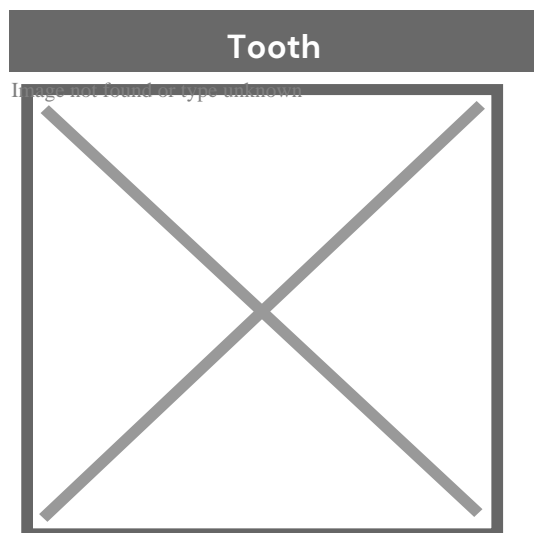
About dental caries

Redirect to:

- Tooth decay
- **From a page move:** This is a redirect from a page that has been moved (renamed). This page was kept as a redirect to avoid breaking links, both internal and external, that may have been made to the old page name.

About tooth

This article is about teeth in general. For specifically human teeth, see Human tooth. For other uses, see Tooth (disambiguation).



A chimpanzee displaying his teeth

Details	
Identifiers	
Latin	<i>dens</i>
MeSH	D014070
FMA	12516

Anatomical terminology

[\[edit on Wikidata\]](#)

A **tooth** (pl.: **teeth**) is a hard, calcified structure found in the jaws (or mouths) of many vertebrates and used to break down food. Some animals, particularly carnivores and omnivores, also use teeth to help with capturing or wounding prey, tearing food, for defensive purposes, to intimidate other animals often including their own, or to carry prey or their young. The roots of teeth are covered by gums. Teeth are not made of bone, but rather of multiple tissues of varying density and hardness that originate from the outermost embryonic germ layer, the ectoderm.

The general structure of teeth is similar across the vertebrates, although there is considerable variation in their form and position. The teeth of mammals have deep roots, and this pattern is also found in some fish, and in crocodilians. In most teleost fish, however, the teeth are attached to the outer surface of the bone, while in lizards they are attached to the inner surface of the jaw by one side. In cartilaginous fish, such as sharks, the teeth are attached by tough ligaments to the hoops of cartilage that form the jaw.^[1]

Monophyodonts are animals that develop only one set of teeth, while diphyodonts grow an early set of deciduous teeth and a later set of permanent or "adult" teeth. Polyphyodonts grow many sets of teeth. For example, sharks, grow a new set of teeth every two weeks to replace worn teeth. Most extant mammals including humans are diphyodonts, but there are exceptions including elephants, kangaroos, and manatees, all of which are polyphyodonts.

Rodent incisors grow and wear away continually through gnawing, which helps maintain relatively constant length. The industry of the beaver is due in part to this qualification. Some rodents, such as voles and guinea pigs (but not mice), as well as lagomorpha (rabbits, hares and pikas), have continuously growing molars in addition to incisors^[2]^[3] Also, tusks (in tusked mammals) grow almost throughout life^[4]

Teeth are not always attached to the jaw, as they are in mammals. In many reptiles and fish, teeth are attached to the palate or to the floor of the mouth, forming additional rows inside those on the jaws proper. Some teleosts even have teeth in the pharynx. While not true teeth in the usual sense, the dermal denticles of sharks are almost identical in structure and are likely to have the same evolutionary origin. Indeed, teeth appear to have first evolved in sharks, and are not found in the more primitive jawless fish – while lampreys do have tooth-like structures on the tongue, these are in fact, composed of keratin, not of dentine or enamel, and bear no relationship to true teeth^[1]] Though "modern" teeth-like structures with dentine and enamel have been found in late conodonts, they are now supposed to have evolved independently of later vertebrates' teeth.^[5]^[6]

Living amphibians typically have small teeth, or none at all, since they commonly feed only on soft foods. In reptiles, teeth are generally simple and conical in shape, although there is some variation between species, most notably the venom-injecting fangs of snakes. The pattern of incisors, canines, premolars and molars is found only in mammals, and to varying extents, in their evolutionary ancestors. The numbers of these types of teeth vary greatly between species; zoologists use a standardised dental formula to describe the precise pattern in any given group.^[1]

Etymology

[edit]

The word *tooth* comes from Proto-Germanic **tanþs*, derived from the Proto-Indo-European **h₂nt-*, which was composed of the root **h₂nt-* 'to eat' plus the active participle suffix **-nt-*, therefore literally meaning 'that which eats'.^[7]

The irregular plural form *teeth* is the result of Germanic umlaut whereby vowels immediately preceding a high vocalic in the following syllable were raised. As the nominative plural ending of the Proto-Germanic consonant stems (to which **tanþs* belonged) was **-iz*, the root vowel in the plural form **tanþiz* (changed by this point to **t^hantiz* via unrelated phonological processes) was raised to /œ̃/ (later unrounded to /ẽ/), and later unrounded to /ẽ/ (later unrounded to /ẽ/), resulting in the **t^hantiz* alternation attested from Old English. Cf. also Old English *b^ook/b^ooks* and *m^use/mⁱce*, from Proto-Germanic **b^oks/b^oks* and **m^us/mⁱs* respectively.

Cognate with Latin *d^{en}tis*, Greek *ὀδόντος* (*odontos*) and Sanskrit *dát*.

Origin

[edit]

Teeth are assumed to have evolved either from ectoderm denticles (scales, much like those on the skin of sharks) that folded and integrated into the mouth (called the "outside-in" theory), or from endoderm pharyngeal teeth (primarily formed in the pharynx of jawless vertebrates) (the "inside-out" theory). In addition, there is another theory stating that neural crest gene regulatory network, and neural crest-derived ectomesenchyme are the key to generate teeth (with any epithelium, either ectoderm or endoderm).[⁴][⁸]

The genes governing tooth development in mammals are homologous to those involved in the development of fish scales.[⁹] Study of a tooth plate of a fossil of the extinct fish *Romundina stellina* showed that the teeth and scales were made of the same tissues, also found in mammal teeth, lending support to the theory that teeth evolved as a modification of scales.[¹⁰]

Mammals

[edit]

Main article: Mammal tooth

Teeth are among the most distinctive (and long-lasting) features of mammal species. Paleontologists use teeth to identify fossil species and determine their relationships. The shape of the animal's teeth are related to its diet. For example, plant matter is hard to digest, so herbivores have many molars for chewing and grinding. Carnivores, on the other hand, have canine teeth to kill prey and to tear meat.

Mammals, in general, are diphyodont, meaning that they develop two sets of teeth. In humans, the first set (the "baby", "milk", "primary" or "deciduous" set) normally starts to appear at about six months of age, although some babies are born with one or more visible teeth, known as neonatal teeth. Normal tooth eruption at about six months is known as teething and can be painful. Kangaroos, elephants, and manatees are unusual among mammals because they are polyphyodonts.

Aardvark

[edit]

In aardvarks, teeth lack enamel and have many pulp tubules, hence the name of the order Tubulidentata.^[11]

Canines

[edit]

In dogs, the teeth are less likely than humans to form dental cavities because of the very high pH of dog saliva, which prevents enamel from demineralizing.^[12] Sometimes called cuspids, these teeth are shaped like points (cusps) and are used for tearing and grasping food.^[13]

Cetaceans

[edit]

Main article: Baleen

Like human teeth, whale teeth have polyp-like protrusions located on the root surface of the tooth. These polyps are made of cementum in both species, but in human teeth, the protrusions are located on the outside of the root, while in whales the nodule is located on the inside of the pulp chamber. While the roots of human teeth are made of cementum on the outer surface, whales have cementum on the entire surface of the tooth with a very small layer of enamel at the tip. This small enamel layer is only seen in older whales where the cementum has been worn away to show the underlying enamel.^[14]

The toothed whale is a parvorder of the cetaceans characterized by having teeth. The teeth differ considerably among the species. They may be numerous, with some dolphins bearing over 100 teeth in their jaws. On the other hand, the narwhals have a

giant unicorn-like tusk, which is a tooth containing millions of sensory pathways and used for sensing during feeding, navigation, and mating. It is the most neurologically complex tooth known. Beaked whales are almost toothless, with only bizarre teeth found in males. These teeth may be used for feeding but also for demonstrating aggression and showmanship.

Primates

[edit]

Main articles: Human tooth and Dental anatomy

In humans (and most other primates), there are usually 20 primary (also "baby" or "milk") teeth, and later up to 32 permanent teeth. Four of these 32 may be third molars or wisdom teeth, although these are not present in all adults, and may be removed surgically later in life.^[15]

Among primary teeth, 10 of them are usually found in the maxilla (i.e. upper jaw) and the other 10 in the mandible (i.e. lower jaw). Among permanent teeth, 16 are found in the maxilla and the other 16 in the mandible. Most of the teeth have uniquely distinguishing features.

Horse

[edit]

Main article: Horse teeth

An adult horse has between 36 and 44 teeth. The enamel and dentin layers of horse teeth are intertwined.^[16] All horses have 12 premolars, 12 molars, and 12 incisors.^[17] Generally, all male equines also have four canine teeth (called tushes) between the molars and incisors. However, few female horses (less than 28%) have canines, and those that do usually have only one or two, which many times are only partially erupted.^[18] A few horses have one to four wolf teeth, which are vestigial premolars, with most of those having only one or two. They are equally common in male and


female horses and much more likely to be on the upper jaw. If present these can cause problems as they can interfere with the horse's bit contact. Therefore, wolf teeth are commonly removed.^[17]

Horse teeth can be used to estimate the animal's age. Between birth and five years, age can be closely estimated by observing the eruption pattern on milk teeth and then permanent teeth. By age five, all permanent teeth have usually erupted. The horse is then said to have a "full" mouth. After the age of five, age can only be conjectured by studying the wear patterns on the incisors, shape, the angle at which the incisors meet, and other factors. The wear of teeth may also be affected by diet, natural abnormalities, and cribbing. Two horses of the same age may have different wear patterns.

A horse's incisors, premolars, and molars, once fully developed, continue to erupt as the grinding surface is worn down through chewing. A young adult horse will have teeth, which are 110–130 mm (4.5–5 inches) long, with the majority of the crown remaining below the gumline in the dental socket. The rest of the tooth will slowly emerge from the jaw, erupting about 3 mm (1/8 in) each year, as the horse ages. When the animal reaches old age, the crowns of the teeth are very short and the teeth are often lost altogether. Very old horses, if lacking molars, may need to have their fodder ground up and soaked in water to create a soft mush for them to eat in order to obtain adequate nutrition.

Proboscideans

[edit]



Section through the ivory tusk of a mammoth

Main article: Elephant ivory

Elephants' tusks are specialized incisors for digging food up and fighting. Some elephant teeth are similar to those in manatees, and elephants are believed to have undergone an aquatic phase in their evolution.

At birth, elephants have a total of 28 molar plate-like grinding teeth not including the tusks. These are organized into four sets of seven successively larger teeth which the elephant will slowly wear through during its lifetime of chewing rough plant material. Only four teeth are used for chewing at a given time, and as each tooth wears out, another tooth moves forward to take its place in a process similar to a conveyor belt. The last and largest of these teeth usually becomes exposed when the animal is around 40 years of age, and will often last for an additional 20 years. When the last of these teeth has fallen out, regardless of the elephant's age, the animal will no longer be able to chew food and will die of starvation.^[19]^[20]


Rabbit

[edit]

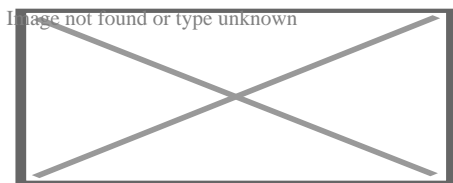
Rabbits and other lagomorphs usually shed their deciduous teeth before (or very shortly after) their birth, and are usually born with their permanent teeth.^[21] The teeth of rabbits complement their diet, which consists of a wide range of vegetation. Since many of the foods are abrasive enough to cause attrition, rabbit teeth grow

continuously throughout life.^[22] Rabbits have a total of six incisors, three upper premolars, three upper molars, two lower premolars, and two lower molars on each side. There are no canines. Dental formula is $\frac{2.0.3.5}{1.0.2.3} = 28$. Three to four millimeters of the tooth is worn away by incisors every week, whereas the cheek teeth require a month to wear away the same amount.^[23]

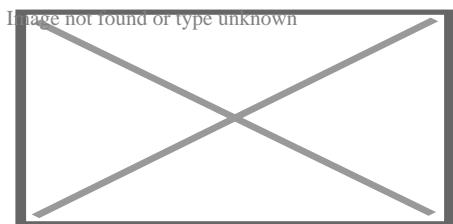
The incisors and cheek teeth of rabbits are called aradicular hypsodont teeth. This is sometimes referred to as an elodont dentition. These teeth grow or erupt continuously. The growth or eruption is held in balance by dental abrasion from chewing a diet high in fiber.



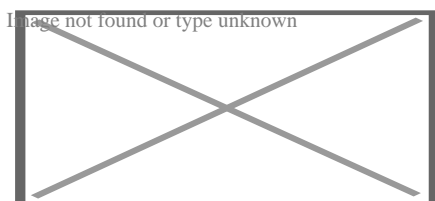
Buccal view of top incisor from *Rattus rattus*. Top incisor outlined in yellow. Molars circled in blue.



Buccal view of the lower incisor from the right dentary of a *Rattus rattus*



Lingual view of the lower incisor from the right dentary of a *Rattus rattus*




Midsagittal view of top incisor from *Rattus rattus*. Top incisor outlined in yellow. Molars circled in blue.

Rodents

[edit]

Rodents have upper and lower hypselodont incisors that can continuously grow enamel throughout its life without having properly formed roots^[24] These teeth are also known as aradicular teeth, and unlike humans whose ameloblasts die after tooth development, rodents continually produce enamel, they must wear down their teeth by gnawing on various materials.^[25] Enamel and dentin are produced by the enamel organ, and growth is dependent on the presence of stem cells, cellular amplification, and cellular maturation structures in the odontogenic region^[26] Rodent incisors are used for cutting wood, biting through the skin of fruit, or for defense. This allows for the rate of wear and tooth growth to be at equilibrium.^[24] The microstructure of rodent incisor enamel has shown to be useful in studying the phylogeny and systematics of rodents because of its independent evolution from the other dental traits. The enamel on rodent incisors are composed of two layers: the inner portio interna (PI) with Hunter-Schreger bands (HSB) and an outer portio externa (PE) with radial enamel (RE)^[27] It usually involves the differential regulation of the epithelial stem cell niche in the tooth of two rodent species, such as guinea pigs.^[28]^[29]



Lingual view of top incisor from *Rattus rattus*. Top incisor outlined in yellow. Molars circled in blue.

The teeth have enamel on the outside and exposed dentin on the inside, so they self-sharpen during gnawing. On the other hand, continually growing molars are found in some rodent species, such as the sibling vole and the guinea pig^[28]^[29] There is variation in the dentition of the rodents, but generally, rodents lack canines and premolars, and have a space between their incisors and molars, called the diastema region.

Manatee

[edit]

Manatees are polyphyodont with mandibular molars developing separately from the jaw and are encased in a bony shell separated by soft tissue^[30]^[31]

Walrus


[edit]

Main article: Walrus ivory

Walrus tusks are canine teeth that grow continuously throughout life^[32]

Fish

[edit]



Teeth of a great white shark

See also: Pharyngeal teeth and Shark tooth

Fish, such as sharks, may go through many teeth in their lifetime. The replacement of multiple teeth is known as polyphyodontia.

A class of prehistoric shark are called cladodonts for their strange forked teeth.

Unlike the continuous shedding of functional teeth seen in modern sharks^[33]^[34] the majority of stem chondrichthyan lineages retained all tooth generations developed throughout the life of the animal.^[35] This replacement mechanism is exemplified by the tooth whorl-based dentitions of acanthodians^[36] which include the oldest known toothed vertebrate, *Qianodus duplicis*^[37].

Amphibians

[edit]

All amphibians have pedicellate teeth, which are modified to be flexible due to connective tissue and uncalcified dentine that separates the crown from the base of the tooth.^[38]

Most amphibians exhibit teeth that have a slight attachment to the jaw or acrodont teeth. Acrodont teeth exhibit limited connection to the dentary and have little enervation.^[39] This is ideal for organisms who mostly use their teeth for grasping, but not for crushing and allows for rapid regeneration of teeth at a low energy cost. Teeth are usually lost in the course of feeding if the prey is struggling. Additionally, amphibians that undergo a metamorphosis develop bicuspid shaped teeth^[40]

Reptiles

[edit]

The teeth of reptiles are replaced constantly throughout their lives. Crocodylian juveniles replace teeth with larger ones at a rate as high as one new tooth per socket every month. Once mature, tooth replacement rates can slow to two years and even

longer. Overall, crocodylians may use 3,000 teeth from birth to death. New teeth are created within old teeth.^[41]

Birds


[edit]

Main article: Ichthyornis

A skull of Ichthyornis discovered in 2014 suggests that the beak of birds may have evolved from teeth to allow chicks to escape their shells earlier, and thus avoid predators and also to penetrate protective covers such as hard earth to access underlying food.^[42]^[43]

Invertebrates

[edit]




The European medicinal leech has three jaws with numerous sharp teeth which function like little saws for incising a host.

True teeth are unique to vertebrates,^[44] although many invertebrates have analogous structures often referred to as teeth. The organisms with the simplest genome bearing such tooth-like structures are perhaps the parasitic worms of the family Ancylostomatidae.^[45] For example, the hookworm *Necator americanus* has two dorsal and two ventral cutting plates or teeth around the anterior margin of the buccal capsule. It also has a pair of subdorsal and a pair of subventral teeth located close to the rear.^[46]

Historically, the European medicinal leech, another invertebrate parasite, has been used in medicine to remove blood from patients.^[47] They have three jaws (tripartite) that resemble saws in both appearance and function, and on them are about 100 sharp teeth used to incise the host. The incision leaves a mark that is an inverted Y inside of a circle. After piercing the skin and injecting anticoagulants (hirudin) and anaesthetics, they suck out blood, consuming up to ten times their body weight in a single meal.^[48]

In some species of Bryozoa, the first part of the stomach forms a muscular gizzard lined with chitinous teeth that crush armoured prey such as diatoms. Wave-like peristaltic contractions then move the food through the stomach for digestion.^[49]



The limpet rasps algae from rocks using teeth with the strongest known tensile strength of any biological material.

Molluscs have a structure called a radula, which bears a ribbon of chitinous teeth. However, these teeth are histologically and developmentally different from vertebrate teeth and are unlikely to be homologous. For example, vertebrate teeth develop from a neural crest mesenchyme-derived dental papilla, and the neural crest is specific to vertebrates, as are tissues such as enamel.^[44]

The radula is used by molluscs for feeding and is sometimes compared rather inaccurately to a tongue. It is a minutely toothed, chitinous ribbon, typically used for scraping or cutting food before the food enters the oesophagus. The radula is unique to molluscs, and is found in every class of mollusc apart from bivalves.

Within the gastropods, the radula is used in feeding by both herbivorous and carnivorous snails and slugs. The arrangement of teeth (also known as denticles) on the radula ribbon varies considerably from one group to another as shown in the diagram on the left.

Predatory marine snails such as the Naticidae use the radula plus an acidic secretion to bore through the shell of other molluscs. Other predatory marine snails, such as the Conidae, use a specialized radula tooth as a poisoned harpoon. Predatory pulmonate land slugs, such as the ghost slug, use elongated razor-sharp teeth on the radula to seize and devour earthworms. Predatory cephalopods, such as squid, use the radula for cutting prey.

In most of the more ancient lineages of gastropods, the radula is used to graze by scraping diatoms and other microscopic algae off rock surfaces and other substrates. Limpets scrape algae from rocks using radula equipped with exceptionally hard rasping teeth.^[50] These teeth have the strongest known tensile strength of any biological material, outperforming spider silk.^[50] The mineral protein of the limpet teeth can withstand a tensile stress of 4.9 GPa, compared to 4 GPa of spider silk and 0.5 GPa of human teeth.^[51]

Fossilization and taphonomy

[edit]



Because teeth are very resistant, often preserved when bones are not,^[52] and reflect the diet of the host organism, they are very valuable to archaeologists and palaeontologists.^[53] Early fish such as the thelodonts had scales composed of dentine and an enamel-like compound, suggesting that the origin of teeth was from scales which were retained in the mouth. Fish as early as the late Cambrian had dentine in their exoskeletons, which may have functioned in defense or for sensing their environments.^[54] Dentine can be as hard as the rest of teeth and is composed of collagen fibres, reinforced with hydroxyapatite.^[54]

Though teeth are very resistant, they also can be brittle and highly susceptible to cracking.^[55] However, cracking of the tooth can be used as a diagnostic tool for predicting bite force. Additionally, enamel fractures can also give valuable insight into the diet and behaviour of archaeological and fossil samples.

Decalcification removes the enamel from teeth and leaves only the organic interior intact, which comprises dentine and cementine.^[56] Enamel is quickly decalcified in acids,^[57] perhaps by dissolution by plant acids or via diagenetic solutions, or in the stomachs of vertebrate predators.^[56] Enamel can be lost by abrasion or spalling,^[56] and is lost before dentine or bone are destroyed by the fossilisation process.^[57] In such a case, the 'skeleton' of the teeth would consist of the dentine, with a hollow pulp cavity.^[56] The organic part of dentine, conversely, is destroyed by alkalis.^[57]

See also

[edit]

-  [Medicine portal](#)
-  [Image: Tooth of type unknown](#)
- Animal tooth development
- Dragon's teeth (mythology)

References

[edit]

- ^** **abc** *Romer, Alfred Sherwood; Parsons, Thomas S. (1977). The Vertebrate Body. Philadelphia, PA: Holt-Saunders International. pp. 300–310. ISBN 978-0-03-910284-5*.
- ^** *Tummers M, Thesleff I (March 2003). "Root or crown: a developmental choice orchestrated by the differential regulation of the epithelial stem cell niche in the tooth of two rodent species". Development. 130 (6): 1049–57. doi:10.1242/dev.00332. PMID 12571097.*
- ^** *Hunt AM (1959). "A description of the molar teeth and investing tissues of normal guinea pigs". J. Dent. Res. 38 (2): 216–31. doi:10.1177/00220345590380020301. PMID 13641521. S2CID 45097018.*
- ^** **ab** *Nasoori, Alireza (2020). "Tusks, the extra-oral teeth". Archives of Oral Biology. 117: 104835. doi:10.1016/j.archoralbio.2020.104835. PMID 32668361. S2CID 220585014.*

5. ^ McCOLLUM, MELANIE; SHARPE, PAUL T. (July 2001). "Evolution and development of teeth". *Journal of Anatomy*. **199** (1–2): 153–159. doi:10.1046/j.1469-7580.2001.19910153.x. PMC 1594990. PMID 11523817.
6. ^ Kaplan, Matt (October 16, 2013). "Fossil scans reveal origins of teeth". *Nature*. doi:10.1038/nature.2013.13964 – via www.nature.com.
7. ^ Harper, Douglas (2001–2021). "tooth | Origin and meaning of tooth". *Online Etymology Dictionary*.
8. ^ Jheon, Andrew H (2012). "From molecules to mastication: the development and evolution of teeth". *Wiley Interdiscip Rev Dev Biol*. **2** (2): 165–182. doi:10.1002/wdev.63. PMC 3632217. PMID 24009032.
9. ^ Sharpe, P. T. (2001). "Fish scale development: Hair today, teeth and scales yesterday?". *Current Biology*. **11** (18): R751 – R752. Bibcode:2001CBio...11.R751S. doi:10.1016/S0960-9822(01)00438-9. PMID 11566120. S2CID 18868124.
10. ^ Jennifer Viegas (June 24, 2015). "First-known teeth belonged to fierce fish". *ABC Science*. Retrieved June 28, 2015.
11. ^ Shoshani 2002, p. 619
12. ^ Hale, FA (2009). "Dental caries in the dog". *Can. Vet. J.* **50** (12): 1301–4. PMC 2777300. PMID 20190984.
13. ^ "Types of Teeth, Dental Anatomy & Tooth Anatomy | Colgate®". www.colgate.com. Archived from the original on 2017-11-19. Retrieved 2017-11-19.
14. ^ "Common Characteristics Of Whale Teeth". Archived from the original on 4 September 2011. Retrieved 18 July 2014.
15. ^ "Everything you need to know about teeth". NHS Scotland. Retrieved 5 May 2020.
16. ^ "Gummed Out: Young Horses Lose Many Teeth, Vet Says". Archived from the original on 8 July 2014. Retrieved 6 July 2014.
17. ^ **a b** Patricia Pence (2002). *Equine Dentistry: A Practical Guide*. Baltimore: Lippincott Williams & Wilkins. ISBN 978-0-683-30403-9.
18. ^ Al Cirelli. "Equine Dentition" (PDF). University of Nevada Reno. SP-00-08. Retrieved 7 June 2010.
19. ^ Maurice Burton; Robert Burton (2002). *International Wildlife Encyclopedia*. Marshall Cavendish. p. 769. ISBN 978-0-7614-7266-7.
20. ^ Bram, L. et al. MCMLXXXIII. *Elephants*. Funk & Wagnalls New Encyclopedia, Volume 9, p. 183. ISBN 0-8343-0051-6
21. ^ "Dental Anatomy & Care for Rabbits and Rodents".
22. ^ Brown, Susan. Rabbit Dental Diseases Archived 2007-10-14 at the Wayback Machine, hosted on the San Diego Chapter of the House Rabbit Society Archived 2007-10-13 at the Wayback Machine. Page accessed April 9, 2007.

23. ^ Rydavy, Robin. Hay & Dental Health, hosted by the Missouri House Rabbit Society–Kansas City. Page accessed January 2, 2024.
24. ^ **a b** Cox, Philip; Hautier, Lionel (2015). *Evolution of the Rodents: Advances in Phylogeny, Functional Morphology and Development*. Cambridge University Press. p. 482. ISBN 9781107044333.
25. ^ Caceci, Thomas. *Veterinary Histology* with subtitle "Digestive System: Oral Cavity" found here Archived 2006-04-30 at the Wayback Machine.
26. ^ Gomes, J.r.; Omar, N.f.; Do Carmo, E.r.; Neves, J.s.; Soares, M.a.m.; Narvaes, E.a.; Novaes, P.d. (30 April 2013). "Relationship Between Cell Proliferation and Eruption Rate in the Rat Incisor". *The Anatomical Record*. **296** (7): 1096–1101. doi:10.1002/ar.22712. ISSN 1932-8494. PMID 23629828. S2CID 13197331.
27. ^ Martin, Thomas (September 1999). "Evolution of Incisor Enamel Microstructure in Theridomyidae (Rodentia)". *Journal of Vertebrate Paleontology*. **19** (3): 550. Bibcode:1999JVPal..19..550M. doi:10.1080/02724634.1999.10011164.
28. ^ **a b** Tummers M and Thesleff I. Root or crown: a developmental choice orchestrated by the differential regulation of the epithelial stem cell niche in the tooth of two rodent species. *Development* (2003). 130(6):1049–57.
29. ^ **a b** AM Hunt. A description of the molar teeth and investing tissues of normal guinea pigs. *J Dent Res*. (1959) 38(2):216–31.
30. ^ Shoshani, J., ed. (2000). *Elephants: Majestic Creatures of the Wild*. Checkmark Books. ISBN 0-87596-143-6.
31. ^ Best, Robin (1984). Macdonald, D. (ed.). *The Encyclopedia of Mammals*. New York: Facts on File. pp. 292–298. ISBN 0-87196-871-1.
32. ^ The Permanent Canine Teeth, hosted on the University of Illinois at Chicago website. Page accessed February 5, 2007.
33. ^ Underwood, Charlie; Johanson, Zerina; Smith, Moya Meredith (November 2016). "Cutting blade dentitions in squaliform sharks form by modification of inherited alternate tooth ordering patterns". *Royal Society Open Science*. **3** (11): 160385. Bibcode:2016RSOS....360385U. doi:10.1098/rsos.160385. ISSN 2054-5703. PMC 5180115. PMID 28018617. S2CID 12821592.
34. ^ Fraser, Gareth J.; Thiery, Alex P. (2019), Underwood, Charlie; Richter, Martha; Johanson, Zerina (eds.), "Evolution, Development and Regeneration of Fish Dentitions", *Evolution and Development of Fishes*, Cambridge: Cambridge University Press, pp. 160–171, doi:10.1017/9781316832172.010, ISBN 978-1-107-17944-8, S2CID 92225621, retrieved 2022-10-22
35. ^ Rücklin, Martin; King, Benedict; Cunningham, John A.; Johanson, Zerina; Marone, Federica; Donoghue, Philip C. J. (2021-05-06). "Acanthodian dental development and

- the origin of gnathostome dentitions". Nature Ecology & Evolution. 5 (7): 919–926. Bibcode:2021NatEE...5..919R. doi:10.1038/s41559-021-01458-4. hdl:1983/27f9a13a-1441-410e-b9a7-116b42cd40f7. ISSN 2397-334X. PMID 33958756. S2CID 233985000.*
36. ^ Burrow, Carole (2021). *Acanthodii, Stem Chondrichthyes*. Verlag Dr. Friedrich Pfeil. ISBN 978-3-89937-271-7. OCLC 1335983356.
 37. ^ Andreev, Plamen S.; Sansom, Ivan J.; Li, Qiang; Zhao, Wenjin; Wang, Jianhua; Wang, Chun-Chieh; Peng, Lijian; Jia, Liantao; Qiao, Tuo; Zhu, Min (September 2022). "The oldest gnathostome teeth". *Nature*. **609** (7929): 964–968. Bibcode:2022Natur.609..964A. doi:10.1038/s41586-022-05166-2. ISSN 1476-4687. PMID 36171375. S2CID 252569771.
 38. ^ Pough, Harvey. *Vertebrate Life*. 9th Ed. Boston: Pearson Education, Inc., 2013. 211–252. Print.
 39. ^ Kardong, Kenneth (1995). *Vertebrate: Comparative Anatomy, Function, Evolution* New York: McGraw–Hill. pp. 215–225. ISBN 9780078023026.
 40. ^ Xiong, Jianli (2014). "Comparison of vomerine tooth rows in juvenile and adult *Hynobius guabangshanensis*". *Vertebrate Zoology*. **64**: 215–220.
 41. ^ Poole, D. F. G. (January 1961). "Notes on Tooth Replacement in the Nile Crocodile *Crocodilus niloticus*". *Proceedings of the Zoological Society of London*. **136** (1): 131–140. doi:10.1111/j.1469-7998.1961.tb06083.x.
 42. ^ Hersher, Rebecca (May 2, 2018). "How Did Birds Lose Their Teeth And Get Their Beaks? Study Offers Clues". NPR.
 43. ^ Field, Daniel J.; Hanson, Michael; Burnham, David; Wilson, Laura E.; Super, Kristopher; Ehret, Dana; Ebersole, Jun A.; Bhullar, Bhart–Anjan S. (May 31, 2018). "Complete Ichthyornis skull illuminates mosaic assembly of the avian head". *Nature* Vol 557, pp 96 – 100.
 44. ^ **a b** Kardong, Kenneth V. (1995). *Vertebrates: comparative anatomy, function, evolution*. McGraw–Hill. pp. 55, 57. ISBN 978-0-697-21991-6.
 45. ^ "Ancylostoma duodenale". *Nematode.net Genome Sequencing Center*. Archived from the original on 2008-05-16. Retrieved 2009-10-27.
 46. ^ Roberts, Larry S., and John Janovy, Jr. *Foundations of Parasitology*. Seventh ed. Singapore: McGraw–Hill, 2006.
 47. ^ Brian Payton (1981). *Kenneth Muller; John Nicholls; Gunther Stent (eds.). Neurobiology of the Leech*. New York: Cold Spring Harbor Laboratory. pp. 27–34. ISBN 978-0-87969-146-2.

48. ^ Wells MD, Manktelow RT, Boyd JB, Bowen V (1993). "The medical leech: an old treatment revisited". *Microsurgery*. **14** (3): 183–6. doi:10.1002/micr.1920140309. PMID 8479316. S2CID 27891377.
49. ^ Ruppert, E.E.; Fox, R.S.; Barnes, R.D. (2004). "Lophoporata". *Invertebrate Zoology* (7 ed.). Brooks / Cole. pp. 829–845. ISBN 978-0-03-025982-1.
50. ^ **a b** Asa H. Barber; Dun Lu; Nicola M. Pugno (18 February 2015), "Extreme strength observed in limpet teeth", *Journal of the Royal Society Interface*, **12** (105): 20141326, doi:10.1098/rsif.2014.1326, PMC 4387522, PMID 25694539
51. ^ Zachary Davies Boren (18 February 2015). "The strongest materials in the world: Limpet teeth beats record resistance of spider silk". *The Independent*. Retrieved 20 February 2015.
52. ^ *Taphonomy: A Process Approach*. Ronald E. Martin. Illustrated edition. Cambridge University Press, 1999. ISBN 978-0-521-59833-0
53. ^ Towle, Ian; Irish, Joel D.; De Groote, Isabelle (2017). "Behavioral inferences from the high levels of dental chipping in *Homo naledi*". *American Journal of Physical Anthropology*. **164** (1): 184–192. doi:10.1002/ajpa.23250. PMID 28542710. S2CID 24296825. Retrieved 2019-01-09.
54. ^ **a b** Teaford, Mark F and Smith, Moya Meredith, 2007. *Development, Function and Evolution of Teeth*, Cambridge University Press. ISBN 978-0-521-03372-5, Chapter 5.
55. ^ Lee, James J.-W.; Constantino, Paul J.; Lucas, Peter W.; Lawn, Brian R. (2011-11-01). "Fracture in teeth—a diagnostic for inferring bite force and tooth function". *Biological Reviews*. **86** (4): 959–974. doi:10.1111/j.1469-185x.2011.00181.x. ISSN 1469-185X. PMID 21507194. S2CID 205599560.
56. ^ **a b c d** Fisher, Daniel C (1981). "Taphonomic Interpretation of Enamel-Less Teeth in the Shotgun Local Fauna (Paleocene, Wyoming)". *Museum of Paleontology Contributions, the University of Michigan*. **25** (13): 259–275. hdl:2027.42/48503.
57. ^ **a b c** Fernandez-Jalvo, Y.; Sanchez-Chillon, B.; Andrews, P.; Fernandez-Lopez, S.; Alcalá Martínez, L. (2002). "Morphological taphonomic transformations of fossil bones in continental environments, and repercussions on their chemical composition" (PDF) . *Archaeometry*. **44** (3): 353–361. doi:10.1111/1475-4754.t01-1-00068.

Sources

[edit]

- Shoshani, Jeheskel (2002). "Tubulidentata". In Robertson, Sarah (ed.). *Encyclopedia of Life Sciences*. Vol. 18: Svedberg, Theodor to Two-hybrid and Related Systems. London, UK: Nature Publishing Group. ISBN 978-1-56159-274-6.

State : Hrvatska

Zip : 10000

Address : IQDENT – Ortodontska Klinika

Company Website : <https://iqdent.hr/>

USEFUL LINKS

[Orthodontic treatment can help improve your child's smile](#)

[Orthodontic treatment for children](#)

[Sitemap](#)

[Privacy Policy](#)

[About Us](#)

Follow us