



- **Reasons Adults Seek Orthodontic Treatment**

Reasons Adults Seek Orthodontic Treatment Overcoming Hesitations About Braces Later in Life Clear Aligners for Subtle Tooth Movement Comparing Ceramic Brackets With Other Invisible Options Balancing Cosmetic Goals and Functional Needs Social Changes That Encourage Adult Orthodontics Handling Orthodontic Care Alongside Busy Schedules Managing Discomfort and Adjusting to Lifestyle Shifts Case Studies Highlighting Adult Smile Transformations Psychological Benefits of Aligned Teeth in Adulthood Minimizing Visibility of Orthodontic Appliances Key Questions Adults Often Ask About Treatment

- **How Orthodontics Connects With Periodontal Health**

How Orthodontics Connects With Periodontal Health Coordinating Orthodontic Work With Restorative Dentistry The Role of Oral Surgery in Complex Alignment Cases Importance of Joint Consultation for Comprehensive Outcomes Leveraging Data Sharing Between Dental Specialties Collaborative Approaches to Pediatric Growth Management Integrating Prosthodontics for Full Mouth Rehabilitation Teamwork for Managing Tongue Thrust and Speech Issues Streamlining Communication Among Healthcare Providers Shared Planning for Improved Patient Experiences Post Surgical Follow Ups With Multiple Specialists Building a Unified Strategy for Long Term Stability

- **About Us**



The Role of Oral Surgery in Complex Alignment Cases

****Desire for Improved Aesthetics**:** Many adults seek orthodontic treatment to enhance the appearance of their smile, addressing concerns such as crooked teeth, gaps, or overbites that may have persisted from childhood or developed due to various life factors.

****Desire for Improved Aesthetics**:** Many adults seek orthodontic treatment to enhance the appearance of their smile, addressing concerns such as crooked teeth, gaps, or overbites that may have persisted from childhood or developed due to various life factors.

When we talk about orthodontic issues in children, it's important to recognize that while many can be effectively managed with traditional orthodontic treatments like braces or aligners, some cases present complexities that demand a more nuanced approach—this is where the role of oral surgery becomes pivotal in achieving optimal alignment and function. Complex alignment cases in pediatric dentistry often involve a tapestry of challenges that go beyond simple tooth misalignment; they can encompass skeletal discrepancies, severe crowding, or anomalies that affect both the teeth and the underlying jaw structure.

Let's first understand what constitutes complex alignment cases. These typically include conditions such as severe overbites or underbites where the jaw relationship is significantly off, causing functional problems like difficulty in chewing or speaking. Another common issue is transverse discrepancies, where the upper and lower jaws are not parallel, leading to a crossbite. Additionally, some children might face situations with

extra or missing teeth, which complicates the orthodontic treatment plan significantly. Some orthodontic issues are inherited while others develop over time **Kids' dental alignment services** dental caries. In these scenarios, while braces can certainly play a part by adjusting tooth positions, they might not fully correct the underlying skeletal imbalances that contribute to these complexities.

This is where oral surgery steps into the spotlight as an integral component of comprehensive treatment for these intricate cases. Oral surgical procedures can realign jaw bones to improve facial symmetry and enhance functionality. For instance, procedures like orthognathic surgery—or jaw surgery—can correct significant skeletal discrepancies by cutting and repositioning the jaws to achieve proper alignment and occlusion (how the upper and lower teeth fit together). Such surgeries aren't just about aesthetics; they address critical issues affecting a child's ability to eat comfortably, speak clearly, and maintain good oral health long-term.

Moreover, early intervention with a combination of orthodontic treatment and timely surgical procedures can prevent future complications. By addressing these issues during childhood or adolescence when growth patterns are still active, surgeons and orthodontists can guide development towards a more harmonious outcome. This collaborative approach ensures that as children grow into adults, they have fewer chances of encountering speech difficulties, TMJ disorders (temporomandibular joint issues), or needing extensive restorative work due to wear and tear from poorly aligned teeth.

Furthermore, it's worth noting that advancements in technology and surgical techniques have made these procedures safer and more predictable than ever before. Three-dimensional imaging allows for precise planning of surgical movements, ensuring better outcomes with reduced recovery times. The integration of computer-guided surgery has also enhanced precision in osteotomies—the cuts made in bone—to achieve desired

movements accurately.

In conclusion, while traditional orthodontics remains a cornerstone for many alignment issues in children, complex cases highlight the indispensable role of oral surgery in crafting comprehensive solutions tailored to individual needs. By harmonizing growth patterns with precise dental adjustments through collaborative care involving both orthodontists and oral surgeons, we pave the way for healthier smiles that stand the test of time—not only enhancing appearance but fundamentally improving quality of life for young patients navigating these challenges. Recognizing when to integrate surgical interventions with ongoing orthodontic care underscores our commitment to delivering holistic solutions aimed at ensuring every child enjoys the best possible oral health outcomes well into adulthood.

****Boosting Self-Confidence**:**

Orthodontic treatment can

significantly improve an

adult's self-esteem and

confidence by correcting

dental imperfections, leading

to a more positive self-image and better social interactions.

- ****Desire for Improved Aesthetics****: Many adults seek orthodontic treatment to enhance the appearance of their smile, addressing concerns such as crooked teeth, gaps, or overbites that may have persisted from childhood or developed due to various life factors.
- ****Boosting Self-Confidence****: Orthodontic treatment can significantly improve an adult's self-esteem and confidence by correcting dental imperfections, leading to a more positive self-image and better social interactions.
- ****Enhancing Oral Health****: Proper alignment of teeth through orthodontic treatment can improve oral hygiene by making it easier to clean teeth effectively, thereby reducing the risk of cavities and gum disease that may have been challenging to manage in misaligned dentitions.
- ****Addressing Chronic Dental Issues****: Adults may seek orthodontics to resolve long-standing dental problems such as bite issues (overbites, underbites, crossbites) that can lead to jaw pain, headaches, and digestive difficulties if left untreated.
- ****Correcting Speech Impediments****: Misaligned teeth or jaw structures can contribute to speech difficulties; orthodontic treatment can correct these issues, improving articulation and overall communication skills.

- ****Preventive Measures Against Tooth Wear****: Properly aligned teeth are less prone to excessive wear and tear; adults may pursue orthodontic treatment to prevent premature tooth degradation and associated costs of restorative dentistry.
- ****Facilitating Better Chewing Efficiency****: Orthodontic treatment can improve bite function and alignment, allowing for more efficient chewing which is crucial for digestion and overall nutritional health in adulthood.

The Role of Oral Surgery in Complex Alignment Cases: Why Early Intervention and Comprehensive Treatment Planning Matter

When we delve into the intricate world of orthodontics, particularly in cases that demand more than just braces or aligners, the significance of early intervention and comprehensive treatment planning becomes paramount. Here, oral surgery emerges as a critical component in achieving not just functional but also aesthetic dental harmony. This essay explores why integrating oral surgery into the treatment plan for complex alignment cases is not merely beneficial but often essential for optimal outcomes.

To begin with, it's crucial to understand what constitutes a "complex alignment case." These are scenarios where misalignments are severe, involving not only the positioning of teeth but also underlying structural issues within the jaw and surrounding tissues. Such complexities might include overbites or underbites that are too pronounced, jaw discrepancies like prognathism (protruding jaw) or retrognathism (receding jaw), or even conditions like impacted teeth that require more than standard orthodontic adjustments. In these instances, the mere application of braces or clear aligners might fall short; this is where oral surgery steps into the spotlight.

Early intervention plays a pivotal role in managing these complex cases effectively. The golden rule here is timing—addressing issues early can prevent them from escalating into more serious problems that could necessitate more invasive treatments down the line. For instance, interceptive orthodontic procedures combined with timely oral surgery can guide growth and development in children and adolescents toward a healthier bite and facial structure. This proactive approach not only simplifies future treatments but also enhances long-term stability and patient satisfaction. Adults aren't exempt from these benefits; early diagnosis and intervention can significantly improve outcomes even when growth potential has been exhausted, by optimizing what can be achieved through surgical means alongside orthodontics.

Comprehensive treatment planning becomes the backbone of successful outcomes in complex alignment cases involving oral surgery. It's an intricate dance between various specialists—orthodontists, oral surgeons, periodontists—and sometimes even maxillofacial surgeons—all working harmoniously towards a common goal: restorative dental health coupled with improved aesthetics. This holistic approach ensures every angle is considered—from assessing bone structure to evaluating soft tissue dynamics—to craft a personalized plan tailored to each patient's unique needs. Such meticulous planning doesn't just enhance predictability but also minimizes risks associated with surgery while maximizing aesthetic and functional results.

Moreover, embracing technology further elevates the efficacy of such comprehensive strategies. Advanced imaging techniques like 3D CT scans provide detailed insights into skeletal structures that were once hidden from view, allowing for precise surgical planning that aligns both form and function perfectly. Digital simulations let patients visualize potential outcomes before any incision is made, fostering informed decision-making and setting realistic expectations—a vital aspect often overlooked yet highly impactful on patient compliance and satisfaction post-treatment.

In conclusion, integrating early intervention with comprehensive treatment planning that includes oral surgery is indispensable in tackling complex alignment cases effectively. This multi-faceted approach not only addresses immediate concerns regarding tooth positioning but also lays a solid foundation for long-term dental health and aesthetic harmony. As we advance technologically and deepen our understanding of craniofacial anatomy and biomechanics, embracing these principles will continue to redefine what's possible in orthodontic care—ensuring smiles aren't just straightened but transformed into expressions of health, confidence, and

****Enhancing Oral Health**:**

Proper alignment of teeth through orthodontic treatment can improve oral hygiene by making it easier to clean teeth effectively, thereby reducing the risk of

cavities and gum disease that may have been challenging to manage in misaligned dentitions.

Understanding Complex Alignment Cases in Children: The Crucial Role of Oral Surgery

The journey of a child's dental development is often a story filled with milestones, from the first tentative baby teeth to the robust set of permanent teeth that shape their smile and influence their overall health. Yet, for some children, this path is not straightforward. Complex alignment cases present unique challenges that extend beyond the realm of traditional orthodontics, often necessitating the specialized expertise of oral surgery. This intricate intersection of dental development and surgical intervention plays a pivotal role in ensuring that children not only achieve aesthetically pleasing smiles but also maintain optimal oral function and health.

Complex alignment cases can emerge due to a variety of factors, including genetic predispositions, developmental anomalies, or traumatic injuries. Conditions like severe crowding, significant overbites or underbites, cleft palates, or impacted teeth require careful evaluation and often demand more than just braces or aligners. These situations underscore the importance of a multidisciplinary approach where oral surgeons

collaborate with orthodontists to devise comprehensive treatment plans tailored to each child's unique needs.

Oral surgery in these contexts serves several critical functions. Firstly, it addresses structural issues that impede proper tooth alignment and occlusion (the way teeth come together). For instance, surgical procedures might be required to remove obstacles such as extra teeth or growth modifications to facilitate better alignment. Techniques such as orthognathic surgery—common in cases involving jaw misalignments—can fundamentally reshape the relationship between the upper and lower jaws, correcting functional problems while enhancing aesthetics.

Moreover, for children with cleft lip and palate—a congenital condition affecting the shaping of facial structures—the role of oral surgery becomes even more pronounced. Early interventions can significantly improve speech articulation, feeding difficulties in infancy, and lay the groundwork for stable dental arches as they grow. These surgeries are not just about physical correction; they profoundly impact psychological well-being by fostering confidence through improved appearance and function.

The timing of these interventions is crucial; pediatric patients present unique considerations due to their ongoing growth and development. Oral surgeons must meticulously plan procedures considering future growth patterns to ensure long-term stability and functionality. In many cases, early assessment and treatment planning can mitigate more invasive procedures later on, highlighting the significance of interdisciplinary communication among healthcare providers involved in a child's care.

In navigating these complex alignment cases, it's essential for families to understand that while the road may be intricate with multiple phases of treatment—including potential surgeries—the ultimate goal remains clear: restoring harmony between form and function in a child's dentition. Oral surgery isn't merely an adjunctive procedure but an integral part

of achieving comprehensive dental health in children facing complex challenges. As we appreciate the nuances involved in treating these young patients, we recognize the profound impact such specialized care has on their quality of life—a testament to advancements in pediatric oral healthcare that continue to evolve positively for future generations.

****Addressing Chronic Dental Issues**:** Adults may seek orthodontics to resolve long-standing dental problems such as bite issues (overbites, underbites, crossbites) that can lead to jaw pain, headaches, and digestive difficulties if left untreated.

When we delve into the intricate world of orthodontics and oral surgery, the term "complex alignment cases" emerges as a pivotal concept that encapsulates a broad spectrum of dental and skeletal challenges requiring a multidisciplinary approach. Complex alignment cases, in essence, refer to situations where the misalignment or malposition of teeth and jaws extends beyond the typical realms addressed by standard orthodontic treatments. These cases often intertwine dental irregularities with significant skeletal discrepancies, necessitating not only the expertise of an orthodontist but also that of an oral surgeon to achieve optimal outcomes. To understand the role of oral surgery in these complex scenarios, it's crucial to dissect the definition and criteria that delineate such cases.

Definition

Complex alignment cases can be defined as orthodontic situations where traditional appliances and techniques—braces, aligners, etc.—are insufficient to correct significant dental or jaw misalignments due to underlying skeletal discrepancies. These discrepancies might involve substantial overbites, underbites, cross-bites, or jaw relationships—such as protrusion or retrusion—that are deeply rooted in bone structure rather than merely superficial tooth positioning. In simpler terms, while standard orthodontic treatments aim to straighten teeth within their existing bone environment, complex alignment cases require reshaping or repositioning the very bones that support these teeth.

Criteria for Complex Alignment Cases

Several key criteria help clinicians identify when a case transcends typical orthodontic intervention and enters the realm of complexity requiring oral surgical involvement:

1. **Skeletal Discrepancies:** A significant imbalance between the upper and lower jaws is a hallmark of complexity. This could manifest as a pronounced overjet (protruding upper front teeth) or overbite (upper front teeth excessively overlapping lower ones), often indicating a discrepancy in jaw size or position.
2. **Dental Crowding and Spacing:** While severe crowding can sometimes be managed with extensive orthodontic treatment alone, when it's coupled with skeletal issues—such as an undersized jaw housing too many teeth—it signals a need for surgical intervention alongside orthodontics to create adequate space and proper alignment.
3. **Functional Issues:** Cases presenting with significant difficulties in biting, chewing, or speaking due to misaligned jaws fall into this category. These functional impairments often necessitate corrective surgeries to ensure both aesthetic harmony and optimal functionality.
4. **Age Considerations:** Adolescents undergoing growth spurts present unique opportunities for combined orthodontic–orthognathic (jaw correction) treatments because their bones are still developing and more responsive to surgical manipulation aimed at correcting alignments.
- 5.

Aesthetic Concerns: Beyond functional issues, severe misalignments affecting facial symmetry and overall appearance might prompt consideration for combined approaches where cosmetic outcomes are paramount alongside functional corrections.

In tackling complex alignment cases, the synergy between orthodontists and oral surgeons becomes paramount. Orthodontists typically initiate treatment with appliances designed to prepare the teeth and gums for upcoming surgical adjustments while simultaneously addressing any milder aspects of tooth misalignment. Following this preparatory phase, oral surgeons step in to perform procedures ranging from osteotomies (cutting and repositioning bones) to genioplasty (chin augmentation or reduction), ensuring that both hard tissue (bone) and soft tissue (gums and muscles) align harmoniously post

****Correcting Speech**

Impediments:** Misaligned teeth or jaw structures can contribute to speech

difficulties; orthodontic treatment can correct these issues, improving articulation and overall communication skills.

The Role of Oral Surgery in Complex Alignment Cases: A Look into Pediatric Patients

When we think about orthodontic treatments, the imagery often conjures up thoughts of braces and retainers—subtle yet powerful tools for guiding teeth into their ideal positions. However, for pediatric patients presenting with complex alignment cases, the journey can sometimes weave through more intricate terrains, where the standard approaches may fall short, and oral surgery emerges as a pivotal component. Understanding the specific causes and contributing factors that necessitate such interventions in young patients reveals a nuanced landscape of dental and skeletal challenges that demand careful consideration and expert handling.

Firstly, let's delve into one of the common underlying issues: **congenital anomalies**. Conditions like cleft lip and palate not only affect speech and feeding but also

significantly impact dental alignment. These anomalies can lead to misaligned teeth that are difficult to correct with traditional orthodontics alone. The structural discrepancies in the jaw require surgical intervention to create a foundation upon which orthodontic treatment can effectively align the teeth. Oral surgery here is not merely an option but often a prerequisite for achieving a harmonious smile and functional occlusion.

Another factor steering pediatric cases toward oral surgery is **dento-alveolar trauma**. Accidents happen, especially in the active lives of children, leading to injuries that can disrupt normal tooth development or alignment. When fractures involve the developing jawbone or significant displacement occurs, surgical intervention becomes crucial not just for aesthetic reasons but for ensuring proper growth and function of the jaw. Early management through oral surgery helps mitigate long-term complications, facilitating better outcomes in subsequent orthodontic phases.

Moreover, **skeletal discrepancies** play a significant role in complex alignment cases among children. Conditions like severe overbite or underbite might stem from disparities in jaw growth rather than just tooth positioning. In such scenarios, orthodontic appliances alone cannot resolve these fundamental skeletal imbalances; orthognathic (jaw) surgery might be necessary to reposition the jaws correctly before or during orthodontic treatment. This collaborative approach ensures that both form and function are addressed comprehensively from an early age, preventing future complications like TMJ disorders or continued malocclusion despite orthodontic efforts.

Additionally, **extremely crowded dentitions** sometimes encountered in pediatric patients may indicate underlying skeletal issues requiring surgical intervention before conventional braces can achieve optimal results efficiently and comfortably. In these complex scenarios, creating additional space through osteotomy—cutting and reshaping bone—can facilitate better tooth alignment without excessive force on already stressed dental structures. This strategic approach allows young patients to undergo effective

orthodontics tailored to their unique anatomical needs without compromising comfort or longevity of results.

As we navigate through these considerations surrounding oral surgery's role in treating complex alignment cases among pediatric patients, it's clear that each child's situation is as unique as their smile. The decision-making process involves a multidisciplinary team including pediatric dentists, orthodontists, and oral surgeons collaboratively assessing each case's intricacies to determine when—and how—oral surgery can serve as an integral stepping stone toward restorative dental care. By addressing these challenging conditions early on with informed interventions tailored specifically for growing mouths and faces, we pave the way for healthier smiles that last a lifetime, providing children not just with beautiful grins but with confidence rooted deeply in their overall well-being.

****Preventive Measures**

Against Tooth Wear:**

Properly aligned teeth are less prone to excessive wear and tear; adults may pursue

orthodontic treatment to prevent premature tooth degradation and associated costs of restorative dentistry.

The intersection of oral surgery and orthodontics represents a fascinating and crucial realm in dental medicine, particularly when it comes to managing complex alignment cases. This synergy between the two disciplines is essential for achieving optimal outcomes in patients who face intricate dental challenges that go beyond the scope of traditional orthodontic treatments. To appreciate the role of oral surgery in these scenarios, let's delve into the nuances that define complex alignment cases and how surgical intervention can transform treatment possibilities.

Complex alignment cases often involve conditions like severe malocclusions, skeletal discrepancies, or anomalies such as impacted teeth, where standard orthodontic appliances—braces, aligners—fall short. These situations might stem from genetic factors, developmental issues, or traumatic events affecting facial and dental structures. For instance, a patient might present with a significant overbite coupled with a jaw misalignment that not only affects aesthetics but also oral function and health. Here's where the expertise of both an orthodontist and an oral surgeon becomes indispensable.

Traditionally, orthodontists work wonders with braces and aligners to adjust tooth positions within the existing bone structure. However, when bone remodeling is required—such as when repositioning the jaw for better alignment—or when there's a need to correct structural imbalances that impede proper tooth alignment, oral surgery steps into the picture. Oral surgeons specialize in procedures like orthognathic surgery (jaw surgery), which can reposition the jaws to achieve balance and harmony between teeth and bite. This isn't just about aesthetics; it's fundamentally about restoring proper function—chewing, speaking, breathing—and enhancing overall quality of life for patients who suffer from these conditions.

Moreover, complex cases sometimes involve extraction of teeth to create space for proper alignment or to facilitate surgical movement of teeth or jaws. Here again, the collaboration between an orthodontist planning tooth movement and an oral surgeon executing precise extractions or bone grafts illustrates the seamless integration necessary for successful outcomes. These coordinated efforts ensure not only cosmetic improvements but also vital functional benefits that underscore the importance of treating dental issues holistically rather than compartmentally.

Additionally, advancements in technology have significantly enhanced our ability to plan and execute these intricate procedures with greater precision than ever before. Tools like 3D imaging and computer-aided design (CAD) allow for meticulous preoperative planning, enabling surgeons and orthodontists to visualize outcomes and tailor treatments uniquely suited to individual patient needs. This level of customization ensures that interventions are not just effective but also minimally invasive where possible, promoting faster recovery times and reducing complications.

In conclusion, the intersection of oral surgery and orthodontics in tackling complex alignment cases exemplifies a multidisciplinary approach at its finest within dentistry. By combining specialized knowledge—one focused on tooth positioning through non-surgical means, the other on skeletal restructuring through surgical intervention—these

professionals offer hope and tangible improvements to patients grappling with severe dental challenges. As technology continues to evolve alongside growing understanding of craniofacial anatomy and biomechanics, we can anticipate even more sophisticated methods emerging at this critical junction between oral surgery and orthodontics—a promising horizon for enhancing both form and function in dental care.

****Facilitating Better Chewing Efficiency**
: Orthodontic treatment can improve bite function and alignment, allowing for more efficient chewing which is crucial for digestion and overall**

nutritional health in adulthood.

When we talk about orthodontic treatment, many of us picture braces or clear aligners, tools that gently coax our teeth into a straighter, more aesthetically pleasing alignment. It's a common pathway for those seeking to improve their smile or correct minor misalignments. However, the world of dental and oral health is far more complex, especially when dealing with cases that don't respond fully to orthodontic interventions alone. This is where the role of oral surgery becomes critically important, stepping in to fill the gaps when orthodontics can't handle the challenge on its own.

Orthodontic treatment is marvelous for addressing issues like overcrowded teeth, mild to moderate spacing, and certain bite discrepancies. It works by applying controlled forces over time to move teeth into better positions within the jawbone. However, there are scenarios where the bones of the jaw itself pose significant obstacles to achieving optimal alignment and function through orthodontics alone. These cases often involve structural issues that require a more invasive approach—enter oral surgery.

One primary instance where orthodontics meets its limits is in cases of severe skeletal discrepancies. For example, individuals with a pronounced overbite or underbite might have jaws that are either positioned too far forward or too far back relative to each other. Orthodontics can help adjust the positioning of individual teeth but cannot fundamentally change the size or position of the jawbones themselves. In such situations, surgical

procedures like maxillary osteotomy (for correcting an overbite by moving the upper jaw forward) or mandibular osteotomy (to reposition a recessed lower jaw) become essential components of treatment. These surgeries reshape and reposition the bone to create a harmonious relationship between the upper and lower jaws, something braces simply cannot accomplish.

Another critical area where oral surgery complements orthodontics is in cases involving impacted teeth—most notably wisdom teeth—but also other permanent teeth that fail to emerge properly due to crowding or anatomical obstructions within the jawbone. While orthodontics can sometimes create space for these teeth to erupt normally, in many instances, especially when there's insufficient space due to bone structure limitations, surgical extraction of obstructing bone or even surgical exposure and bonding of brackets on impacted teeth might be necessary for successful integration into the dental arch.

Furthermore, patients with cleft palate or other congenital anomalies affecting facial and jaw development often require a multidisciplinary approach combining orthodontics with various forms of oral and maxillofacial surgery. These complex conditions demand precise interventions at different stages of growth and development to ensure proper function and aesthetics. Here again, while braces play a supportive role in tooth alignment post-surgery, it's often the surgical correction that lays the foundational framework for subsequent orthodontic refinement.

In summary, while orthodontic treatment is an invaluable tool in correcting many alignment issues, there are definite limits to its effectiveness when faced with substantial skeletal imbalances or structural barriers within the jawbone itself. Oral surgery emerges as an indispensable ally in these complex alignment cases—an essential partner that allows for comprehensive treatment outcomes beyond what orthodontics alone can achieve. Together, these disciplines weave a tapestry of care tailored not just to straighten teeth but also to craft functional smiles that endure through a lifetime of use and wear.

The importance of interdisciplinary approaches in treating complex cases, particularly within the realm of oral surgery and complex alignment cases, underscores a pivotal shift in modern healthcare towards collaborative and comprehensive patient care. This approach recognizes that complex dental and orthodontic issues often transcend the scope of single-specialty treatment, necessitating a synergistic blend of expertise from various disciplines to achieve optimal outcomes.

Complex alignment cases, which might involve not just misaligned teeth but also underlying skeletal discrepancies, periodontal concerns, or even systemic health issues impacting oral health, demand a multifaceted treatment strategy. Here's where the beauty of interdisciplinary collaboration comes into play. By integrating the specialized knowledge of orthodontists, oral surgeons, periodontists, prosthodontists, and sometimes even general practitioners or specialists like endodontists and pediatric dentists, we can craft a treatment plan that addresses all facets of a patient's condition.

Take, for instance, a patient presenting with severe malocclusion coupled with temporomandibular joint (TMJ) dysfunction and significant bone loss requiring grafting before any orthodontic intervention can be safely considered. An interdisciplinary team would assess these issues collectively—an orthodontist focusing on tooth positioning, an oral surgeon ready to tackle the skeletal and bone grafting needs, and perhaps a periodontist to ensure gum health is optimized for both immediate and long-term success. This collaborative effort ensures no stone is left unturned in addressing the complexity of the case.

Moreover, interdisciplinary approaches foster innovation in treatment methodologies. When professionals from different backgrounds come together to discuss a case, they bring unique perspectives that can lead to novel solutions or modifications in existing techniques. This cross-pollination of ideas can enhance treatment efficacy and patient comfort levels significantly. For example insights from biomechanical engineering might

influence how implants are designed for better osseointegration in complex scenarios, while advances in digital technology shared across disciplines can streamline diagnosis and treatment planning processes.

Equally crucial is the impact on patient experience and outcomes. Complex cases often require prolonged treatments with multiple stages; an interdisciplinary team can provide continuous care coordination ensuring each phase seamlessly transitions to the next without overlooking critical details. This holistic approach not only improves clinical results but also fosters greater patient trust and satisfaction as individuals navigate what might otherwise feel like an overwhelming journey through various medical landscapes.

In conclusion, embracing interdisciplinary approaches within oral surgery for complex alignment cases represents more than just a trend; it reflects an evolution towards empathetic, effective healthcare delivery tailored to individual needs. By harnessing diverse expertise collaboratively, we elevate standard care protocols into customized solutions that address not just the immediate dental concerns but contribute significantly to overall well-being—a testament to the profound significance of teamwork in achieving superior health outcomes in today's intricate medical environment.

When we delve into the intricate world of pediatric orthodontics, particularly focusing on cases that demand a complex approach to alignment, it becomes evident that oral surgery often plays a pivotal role. The journey from misaligned teeth to a harmonious bite involves not just the meticulous application of braces and aligners but sometimes the skilled hand of an oral surgeon. Let's unpack the indicators that signal when oral surgery might be necessary in these complex alignment cases, highlighting its indispensable role in achieving optimal outcomes for young patients.

One primary indication for considering oral surgery in pediatric orthodontics arises from **skeletal discrepancies**. These discrepancies refer to significant imbalances in the growth

patterns of the upper and lower jaws. For instance, when a child exhibits severe overbite or underbite—where the upper jaw is significantly forward or backward relative to the lower jaw—orthodontic treatment alone may not suffice. In such scenarios, surgical procedures like orthognathic surgery can realign the jaws to ensure proper function and aesthetics. This isn't merely about straightening teeth; it's about ensuring that the jaws fit together correctly, facilitating normal speech, chewing, and long-term stability of the bite.

Another critical indicator is **impacted teeth**, particularly third molars or even other permanent teeth that fail to erupt properly due to lack of space or improper positioning within the jawbone. While extraction might be an immediate solution for impacted wisdom teeth, other impacted permanent teeth may require surgical exposure and orthodontic traction for successful alignment. This combined approach ensures these teeth emerge correctly and contribute positively to the overall dental arch harmony.

Crowding is another common issue where oral surgery might complement orthodontic efforts. In cases where there's simply not enough space in the jaw for all permanent teeth to align properly, surgical options like alveolar bone expansion can create additional room. This procedure can be a game-changer for patients struggling with severe crowding where traditional orthodontic methods fall short. It allows for better alignment and reduces future complications like tooth decay and gum disease by ensuring each tooth has its appropriate space within the mouth.

Additionally, **cleft lip and palate conditions** often necessitate a multidisciplinary approach inclusive of oral surgery alongside orthodontic care. These congenital anomalies require precise intervention not only for aesthetic reasons but crucially for functional purposes such as speech development, eating, and breathing. Oral surgeons work hand-in-hand with orthodontists to address bone grafting needs and facilitate proper alignment within these complex cases, contributing significantly to improving both form and function for affected children.

Lastly, **traumatic injuries** affecting facial bones or can also lead to scenarios requiring oral surgical intervention post-treatment stabilization through orthodontics cannot fully resolve skeletal disharmonies or tooth positioning issues caused by trauma. Here again, timely surgical correction becomes vital in restoring both functionality and appearance—a critical aspect during formative years when self-esteem tied closely to physical appearance is under development.

In summary, while orthodontics stands as a cornerstone in correcting tooth alignment issues in pediatrics, its efficacy often hinges on timely integration with oral surgery when faced with skeletal discrepancies, impacted teeth, severe crowding incapable of resolution through braces alone, congenital conditions like cleft lip and palate, or traumatic injuries affecting dental occlusion and facial harmony. These complex alignment cases underscore how intertwined these disciplines are; together they

The Role of Oral Surgery in Complex Alignment Cases: Navigating the Path to a Healthier Smile

When we think about orthodontic treatment, many of us picture braces or clear aligners subtly shifting teeth into better positions over time. However, for some individuals, the journey to achieving a healthy, functional bite and an aesthetically pleasing smile is far more complex. This is where the specialized realm of oral surgery intertwines with orthodontics, offering solutions for specific scenarios that require a more hands-on approach. Let's delve into these critical situations—severe crowding, impacted teeth among them—to appreciate the essential role oral surgery plays in complex alignment cases.

Severe Crowding: When There's Simply Not Enough Space

Imagine a scenario where someone's jaw is too small to accommodate all their teeth properly. This condition, known as severe crowding, can lead to overlapping teeth, misalignment, and an increased risk of dental issues like decay and gum disease due to the challenging hygiene conditions such crowded spaces create. In these cases, orthodontic treatment alone might not suffice; this is where oral surgery steps in. Procedures like tooth extraction or even orthognathic surgery—often referred to as jaw surgery—may become necessary. By strategically removing certain teeth or altering the jawbone structure, space can be created or redefined to allow for proper alignment through subsequent orthodontic treatment. It's a harmonious collaboration between extracting problematic teeth and realigning what remains or will be aligned afterward for optimal function and aesthetics.

Impacted Teeth: The Hidden Challenge Beneath the Gums

Another common scenario demanding surgical intervention involves impacted teeth, particularly third molars—or wisdom teeth—that fail to emerge properly due to obstruction by bone or other teeth. While not every impacted tooth necessitates removal, those that are positioned in a way that they cannot erupt without causing damage to adjacent structures or leading to infection often require extraction. This is crucial because impacted wisdom teeth can lead to pain, swelling, cysts, and even damage to neighboring teeth and bone if left untreated. Oral surgeons expertly navigate these delicate extractions under careful planning and imaging guidance, ensuring minimal discomfort and swift recovery while preventing future complications that could derail overall oral health and alignment goals.

The Synergy Between Orthodontics and Oral Surgery

It's essential to recognize that while orthodontics deals primarily with the straightening of teeth using appliances like braces and aligners, oral surgery addresses structural issues within the mouth that impede optimal alignment and function—issues that sometimes cannot be resolved through orthodontics alone. Together, these disciplines offer comprehensive solutions tailored specifically to each patient's needs. For instance, after orthognathic surgery repositions the jaw bones for better function and aesthetics, extensive orthodontic treatment may follow to fine-tune tooth alignment within this new framework. This synergy ensures not just straighter teeth but also improved bite functionality—and ultimately—a healthier mouth environment conducive to long-term well-being.

In conclusion, the role of oral surgery in addressing complex alignment cases extends beyond mere correction; it embodies a transformative approach towards achieving balanced oral health where every element—the bones supporting our teeth, the gums surrounding them, and the teeth themselves—works in concert for optimal function and appearance. Whether it's overcoming severe crowding through strategic extractions or addressing hidden challenges like impacted teeth with precision surgeries, these interventions

The Role of Oral Surgery in Creating Space for Proper Tooth Alignment: A Crucial Aspect in Complex Alignment Cases

When we think about straightening teeth, many of us envision the more common methods like braces or aligners, which gradually shift teeth into their desired positions over time. However, for those grappling with complex alignment issues, the journey often requires a more nuanced and sometimes surgical approach. This is where oral surgery steps into the spotlight, playing an indispensable role in crafting the necessary space for proper tooth alignment. Let's delve into how this intricate branch of dentistry transforms challenging cases into manageable ones, paving the way for beautiful smiles and improved oral health.

To begin with, it's essential to understand that not all orthodontic challenges are created equal. Some individuals may face conditions where there simply isn't enough space in the jaw for all teeth to align correctly. This could stem from a variety of factors including genetics, early loss of baby teeth, or even accidents that have altered the jaw structure. In these complex scenarios, merely applying pressure through braces might not be sufficient; instead, creating additional space becomes paramount. Here's where oral surgery can truly shine.

One common procedure utilized is called "orthognathic surgery," often referred to as jaw surgery. This involves repositioning the jaws to achieve better alignment and functionality. For someone with a severe overbite or underbite—conditions where the upper and lower jaws don't meet correctly—this surgery can be transformative. By carefully cutting and repositioning bone segments, surgeons can create the extra room needed for teeth to align properly while also improving bite function and facial aesthetics.

Another scenario where oral surgery plays a critical role is in addressing impacted teeth, particularly wisdom teeth or other posterior teeth that don't have enough space to emerge correctly. When these teeth are trapped beneath gums or bone—impacting—not only alignment but also overall oral health can be compromised due to potential crowding or infection risks. Oral surgeons expertly extract these problematic teeth or sometimes reposition them if feasible, thereby clearing pathways for other teeth to align without obstruction.

The process leading up to such surgeries is meticulous and collaborative. Orthodontists often work hand-in-hand with oral surgeons to plan treatments meticulously using advanced imaging techniques like CT scans to visualize bone structures accurately. Together they determine when surgery might be beneficial and how it complements orthodontic treatment plans involving braces or clear aligners post-surgery. This teamwork ensures a smooth transition from surgical correction to finishing touches with

orthodontics aimed at fine-tuning tooth alignment post-procedure.

Moreover, advancements in technology continue to refine these processes making them safer and more effective than ever before. From computer-guided surgeries ensuring precise bone cuts and placement to innovative implants that help stabilize newly positioned jaws during healing phases—the field is evolving rapidly, enhancing outcomes significantly for patients facing complex alignment challenges.

In conclusion, while braces remain a cornerstone of orthodontic treatment for many, they are just one piece of a larger puzzle when it comes to complex tooth alignment cases. Oral surgery emerges as an invaluable tool—capable of creating essential space where none seemed available before—and plays a pivotal role in achieving not just straighter teeth but also balanced bites and healthier mouths overall. It's through this combination of expertise from both orthodontists and oral surgeons that patients facing daunting dental challenges find renewed hope

When we delve into the intricate world of orthodontics and oral surgery, particularly in the context of complex alignment cases, the pre-surgical considerations and planning phase emerges as a critical cornerstone. This stage is not merely about preparing for the operation; it's a comprehensive process that lays the groundwork for successful outcomes, ensuring that every step taken leads harmoniously to the desired alignment and functionality of the patient's dentition and oral structures.

Firstly, understanding the patient's unique situation is paramount. This involves a thorough examination that goes beyond just looking at tooth alignment. It includes a detailed analysis of dental records, radiographs like panoramic X-rays and cone-beam computed tomography (CBCT) scans, which provide three-dimensional views essential for complex cases. These images reveal not only the position of teeth but also the underlying bone structure, potential anomalies, and any existing pathologies that could influence surgical

planning.

In addition to imaging, a comprehensive medical history is crucial. This includes reviewing any systemic conditions—like diabetes or heart disease—that could affect healing or increase surgical risks. Allergies to medications or materials used in surgery must also be considered to tailor an individualized treatment plan that prioritizes safety and efficacy. Furthermore, discussing previous dental treatments and orthodontic history provides insights into how the teeth have responded to earlier interventions, guiding future strategies.

Another pivotal aspect is setting realistic expectations with the patient. Complex alignment cases often involve multiple stages of treatment, including pre-surgical orthodontics to prepare the teeth and jaws for optimal surgical results. Communicating these steps clearly helps manage expectations regarding timelines, potential discomfort post-surgery, and the necessity for postoperative orthodontic work to fine-tune alignments once surgery has reshaped the jawbone architecture.

Planning also involves considering various surgical options tailored to individual needs. For instance, in cases requiring jaw realignment (orthognathic surgery), precise calculations are made using advanced software simulations to predict outcomes accurately and minimize risks associated with moving bones in the intricate landscape of facial anatomy. Similarly, when dealing with impacted teeth or those requiring extraction prior to alignment, careful planning ensures minimal disruption to surrounding tissues while achieving optimal positioning for future prosthetic work if needed.

Moreover, interdisciplinary collaboration plays a significant role in this phase. Working closely with orthodontists allows for coordinated approaches where tooth movement can be synergistically aligned with skeletal changes achieved through surgery. Such teamwork

ensures continuity from pre-surgical planning through post-operative care, optimizing both aesthetic and functional outcomes for patients undergoing complex alignment procedures.

In essence, pre-surgical considerations and planning in complex alignment cases encapsulate an exhaustive blend of diagnostic precision, medical awareness, patient communication, and collaborative teamwork. It's an intricate dance of preparation aimed at not just correcting misalignments but ensuring overall oral health.

When delving into the intricate world of complex alignment cases, particularly within the realm of orthodontics and oral surgery, understanding the assessment tools and techniques for evaluating the need for surgery becomes paramount. This evaluation is not merely a procedural formality; it's a critical step that bridges diagnostic insight with therapeutic strategy, ensuring that patients receive care tailored to their unique dental and skeletal challenges.

In assessing whether oral surgery is necessary for complex alignment cases, clinicians employ a multifaceted approach that combines traditional methods with cutting-edge technology. The journey typically begins with a comprehensive clinical examination, where the orthodontist or oral surgeon meticulously evaluates the patient's dental occlusion, jaw relationships, and facial aesthetics. This hands-on approach allows for the identification of anomalies such as malocclusions, skeletal discrepancies, or soft tissue imbalances that might necessitate surgical intervention alongside orthodontic treatment.

Beyond physical examination, advanced imaging techniques play a crucial role in this decision-making process. Cone Beam Computed Tomography (CBCT), for instance, offers high-resolution 3D images of teeth, bones, and surrounding structures with minimal radiation exposure compared to traditional CT scans. These detailed visuals are invaluable when planning surgeries like osteotomies or assessing bone density and volume—factors

critical for successful surgical outcomes in complex alignment cases. Additionally, digital models and intraoral scanners provide accurate representations of the patient's dentition and jaw structure, facilitating precise preoperative planning and simulation of potential surgical movements.

Another significant tool in this evaluation is cephalometric analysis—a method using X-ray images to assess skull growth and tooth positioning relative to each other and the cranial base. By applying various cephalometric analyses, practitioners can predict how surgically altering jaw positions might improve occlusion and facial harmony. Moreover, utilizing computer-aided design/computer-aided manufacturing (CAD/CAM) technologies allows for virtual simulations of surgical procedures on these digital models before any physical intervention occurs—a step that significantly enhances precision and minimizes risks associated with surgery.

Furthermore, patient-specific factors such as age, overall health status, and personal expectations cannot be overlooked during this assessment phase. For instance, growing patients may require different considerations than adults due to ongoing craniofacial development possibilities. Similarly, systemic conditions could impact healing post-surgery or influence treatment choices altogether. Engaging patients in informed discussions about their goals—be it functional improvement or aesthetic enhancement—ensures that their desires align with what can realistically be achieved through combined orthodontic-surgical means.

In conclusion, evaluating the need for surgery in complex alignment cases involves a delicate balance of traditional clinical acumen enhanced by modern technological advancements. From initial examinations to sophisticated imaging techniques like CBCT coupled with advanced analytical tools such as CAD/CAM simulations, every step aims to provide an exhaustive understanding of each case's intricacies. Ultimately, it's this holistic approach that ensures patients embark on their journey to improved oral health and

aesthetics armed with confidence—and a treatment plan precisely suited to their unique needs.

The intricate world of orthodontics and oral surgery often intersects in the treatment of complex alignment cases, a juncture where collaboration between orthodontists and oral surgeons becomes not just beneficial, but essential. This partnership is pivotal in addressing the multifaceted challenges presented by severely misaligned teeth, jaw discrepancies, and other anatomical complexities that cannot be effectively managed by one discipline alone. The role of oral surgery in these scenarios transcends mere procedural necessity; it embodies a synergistic approach to patient care that leverages the unique expertise of both specialties to achieve optimal outcomes.

Complex alignment cases often involve more than just the straightening of teeth; they can encompass significant skeletal discrepancies that require precise surgical intervention to correct. Here, the orthodontist's role is crucial in preparing the dentition for surgery and ensuring proper alignment post-operatively. However, without the strategic planning and execution provided by an oral surgeon, achieving harmonious function and aesthetics can be a distant dream. Oral surgeons bring to the table their specialized skills in bone manipulation, tooth extraction when necessary, and the correction of jaw positions—all vital components in transforming complex malocclusions into balanced smiles.

The collaborative planning process begins with comprehensive diagnostic assessments where both professionals contribute their insights. Orthodontists offer detailed analyses of tooth positioning and occlusion, while oral surgeons provide perspectives on skeletal relationships and potential surgical modifications needed. Together, they map out a treatment plan that seamlessly integrates orthodontic appliances with surgical interventions at opportune moments. This joint strategy ensures that each phase complements the other, minimizing complications and maximizing efficiency towards restoring dental health and functionality.

Moreover, this collaborative approach significantly enhances patient outcomes by providing continuity of care from pre-operative planning through post-operative adjustments. Patients benefit from a unified vision among their healthcare providers, which fosters trust and understanding throughout their treatment journey. Oral surgeons can address immediate surgical needs while orthodontists orchestrate the gradual movement of teeth into their ideal positions over time—a dance of timing and precision that demands close coordination between these specialists.

Furthermore, advancing technologies such as 3D imaging, virtual simulations, and customized surgical guides have revolutionized how these professionals collaborate. These tools allow for meticulous pre-surgical planning where every angle is considered before making an incision or applying force to bone or teeth. Such technological integration not only improves accuracy but also opens new avenues for personalized treatment strategies tailored specifically to each patient's unique condition.

In conclusion, the role of oral surgery in complex alignment cases underscores a narrative deeply rooted in collaboration between orthodontists and oral surgeons—a narrative where mutual respect for each other's expertise leads to exceptional patient care outcomes. Through shared knowledge, combined efforts during planning stages, synchronized execution of treatments, and ongoing communication post-surgery, these practitioners exemplify what true interdisciplinary cooperation looks like in modern dentistry. As we continue to embrace technological advancements alongside this collaborative spirit, patients facing complex dental challenges will undoubtedly benefit from more effective solutions tailored precisely to their needs—a testament to what can be achieved when disciplines unite for a common goal: restoring health and confidence through beautiful smiles crafted with care at every step.

When delving into the realm of complex alignment cases in orthodontics, it's pivotal to recognize the indispensable role oral surgery plays in achieving optimal outcomes. This intersection of dental expertise and surgical precision is often the key that unlocks

harmony within a patient's bite and smile. Let's explore some of the commonly used oral surgical procedures that are pivotal in addressing these complex scenarios.

First off, **orthognathic surgery** stands out as a cornerstone procedure for patients with significant skeletal discrepancies. This type of surgery addresses issues where the jaws do not align properly, impacting both function and aesthetics. Whether it's correcting an overbite, underbite, or protruding jaw, orthognathic surgery works in tandem with orthodontic treatment to realign the jaws and teeth for improved function and a more balanced appearance. The procedure typically involves cutting and repositioning the jawbone(s), which then heal in their new positions, often requiring braces or other orthodontic appliances before and after surgery to ensure precise alignment.

Another crucial procedure is **dental implant surgery**, especially relevant in cases where one or more teeth need replacement due to extraction, trauma, or congenital absence. In complex alignment situations, implants can serve not just as replacements for missing teeth but also play a role in stabilizing the jaw structure and improving overall bite alignment. This surgical process involves placing titanium posts directly into the jawbone, which then integrate with the bone through osseointegration—a biological process that anchors the implant securely—before being crowned with artificial teeth.

Genioplasty is another notable surgical option often considered in complex alignment cases. This procedure focuses on modifying the chin's shape or position to enhance facial symmetry and balance. While primarily aesthetic, genioplasty can significantly impact functional outcomes by altering facial profiles and contributing to better bite alignment when integrated with other surgical or orthodontic treatments.

Lastly, **bone grafting** emerges as a foundational procedure in many oral surgeries related to complex alignments. It's particularly essential when there's insufficient bone density or

volume to support implants or facilitate certain types of orthognathic surgery effectively. Bone grafting involves transplanting bone tissue from another area of the body or using synthetic materials to build up deficient areas of the jawbone, thereby providing a stable foundation for future dental work or structural corrections necessary for proper alignment.

In weaving these procedures together within the context of complex alignment cases, it becomes evident how oral surgery transcends mere procedural necessity; it embodies an artful blend of science and skill aimed at transforming lives through improved function and aesthetics. Each procedure discussed here serves not only its specific purpose but also contributes toward achieving a harmonious balance between form and function—a goal that resonates deeply with patients seeking comprehensive solutions for their dental health challenges.

The journey through these surgeries requires careful planning involving multidisciplinary teams consisting of orthodontists, oral surgeons, and sometimes other specialists like periodontists or prosthodontists. The synergy among these professionals ensures that every angle is considered—from pre-surgical assessments and imaging to postoperative care—to achieve enduring results that resonate positively in patients' lives.

In conclusion, recognizing the role of these oral surgical procedures highlights how integral they are in managing complex alignment cases beyond traditional orthodontic methods alone can achieve. Each intervention plays its part in crafting personalized treatment plans tailored to individual needs—a testament to modern dentistry's commitment to

The role of oral surgery in complex alignment cases is a nuanced and critical component of achieving optimal dental health and aesthetics, particularly when standard orthodontic treatments fall short. To fully appreciate this, let's delve into the procedures that often come to the forefront: tooth extraction, alveolar bone grafting, and dental implants, each

playing a pivotal role in crafting a harmonious smile.

To begin with, tooth extraction might seem like a drastic measure, but in complex alignment scenarios, it can be an essential step toward achieving proper occlusion and spacing. When teeth are severely misaligned, overcrowded, or impacted—like wisdom teeth that refuse to emerge correctly—they can impede the progress of orthodontic treatments aimed at straightening remaining teeth. Extracting these problematic teeth clears the way for the teeth that need to move into position, ensuring that they have enough room to align effectively without undue pressure or interference. This preliminary surgical intervention is often crucial for setting the stage for successful orthodontic treatment down the line.

Following extraction, if significant bone loss has occurred due to prolonged misalignment or other factors, alveolar bone grafting may be necessary. The alveolar bone is the part of the jawbone that supports our teeth; when it's compromised, it can lead to unstable foundations for both natural teeth and future dental implants. Bone grafting involves taking bone material—often from another part of the body or sourced synthetically—and transplanting it into the deficient area within the jawbone. Over time, this graft integrates with the existing bone structure, restoring its strength and density. This procedure not only supports current dental work but also prepares the jaw for future implant placements by ensuring there's adequate bone volume and quality—a critical factor for long-term success and stability of dental implants.

Speaking of implants, they represent a remarkable advancement in oral surgery and prosthodontics for complex alignment cases. Dental implants serve as artificial tooth roots made typically from titanium that are surgically inserted into the jawbone to support replacement teeth such as crowns or bridges. Unlike removable dentures or traditional bridges which rely on adjacent teeth for support, implants integrate directly with bone tissue through a process called osseointegration. This biological bonding

provides unparalleled stability and durability for prosthetic teeth. In complex alignment scenarios where several teeth need replacement or stabilization post-extraction or due to congenital anomalies, implants offer both functional restoration and aesthetic improvement without compromising surrounding healthy tissues or necessitating alterations to adjacent natural teeth—a stark contrast to conventional methods.

In summary, oral surgery plays an indispensable role in navigating complex alignment cases beyond what basic orthodontics can achieve alone. Through thoughtfully executed procedures like tooth extraction to create space, alveolar bone grafting to rebuild support structures where needed, and dental implant placement for stable and lasting solutions—oral surgeons collaborate with orthodontists to deliver comprehensive care tailored to each patient's unique challenges. These combined efforts ensure not just a straight smile but one that's healthy, functional, and beautiful—truly embodying what modern dentistry strives towards in addressing intricate alignment issues with precision and care.

The Role of Oral Surgery in Complex Alignment Cases: Weighing Benefits Against Risks in Pediatric Patients

When it comes to addressing complex alignment issues in children, the realm of oral surgery emerges as a critical yet nuanced area of pediatric dentistry and orthodontics. The decision to involve oral surgery in treating these cases is multifaceted, promising significant benefits but also carrying potential risks that necessitate careful consideration, especially given the developmental nature of pediatric patients. Let's delve into this intricate balance.

Benefits:

One of the most compelling advantages of oral surgery in complex alignment cases is its capacity to directly address structural issues that standard orthodontic treatments might not fully resolve. For instance, conditions like impacted teeth, severe crowding, or skeletal discrepancies can profoundly benefit from surgical intervention. Corrective jaw surgeries, for example, can realign the jaws to improve functionality and aesthetics, significantly enhancing a child's quality of life by boosting confidence and facilitating better speech and eating habits. Moreover, early intervention through oral surgery can sometimes simplify and shorten the overall treatment timeline when combined with orthodontic appliances, reducing the need for prolonged braces or other corrective measures.

Additionally, addressing alignment issues early on can prevent future complications such as tooth decay, gum disease, and even temporomandibular joint (TMJ) disorders. By ensuring proper occlusion and jaw alignment from a young age, oral surgery contributes to long-term oral health and reduces the likelihood of more invasive procedures later in life. This proactive approach is particularly beneficial considering children's remarkable capacity for healing and adaptation.

Potential Risks:

Despite these substantial benefits, it's crucial to acknowledge the risks inherently associated with any surgical procedure. Anesthesia, a necessary component of oral surgery, poses its own set of challenges in pediatric patients due to their smaller airway sizes and unique physiological responses. Ensuring patient safety during and after anesthesia administration requires meticulous planning and monitoring by an experienced team. Furthermore, as with any surgery, there's an inherent risk of complications such as infection, bleeding disorders, or adverse reactions to anesthesia that must be vigilantly managed.

Beyond immediate surgical risks lies the concern of growth interference. Children are still developing; thus surgical interventions must be carefully timed to avoid disrupting natural growth patterns inadvertently. Misjudgment here could lead to unforeseen consequences affecting facial development or requiring additional corrective measures down the line. Additionally, there's always a psychological aspect; children might experience anxiety about surgeries or dissatisfaction with outcomes if expectations aren't clearly communicated and managed by healthcare providers.

In conclusion, while oral surgery presents transformative benefits for children grappling with complex alignment cases—offering solutions that can enhance both function and aesthetics—it comes wrapped with responsibilities that require careful deliberation and expertise. Parents and healthcare providers must engage in thorough discussions weighing these benefits against potential risks to make informed decisions tailored specifically to each child's unique circumstances. With cautious optimism grounded in comprehensive care planning, oral surgery can pave the way toward healthier smiles and improved lives for young patients navigating challenging alignment issues.

Post-surgical orthodontic treatment strategies play a pivotal role in the realm of complex alignment cases, marking a significant intersection between oral surgery and orthodontics. This intricate dance between disciplines is crucial when dealing with patients whose dental issues extend beyond the scope of traditional orthodontic braces and retainers. The journey from surgical intervention to achieving a harmonious bite and aesthetic smile requires meticulous planning, precision, and a comprehensive understanding of both fields.

To set the stage, consider cases where orthodontic correction alone cannot achieve optimal results due to structural discrepancies in the jaw or severe malocclusions compounded by skeletal imbalances. Here's where oral surgery steps in as a powerful ally. Surgical procedures such as orthognathic surgery—aiming to correct jaw misalignments—or various bone grafting techniques can reshape the foundation upon which orthodontic

treatment will thrive. The goal is not merely to adjust tooth position but to ensure that teeth have a stable framework that supports their new alignment long-term.

The strategy post-surgery involves several key components, beginning with an intricate recovery phase. Patients require careful monitoring and management of pain, swelling, and healing processes, often involving medications and possibly dietary adjustments to facilitate proper recovery without compromising surgical sites. This initial period sets the groundwork for subsequent orthodontic adjustments.

Following stabilization post-surgery, the orthodontist takes over with a tailored treatment plan that leverages appliances—often including braces or clear aligners—to fine-tune tooth positioning. The complexity here lies in coordinating these forces with the new skeletal structure created by surgery. Orthodontists must navigate this delicate balance carefully to avoid undue stress on healing bones while achieving precise alignment goals.

Another critical element is patient compliance and communication. Given the extended duration these treatments often require—sometimes spanning several years—the relationship between dentist/orthodontist and patient becomes pivotal. Regular follow-ups are essential not just for monitoring progress but also for motivating patients through potential challenges they may encounter along their journey toward improved oral health and aesthetics.

Moreover, advancements in technology have enhanced post-surgical orthodontic strategies significantly. Tools like 3D imaging allow for precise preoperative planning, ensuring that surgical interventions are aligned with future orthodontic goals right from the outset. Virtual simulations can predict outcomes, allowing both surgeon and orthodontist to visualize potential results before any cutting or moving of teeth begins—a leap forward from traditional methods reliant on two-dimensional radiographs and

models.

Lastly, interdisciplinary collaboration remains at the heart of successful post-surgical orthodontic treatment strategies for complex alignment cases. Regular meetings between oral surgeons and orthodontists ensure seamless transitions from surgery to active orthodontic phases, adjusting plans as necessary based on healing progress or unforeseen complications that might arise during recovery or treatment stages.

In conclusion, post-surgical orthodontic treatment strategies represent a sophisticated blend of surgical expertise and meticulous dental care aimed at transforming complex alignment cases into success stories of restored function and beauty. It's a testament to how far we've come in understanding not just teeth but how they fit into our overall health narrative—a narrative increasingly written with precision tools, collaborative spirit, and patient-centered approaches at its core.

The intricate dance between orthodontics and oral surgery in the realm of complex alignment cases is a testament to the evolving sophistication within dental medicine. This synergy isn't merely about aesthetics; it's fundamentally about function, comfort, and long-term oral health. Understanding the sequence and timing of orthodontic treatment before, during, and after surgery reveals a carefully choreographed approach that can make all the difference for patients navigating these complex journeys.

Before Surgery: Setting the Stage

Pre-operatively, orthodontic treatment often plays a crucial preparatory role. The goal here is to optimize tooth positioning to facilitate surgical procedures and ensure the best possible outcome post-surgery. This phase might involve several months—or even years—of careful orthodontic planning and execution. For instance, if a patient requires jaw

surgery to correct a misalignment or improve bite functionality, orthodontists will work diligently to align teeth in a manner that supports the surgical objectives. This could include widening the dental arches, correcting overbites or overjets, or ensuring teeth are appropriately spaced for optimal results once the jaws are realigned. The use of appliances like braces or clear aligners becomes pivotal during this stage, allowing for precise control over tooth movement.

During Surgery: The Surgical Alignment

The surgical phase itself is where oral surgery truly takes center stage. Here, surgeons meticulously adjust the position of jaws, bones, or teeth to achieve structural balance and harmony within the patient's dentition and facial structure. In some cases, this might involve cutting and repositioning bone segments (orthognathic surgery), which necessitates an acute understanding of both surgical techniques and dental anatomy. While under anesthesia, patients' teeth may require minor adjustments to align perfectly with their new skeletal framework immediately post-surgery. This coordination ensures that once healing begins, teeth are in positions that complement the surgical alterations without needing extensive further adjustments later on.

After Surgery: Fine-Tuning for Perfection

Post-surgery marks another critical chapter where orthodontic treatment resumes with renewed focus—this time on fine-tuning and stabilization. After bones have healed around new positions (a process known as osseointegration), orthodontists take over again to refine tooth alignment and occlusion (how upper and lower teeth come together). This phase can involve additional braces or aligners tailored specifically to address any lingering discrepancies or to ensure comprehensive stability of the new skeletal arrangement. It's during this period that patients often experience significant

improvements in bite function and aesthetic outcomes, culminating in a smile that's not just visually appealing but also highly functional.

In essence, integrating orthodontics with oral surgery in complex alignment cases exemplifies modern dentistry's holistic approach—where each phase builds upon previous steps for an outcome that transcends mere cosmetic improvement. It underscores an understanding that true transformation comes from harmonizing form with function through meticulous planning, precise execution across different stages of treatment, and dedicated follow-up care post-surgery. Patients embarking on such comprehensive treatments are reminded that their journey towards enhanced oral health and confidence is supported by professionals who appreciate both the artistry and science involved in crafting beautiful smiles rooted in solid structural integrity.

The Role of Oral Surgery in Complex Alignment Cases: Emphasizing the Importance of Oral Hygiene and Follow-Up Care

When we delve into the intricate world of orthodontics, particularly in cases demanding the precision and expertise of oral surgery, it becomes clear that the journey to a perfect smile is as much about meticulous planning and execution as it is about the diligent care that follows. The importance of maintaining oral hygiene and adhering to post-surgery follow-up care cannot be overstated; these elements are pivotal not just for achieving desired aesthetic outcomes but also for ensuring the longevity and health of one's dental structure post-intervention.

To begin with, let's consider what complex alignment cases entail. These situations often require oral surgery to correct severe malocclusions, address issues like impacted teeth, or prepare the jaw for orthodontic appliances that will guide teeth into their proper positions. Such procedures, while transformative, introduce an element of vulnerability to the oral environment. The surgical sites become entry points for bacteria, increasing the

risk of infection if not properly managed. Herein lies the critical role of maintaining impeccable oral hygiene immediately following surgery.

Post-surgery, patients are often advised to adhere to a regimen that minimizes bacterial load in the mouth. This includes gentle brushing around surgical sites—taking care not to disrupt healing tissues—flossing carefully to avoid trauma to sensitive areas, and using antimicrobial mouth rinses as prescribed by dental professionals. These practices don't just prevent infections; they foster an environment conducive to healing, allowing tissues to regenerate smoothly without complications that could jeopardize the success of the alignment efforts.

Moreover, following up with healthcare providers is equally crucial in this journey. Regular check-ups allow dentists and oral surgeons to monitor progress closely, intervening swiftly should any signs of complications arise—be it delayed healing, infection, or issues related to appliance fit post-surgery. These follow-ups serve as a safety net, ensuring that any minor hiccups do not escalate into major setbacks that could alter treatment timelines or outcomes significantly. Additionally, these visits provide opportunities for adjustments in orthodontic appliances and continuous guidance on maintaining optimal oral hygiene tailored specifically to individual needs post-surgery.

Furthermore, adherence to follow-up care illustrates a patient's commitment to their overall treatment plan—a vital psychological aspect influencing recovery and satisfaction with results. Understanding that each appointment is a step towards achieving not just cosmetic improvements but enhanced functionality and comfort reinforces motivation during what can be a lengthy process fraught with challenges.

In conclusion, while orthognathic surgery opens doors to transformative alignment possibilities for those grappling with complex dental issues, its success hinges

significantly on diligent maintenance of oral hygiene and conscientious adherence to follow-up care protocols post-procedure. By embracing these responsibilities wholeheartedly, patients pave the way for successful outcomes—the realization of their smile goals coupled with preserved oral health—a testament to both modern medical advancements and personal dedication towards well-being.

When delving into the nuanced realm of oral surgery, particularly in the context of complex alignment cases, it's crucial to weave together the threads of long-term outcomes and patient considerations to fully appreciate the intricacies involved. Oral surgery in these scenarios isn't merely about straightening teeth or correcting bites; it's a multifaceted approach that demands a deep understanding of both the immediate dental concerns and the broader implications for a patient's overall health and quality of life.

Firstly, let's consider the **long-term outcomes** of oral surgery in complex alignment cases. The primary goal is often to achieve a stable, functional, and aesthetic result that enhances not just dental health but also facial harmony and self-confidence. However, achieving this isn't solely about the surgical techniques employed during the procedure. It's equally about anticipating potential complications and planning for maintenance post-surgery. For instance, patients may require ongoing orthodontic care to ensure teeth remain aligned as they heal and adjust over time. Moreover, factors like bone density and healing capacity can significantly influence long-term stability; hence, personalized treatment plans are paramount. The integration of advanced imaging technologies pre-operatively allows surgeons to meticulously plan procedures that optimize outcomes while minimizing risks—a cornerstone for success in complex cases.

Beyond these clinical considerations, **patient considerations** play an indispensable role. Each patient brings their unique set of challenges—physical, emotional, and psychological—that must be respectfully acknowledged and addressed. Pain management is a critical aspect; patients must feel supported throughout their healing journey with clear communication regarding what to expect post-surgery. Additionally, there's an emotional

dimension; undergoing oral surgery can be daunting, especially for those with complex needs who may have experienced previous disappointments or trauma related to dental care. Building trust through empathy and open dialogue fosters an environment where patients feel understood and motivated to adhere to post-operative instructions crucial for their recovery.

Moreover, understanding lifestyle factors is essential; dietary habits post-surgery might need adjustment temporarily, impacting nutrition and overall wellbeing during recovery periods. Oral hygiene practices also take on new importance as patients navigate healing phases to prevent infections—a factor oft underestimated but vital for successful outcomes.

Lastly, it's important to recognize that long-term success hinges not only on technical proficiency but also on establishing a collaborative relationship between healthcare providers and patients that extends beyond the operating room. Regular follow-ups are key; they allow for timely adjustments in treatment plans should any issues arise while reinforcing patient education about maintaining oral health over years to come. This comprehensive approach ensures that while immediate goals are met—correcting alignment issues—patients are equipped with knowledge and tools necessary for sustained oral health and satisfaction with their outcome.

In essence, navigating complex alignment cases through oral surgery requires a tapestry woven from technical expertise, personalized care strategies addressing both short-term surgical needs and long-term lifestyle adjustments, all underpinned by robust patient-provider relationships built on trust and mutual understanding. As we advance in this field, recognizing these elements will continue to enhance not just clinical success rates but also improve the holistic well-being of individuals seeking transformative dental solutions tailored uniquely to their needs.

The integration of orthodontic and surgical treatments in managing complex alignment cases represents a significant advancement in the field of dentistry, offering patients a pathway to not just improved aesthetics but also enhanced functionality and overall oral health. This combined approach is particularly crucial for individuals dealing with complex dental conditions that traditional orthodontic methods alone may struggle to address effectively. Let's delve into the expected results and benefits that such a comprehensive treatment strategy can deliver, highlighting its transformative impact on patient outcomes.

Firstly, one of the most apparent benefits of combining orthodontic and surgical treatments is the ability to correct severe malocclusions—misalignments of the teeth and jaws—that are too complex for braces or aligners to manage effectively on their own. For instance, cases involving significant overbites, underbites, or jaw discrepancies can benefit immensely from surgical intervention alongside orthodontics. Surgery can adjust the position of the jaw bones to achieve proper alignment, which when followed by orthodontic treatment, ensures that the teeth fit together correctly both functionally and esthetically. The result? A smile that's not only visually pleasing but also optimizes bite function, reducing risks associated with uneven wear on teeth and improving overall chewing efficiency.

Moreover, this integrated approach significantly enhances facial aesthetics. Complex cases often involve issues that go beyond mere tooth alignment; they can affect facial symmetry and proportion. Orthognathic surgery, precisely planned in conjunction with orthodontic treatment, can reshape the bones of the jaw to improve facial balance and harmony. Patients frequently report a boost in self-esteem and confidence following such transformative changes, underscoring the profound psychological benefits alongside physical improvements.

Another critical advantage lies in addressing functional issues that impact quality of life. Difficulties with speaking clearly, chewing food properly, or even breathing comfortably due to structural abnormalities in the jaw or alignment of teeth can be dramatically alleviated through this combined treatment method. By ensuring proper occlusion (how the upper and lower teeth come together) and correcting skeletal imbalances, patients experience a marked improvement in these functional aspects, contributing to better oral health and comfort in daily activities.

Additionally, there's an important long-term perspective to consider: maintaining stability post-treatment. While orthodontics alone might straighten teeth without addressing underlying skeletal discrepancies—which could lead to relapse—combining it with surgery provides a more stable foundation for lasting results. The structural changes made through surgery work in tandem with orthodontics to ensure that once aligned teeth remain so over time, minimizing or eliminating the need for future interventions.

In conclusion, integrating orthodontic treatments with oral surgery for complex alignment cases offers a holistic approach that addresses both functional and aesthetic concerns comprehensively. Patients stand to gain not just straighter teeth but also improved jaw function, enhanced facial aesthetics leading to greater self-confidence, and above all, a sustainable solution that supports long-term oral health and wellbeing. This synergistic method encapsulates the evolving nature of dental care—where precision science meets artistry—to deliver remarkable outcomes tailored specifically to each individual's unique needs.

The journey of children undergoing complex treatments, particularly within the realm of oral surgery for alignment cases, extends far beyond the clinical procedures themselves. It's a tapestry woven with threads of physical challenge, emotional resilience, and the crucial role that patient-centered care plays in shaping their experience. The psychological impact on these young patients is profound and multifaceted, making it imperative to approach their care with a holistic perspective that prioritizes their

emotional and psychological well-being alongside the physical treatment goals.

Complex alignment cases in orthodontics or oral surgery often necessitate extensive treatment periods, multiple procedures, and sometimes uncomfortable recovery phases. For children, who are already navigating the intricate landscape of growing up—socially, emotionally, and physically—these medical journeys can introduce unique stresses. Fear of the unknown, anxiety about pain or changes to their appearance, and disruptions to their daily life can all contribute to heightened levels of stress and anxiety. Moreover, the necessity for prolonged treatment can affect self-esteem and social interactions as children may feel different from their peers or face challenges in participating in normal activities.

Patient-centered care emerges as a beacon of hope amidst these challenges. At its core, this approach emphasizes understanding each child not just as a patient with a set of symptoms or conditions but as an individual with unique feelings, fears, and aspirations. It's about creating a supportive environment where children feel heard, understood, and involved in their care process. This involves clear communication from healthcare providers; explaining procedures in age-appropriate language fosters trust and reduces anxiety. Involving parents or guardians while respecting the child's autonomy encourages a sense of security and shared responsibility in facing medical challenges.


Moreover, integrating psychological support into the treatment plan is critical. Whether through counseling services tailored to address specific fears or anxieties related to treatment or simply by ensuring that healthcare environments are welcoming and child-friendly—incorporating play areas or distraction techniques during procedures—can significantly alleviate stress. Empathy from staff at every level contributes to an atmosphere where children feel valued beyond their medical condition; this nurturing environment can bolster their resilience and promote a more positive outlook on their treatment journey.

Additionally, recognizing the power of peer support cannot be understated. Facilitating connections with other children undergoing similar treatments creates a community where shared experiences foster friendship and mutual encouragement—a powerful antidote to feelings of isolation that complex treatments might impose.

In essence, patient-centered care transcends merely treating the physical aspects of complex alignment cases in pediatric oral surgery; it addresses the full spectrum of emotional needs that accompany such treatments. By placing empathy, clear communication, psychological support, and community at its heart, we empower children not just to endure their treatments but to navigate them with courage and optimism. This comprehensive approach ensures that while they conquer their physical challenges through expert surgical care, they also build psychological strength—a foundation vital for thriving both during their treatment journey and beyond into adulthood.

About child

"Children" and "Childhood" redirect here. For other uses, see Child (disambiguation), Children (disambiguation), and Childhood (disambiguation).

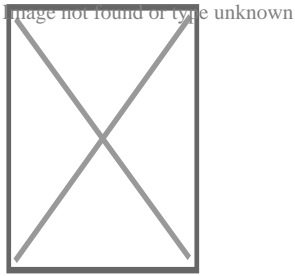


International children in traditional clothing at Liberty Weekend

- v
- t
- e

Part of a series on

Human growth and development



Stages

- Gamete
- Zygote
- Embryo
- Fetus
- Infant
- Toddler
- Child
- Preadolescent
- Adolescent
- Emerging and early adulthood
- Young adult
- Middle adult
- Old adult
- Dying


Biological milestones

- Fertilization
- Pregnancy
- Childbirth
- Walking
- Language acquisition
- Puberty
- Menopause
- Ageing
- Death

Development and psychology

- Pre- and perinatal
- Infant and child
- Nature versus nurture
- Adolescent
- Youth
- Young adult
- Adult
- Maturity

Developmental stage theories


- Attachment
- Ecological
- Psychosocial
- Psychosexual development
- Moral
- Cognitive
- Cultural-historical
- Evolutionary
-  Psychology portal

A **child** (pl. **children**) is a human being between the stages of birth and puberty,^{[1][2]} or between the developmental period of infancy and puberty.^[3] The term may also refer to an unborn human being.^{[4][5]} In English-speaking countries, the legal definition of *child* generally refers to a minor, in this case as a person younger than the local age of majority (there are exceptions like, for example, the consume and purchase of alcoholic beverage even after said age of majority^[6]), regardless of their physical, mental and sexual development as biological adults.^{[1][7][8]} Children generally have fewer rights and responsibilities than adults. They are generally classed as unable to make serious decisions.

Child may also describe a relationship with a parent (such as sons and daughters of any age)^[9] or, metaphorically, an authority figure, or signify group membership in a clan, tribe, or religion; it can also signify being strongly affected by a specific time, place, or circumstance, as in "a child of nature" or "a child of the Sixties."^[10]

Biological, legal and social definitions

[edit]



Children playing ball games, Roman artwork, 2nd century AD

In the biological sciences, a child is usually defined as a person between birth and puberty,^{[1][2]} or between the developmental period of infancy and puberty.^[3] Legally, the term *child* may refer to anyone below the age of majority or some other age limit.

The United Nations Convention on the Rights of the Child defines *child* as, "A human being below the age of 18 years unless under the law applicable to the child,

majority is attained earlier."^[11] This is ratified by 192 of 194 member countries. The term *child* may also refer to someone below another legally defined age limit unconnected to the age of majority. In Singapore, for example, a *child* is legally defined as someone under the age of 14 under the "Children and Young Persons Act" whereas the age of majority is 21.^[12]^[13] In U.S. Immigration Law, a child refers to anyone who is under the age of 21.^[14]

Some English definitions of the word *child* include the fetus (sometimes termed *the unborn*).^[15] In many cultures, a child is considered an adult after undergoing a rite of passage, which may or may not correspond to the time of puberty.

Children generally have fewer rights than adults and are classed as unable to make serious decisions, and legally must always be under the care of a responsible adult or child custody, whether their parents divorce or not.


Developmental stages of childhood

[edit]


Further information: Child development stages and Child development

Early childhood


[edit]



Children playing the violin in a group recital, Ithaca, New York, 2011



Children in Madagascar, 2011



Child playing piano, 1984

Early childhood follows the infancy stage and begins with toddlerhood when the child begins speaking or taking steps independently.^{[16][17]} While toddlerhood ends around age 3 when the child becomes less dependent on parental assistance for basic needs, early childhood continues approximately until the age of 5 or 6. However, according to the National Association for the Education of Young Children, early childhood also includes infancy. At this stage children are learning through observing, experimenting and communicating with others. Adults supervise and support the development process of the child, which then will lead to the child's autonomy. Also during this stage, a strong emotional bond is created between the child and the care providers. The children also start preschool and kindergarten at this age: and hence their social lives.

Middle childhood

[edit]

Middle childhood begins at around age 7, and ends at around age 9 or 10.^[18] Together, early and middle childhood are called formative years. In this middle period, children develop socially and mentally. They are at a stage where they make new friends and gain new skills, which will enable them to become more independent and enhance their individuality. During middle childhood, children enter the school years, where they are presented with a different setting than they are used to. This new setting creates new challenges and faces for children.^[19] Upon the entrance of school, mental disorders that would normally not be noticed come to light. Many of these disorders include: autism, dyslexia, dyscalculia, and ADHD.^[20] Special education, least restrictive environment, response to intervention and individualized education plans are all specialized plans to help children with disabilities.^[20]

Middle childhood is the time when children begin to understand responsibility and are beginning to be shaped by their peers and parents. Chores and more responsible decisions come at this time, as do social comparison and social play.^[20] During social play, children learn from and teach each other, often through observation.^[21]

Late childhood

[edit]

Main article: Preadolescence

Preadolescence is a stage of human development following early childhood and preceding adolescence. Preadolescence is commonly defined as ages 9–12, ending with the major onset of puberty, with markers such as menarche, spermarche, and the peak of height velocity occurring. These changes usually occur between ages 11 and 14. It may also be defined as the 2-year period before the major onset of puberty.^[22] Preadolescence can bring its own challenges and anxieties.


Preadolescent children have a different view of the world from younger children in many significant ways. Typically, theirs is a more realistic view of life than the intense, fantasy-oriented world of earliest childhood. Preadolescents have more mature, sensible, realistic thoughts and actions: 'the most "sensible" stage of development...the child is a much *less emotional being* now.'^[23] Preadolescents may well view human relationships differently (e.g. they may notice the flawed, human side of authority figures). Alongside that, they may begin to develop a sense of self-identity, and to have increased feelings of independence: 'may feel an individual, no longer "just one of the family."^[24]

Developmental stages post-childhood

[edit]

Adolescence

[edit]



An adolescent girl, photographed by Paolo Monti


Adolescence is usually determined to be between the onset of puberty and legal adulthood: mostly corresponding to the teenage years (13–19). However, puberty usually begins before the teenage years (10–11 for girls and 11–12 for boys). Although biologically a child is a human being between the stages of birth and puberty,^{[1][2]} adolescents are legally considered children, as they tend to lack adult rights and are still required to attend compulsory schooling in many cultures, though this varies. The onset of adolescence brings about various physical,

psychological and behavioral changes. The end of adolescence and the beginning of adulthood varies by country and by function, and even within a single nation-state or culture there may be different ages at which an individual is considered to be mature enough to be entrusted by society with certain tasks.

History

[edit]

Main article: History of childhood




Playing Children, by Song dynasty Chinese artist Su Hanchen, c. 1150 AD.

During the European Renaissance, artistic depictions of children increased dramatically, which did not have much effect on the social attitude toward children, however.^[25]


The French historian Philippe Ariès argued that during the 1600s, the concept of childhood began to emerge in Europe,^[26] however other historians like Nicholas Orme have challenged this view and argued that childhood has been seen as a separate stage since at least the medieval period.^[27] Adults saw children as separate beings, innocent and in need of protection and training by the adults

around them. The English philosopher John Locke was particularly influential in defining this new attitude towards children, especially with regard to his theory of the tabula rasa, which considered the mind at birth to be a "blank slate". A corollary of this doctrine was that the mind of the child was born blank, and that it was the duty of the parents to imbue the child with correct notions. During the early period of capitalism, the rise of a large, commercial middle class, mainly in the Protestant countries of the Dutch Republic and England, brought about a new family ideology centred around the upbringing of children. Puritanism stressed the importance of individual salvation and concern for the spiritual welfare of children.^[28]




The Age of Innocence c. 1785/8. Reynolds emphasized the natural grace of children in his paintings.

The modern notion of childhood with its own autonomy and goals began to emerge during the 18th-century Enlightenment and the Romantic period that followed it.^[29]^[30] Jean Jacques Rousseau formulated the romantic attitude towards children in his famous 1762 novel *Emile: or, On Education*. Building on the ideas of John Locke and other 17th-century thinkers, Jean-Jaques Rousseau described childhood as a brief period of sanctuary before people encounter the perils and hardships of adulthood.^[29] Sir Joshua Reynolds' extensive children portraiture demonstrated the new enlightened attitudes toward young children. His 1788 painting *The Age of Innocence* emphasizes the innocence and natural grace of the posing child and soon became a public favourite.^[31]



Brazilian princesses Leopoldina (left) and Isabel (center) with an unidentified friend, c. 1860.

The idea of childhood as a locus of divinity, purity, and innocence is further expounded upon in William Wordsworth's "Ode: Intimations of Immortality from Recollections of Early Childhood", the imagery of which he "fashioned from a complex mix of pastoral aesthetics, pantheistic views of divinity, and an idea of spiritual purity based on an Edenic notion of pastoral innocence infused with Neoplatonic notions of reincarnation".^[30] This Romantic conception of childhood, historian Margaret Reeves suggests, has a longer history than generally recognized, with its roots traceable to similarly imaginative constructions of childhood circulating, for example, in the neo-platonic poetry of seventeenth-century metaphysical poet Henry Vaughan (e.g., "The Retreat", 1650; "Childe-hood", 1655). Such views contrasted with the stridently didactic, Calvinist views of infant depravity.^[32]




Armenian scouts in 1918

With the onset of industrialisation in England in 1760, the divergence between high-minded romantic ideals of childhood and the reality of the growing magnitude of child exploitation in the workplace, became increasingly apparent. By the late 18th century, British children were specially employed in factories and mines and as chimney sweeps,^[33] often working long hours in dangerous jobs for low pay.^[34] As the century wore on, the contradiction between the conditions on the ground for poor children and the middle-class notion of childhood as a time of simplicity and innocence led to the first campaigns for the imposition of legal protection for children.


British reformers attacked child labor from the 1830s onward, bolstered by the horrific descriptions of London street life by Charles Dickens.^[35] The campaign eventually led to the Factory Acts, which mitigated the exploitation of children at the workplace^[33]^[36]

Modern concepts of childhood


[edit]




Children play in a fountain in a summer evening, Davis, California.



An old man and his granddaughter in Turkey.



Nepalese children playing with cats.



Harari girls in Ethiopia.

The modern attitude to children emerged by the late 19th century; the Victorian middle and upper classes emphasized the role of the family and the sanctity of the child – an attitude that has remained dominant in Western societies ever since.^[37]] The genre of children's literature took off, with a proliferation of humorous, child-oriented books attuned to the child's imagination. Lewis Carroll's fantasy *Alice's Adventures in Wonderland*, published in 1865 in England, was a landmark in the

genre; regarded as the first "English masterpiece written for children", its publication opened the "First Golden Age" of children's literature.

The latter half of the 19th century saw the introduction of compulsory state schooling of children across Europe, which decisively removed children from the workplace into schools.^{[38][39]}

The market economy of the 19th century enabled the concept of childhood as a time of fun, happiness, and imagination. Factory-made dolls and doll houses delighted the girls and organized sports and activities were played by the boys.^[40]] The Boy Scouts was founded by Sir Robert Baden-Powell in 1908,^{[41][42]} which provided young boys with outdoor activities aiming at developing character, citizenship, and personal fitness qualities.^[43]

In the 20th century, Philippe Ariès, a French historian specializing in medieval history, suggested that childhood was not a natural phenomenon, but a creation of society in his 1960 book *Centuries of Childhood*. In 1961 he published a study of paintings, gravestones, furniture, and school records, finding that before the 17th century, children were represented as mini-adults.

In 1966, the American philosopher George Boas published the book *The Cult of Childhood*. Since then, historians have increasingly researched childhood in past times.^[44]

In 2006, Hugh Cunningham published the book *Invention of Childhood*, looking at British childhood from the year 1000, the Middle Ages, to what he refers to as the Post War Period of the 1950s, 1960s and 1970s.^[45]

Childhood evolves and changes as lifestyles change and adult expectations alter. In the modern era, many adults believe that children should not have any worries or work, as life should be happy and trouble-free. Childhood is seen as a mixture of simplicity, innocence, happiness, fun, imagination, and wonder. It is thought of as a

time of playing, learning, socializing, exploring, and worrying in a world without much adult interference.^{[29][30]}

A "loss of innocence" is a common concept, and is often seen as an integral part of coming of age. It is usually thought of as an experience or period in a child's life that widens their awareness of evil, pain or the world around them. This theme is demonstrated in the novels *To Kill a Mockingbird* and *Lord of the Flies*. The fictional character Peter Pan was the embodiment of a childhood that never ends.^{[46][47]}

Healthy childhoods

[edit]

Role of parents

[edit]

Main article: Parenting

Children's health

[edit]

Further information: Childhood obesity, Childhood immunizations, and List of childhood diseases

Children's health includes the physical, mental and social well-being of children. Maintaining children's health implies offering them healthy foods, insuring they get enough sleep and exercise, and protecting their safety.^[48] Children in certain parts of the world often suffer from malnutrition, which is often associated with other conditions, such diarrhea, pneumonia and malaria.^[49]

Child protection

[edit]


Further information: Child labor, Child labor laws, Risk aversion, Child abuse, and Protection of Children Act

Child protection, according to UNICEF, refers to "preventing and responding to violence, exploitation and abuse against children – including commercial sexual exploitation, trafficking, child labour and harmful traditional practices, such as female genital mutilation/cutting and child marriage".^[50] The Convention on the Rights of the Child protects the fundamental rights of children.

Play

[edit]

Further information: Play (activity), Playground, Imaginary friend, and Childhood secret club




Dancing at Mother of Peace AIDs orphanage, Zimbabwe

Play is essential to the cognitive, physical, social, and emotional well-being of children.^[51] It offers children opportunities for physical (running, jumping, climbing, etc.), intellectual (social skills, community norms, ethics and general knowledge) and emotional development (empathy, compassion, and friendships). Unstructured play encourages creativity and imagination. Playing and interacting with other children, as well as some adults, provides opportunities for friendships, social interactions, conflicts and resolutions. However, adults tend to (often mistakenly)

assume that virtually all children's social activities can be understood as "play" and, furthermore, that children's play activities do not involve much skill or effort.^[52]^[53]
^[54]^[55]

It is through play that children at a very early age engage and interact in the world around them. Play allows children to create and explore a world they can master, conquering their fears while practicing adult roles, sometimes in conjunction with other children or adult caregivers.^[51] Undirected play allows children to learn how to work in groups, to share, to negotiate, to resolve conflicts, and to learn self-advocacy skills. However, when play is controlled by adults, children acquiesce to adult rules and concerns and lose some of the benefits play offers them. This is especially true in developing creativity, leadership, and group skills.^[51]



Ralph Hedley, *The Tournament*, 1898. It depicts poorer boys playing outdoors in a rural part of the Northeast of England.

Play is considered to be very important to optimal child development that it has been recognized by the United Nations Commission on Human Rights as a right of every child.^[11] Children who are being raised in a hurried and pressured style may limit the protective benefits they would gain from child-driven play.^[51]

The initiation of play in a classroom setting allows teachers and students to interact through playfulness associated with a learning experience. Therefore, playfulness aids the interactions between adults and children in a learning environment. "Playful Structure" means to combine informal learning with formal learning to produce an effective learning experience for children at a young age.^[56]


]

Even though play is considered to be the most important to optimal child development, the environment affects their play and therefore their development. Poor children confront widespread environmental inequities as they experience less social support, and their parents are less responsive and more authoritarian. Children from low income families are less likely to have access to books and computers which would enhance their development.^[57]

Street culture

[edit]

Main articles: Children's street culture and Children's street games



Children in front of a movie theatre, Toronto, 1920s.

Children's street culture refers to the cumulative culture created by young children and is sometimes referred to as their *secret world*. It is most common in children between the ages of seven and twelve. It is strongest in urban working class industrial districts where children are traditionally free to play out in the streets for long periods without supervision. It is invented and largely sustained by children themselves with little adult interference.

Young children's street culture usually takes place on quiet backstreets and pavements, and along routes that venture out into local parks, playgrounds, scrub and wasteland, and to local shops. It often imposes imaginative status on certain sections of the urban realm (local buildings, kerbs, street objects, etc.). Children

designate specific areas that serve as informal meeting and relaxation places (see: Sobel, 2001). An urban area that looks faceless or neglected to an adult may have deep 'spirit of place' meanings in to children. Since the advent of indoor distractions such as video games, and television, concerns have been expressed about the vitality – or even the survival – of children's street culture.

Geographies of childhood

[edit]

The geographies of childhood involves how (adult) society perceives the idea of childhood, the many ways adult attitudes and behaviors affect children's lives, including the environment which surrounds children and its implications.^[58]

The geographies of childhood is similar in some respects to children's geographies which examines the places and spaces in which children live.^[59]

Nature deficit disorder

[edit]

Main article: Nature deficit disorder

Nature Deficit Disorder, a term coined by Richard Louv in his 2005 book *Last Child in the Woods*, refers to the trend in the United States and Canada towards less time for outdoor play,^[60]^[61] resulting in a wide range of behavioral problems.^[62]

With increasing use of cellphones, computers, video games and television, children have more reasons to stay inside rather than outdoors exploring. "The average American child spends 44 hours a week with electronic media".^[63] Research in 2007 has drawn a correlation between the declining number of National Park visits in the U.S. and increasing consumption of electronic media by children.^[64] The media has accelerated the trend for children's nature disconnection by

deemphasizing views of nature, as in Disney films.^[65]

Age of responsibility


[edit]

Further information: Age of consent, Age of majority, Age of criminal responsibility, and Marriageable age


The age at which children are considered responsible for their society-bound actions (e. g. marriage, voting, etc.) has also changed over time,^[66] and this is reflected in the way they are treated in courts of law. In Roman times, children were regarded as not culpable for crimes, a position later adopted by the Church. In the 19th century, children younger than seven years old were believed incapable of crime. Children from the age of seven forward were considered responsible for their actions. Therefore, they could face criminal charges, be sent to adult prison, and be punished like adults by whipping, branding or hanging. However, courts at the time would consider the offender's age when deliberating sentencing.^[citation needed] Minimum employment age and marriage age also vary. The age limit of voluntary/involuntary military service is also disputed at the international level.^[67]

Education

[edit]



Children in an outdoor classroom in Bié, Angola



Children seated in a Finnish classroom at the school of Torvinen in Sodankylä, Finland, in the 1920s


Main article: Education

Education, in the general sense, refers to the act or process of imparting or acquiring general knowledge, developing the powers of reasoning and judgment, and preparing intellectually for mature life.^[68] Formal education most often takes place through schooling. A right to education has been recognized by some governments. At the global level, Article 13 of the United Nations' 1966 International Covenant on Economic, Social and Cultural Rights (ICESCR) recognizes the right of everyone to an education.^[69] Education is compulsory in most places up to a certain age, but attendance at school may not be, with alternative options such as home-schooling or e-learning being recognized as valid forms of education in certain jurisdictions.

Children in some countries (especially in parts of Africa and Asia) are often kept out of school, or attend only for short periods. Data from UNICEF indicate that in 2011, 57 million children were out of school; and more than 20% of African children have never attended primary school or have left without completing primary education.^[70] According to a UN report, warfare is preventing 28 million children worldwide from receiving an education, due to the risk of sexual violence and attacks in schools.^[71] Other factors that keep children out of school include poverty, child labor, social attitudes, and long distances to school.^{[72][73]}

Attitudes toward children

[edit]



Group of breaker boys in Pittston, Pennsylvania, 1911. Child labor was widespread until the early 20th century. In the 21st century, child labor rates are highest in Africa.

Social attitudes toward children differ around the world in various cultures and change over time. A 1988 study on European attitudes toward the centrality of children found that Italy was more child-centric and the Netherlands less child-centric, with other countries, such as Austria, Great Britain, Ireland and West Germany falling in between.^[74]

Child marriage

[edit]

In 2013, child marriage rates of female children under the age of 18 reached 75% in Niger, 68% in Central African Republic and Chad, 66% in Bangladesh, and 47% in India.^[75] According to a 2019 UNICEF report on child marriage, 37% of females were married before the age of 18 in sub-Saharan Africa, followed by South Asia at 30%. Lower levels were found in Latin America and Caribbean (25%), the Middle East and North Africa (18%), and Eastern Europe and Central Asia (11%), while rates in Western Europe and North America were minimal.^[76] Child marriage is more prevalent with girls, but also involves boys. A 2018 study in the journal *Vulnerable Children and Youth Studies* found that, worldwide, 4.5% of males are married before age 18, with the Central African Republic having the highest average rate at

27.9%.^[77]

Fertility and number of children per woman

[edit]

Before contraception became widely available in the 20th century, women had little choice other than abstinence or having often many children. In fact, current population growth concerns have only become possible with drastically reduced child mortality and sustained fertility. In 2017 the global total fertility rate was estimated to be 2.37 children per woman,^[78] adding about 80 million people to the world population per year. In order to measure the total number of children, scientists often prefer the completed cohort fertility at age 50 years (CCF50).^[78] Although the number of children is also influenced by cultural norms, religion, peer pressure and other social factors, the CCF50 appears to be most heavily dependent on the educational level of women, ranging from 5–8 children in women without education to less than 2 in women with 12 or more years of education.^[78]

Issues

[edit]

Emergencies and conflicts

[edit]

See also: Declaration on the Protection of Women and Children in Emergency and Armed Conflict, Children in the Israeli–Palestinian conflict, Save the Children, Inter-Agency Network for Education in Emergencies, Military use of children, Trafficking of children, International child abduction, and Refugee children

Emergencies and conflicts pose detrimental risks to the health, safety, and well-being of children. There are many different kinds of conflicts and emergencies, e.g.

wars and natural disasters. As of 2010 approximately 13 million children are displaced by armed conflicts and violence around the world.^[79] Where violent conflicts are the norm, the lives of young children are significantly disrupted and their families have great difficulty in offering the sensitive and consistent care that young children need for their healthy development.^[79] Studies on the effect of emergencies and conflict on the physical and mental health of children between birth and 8 years old show that where the disaster is natural, the rate of PTSD occurs in anywhere from 3 to 87 percent of affected children.^[80] However, rates of PTSD for children living in chronic conflict conditions varies from 15 to 50 percent.^{[81][82]}

Child protection

[edit]

This section is an excerpt from Child protection.[edit]

- v
- t
- e

Childcare

At home

- Parents
- Extended family
- Au pair
- Babysitter
- Governess
- Nanny

Outside the home

- Daycare
- Pre-school playgroup

Educational settings

- Early childhood education
- Homeschooling
- Pre-kindergarten
- Preschool
- Kindergarten
- Primary school

Institutions and standards

- Child protection
- *In loco parentis*
- Minor

Related

- Child abuse
- Child marriage
- Child Online Protection
- Family law
- Men in early childhood education
- Orphanage
- Parenting

Child protection (also called child welfare) is the safeguarding of children from violence, exploitation, abuse, abandonment, and neglect.^{[83][84][85][86]} It involves identifying signs of potential harm. This includes responding to allegations or suspicions of abuse, providing support and services to protect children, and holding those who have harmed them accountable.^[87]

The primary goal of child protection is to ensure that all children are safe and free from harm or danger.^{[86][88]} Child protection also works to prevent future harm by creating policies and systems that identify and respond to risks before they lead to harm.^[89]

In order to achieve these goals, research suggests that child protection services should be provided in a holistic way.^{[90][91][92]} This means taking into account the social, economic, cultural, psychological, and environmental factors that can contribute to the risk of harm for individual children and their families.

Collaboration across sectors and disciplines to create a comprehensive system of support and safety for children is required.^{[93][94]}

It is the responsibility of individuals, organizations, and governments to ensure that children are protected from harm and their rights are respected.^[95] This includes providing a safe environment for children to grow and develop, protecting them from physical, emotional and sexual abuse, and ensuring they have access to education, healthcare, and resources to fulfill their basic needs.^[96]

Child protection systems are a set of services, usually government-run, designed to protect children and young people who are underage and to encourage family stability. UNICEF defines^[97] a 'child protection system' as:

"The set of laws, policies, regulations and services needed across all social sectors – especially social welfare, education, health, security and justice – to support prevention and response to protection-related risks. These systems are part of social protection, and extend beyond it. At the level of prevention, their aim includes supporting and strengthening families to reduce social exclusion, and to lower the risk of separation, violence and exploitation. Responsibilities are often spread across government agencies, with services delivered by local authorities, non-

State providers, and community groups, making coordination between sectors and levels, including routine referral systems etc., a necessary component of effective child protection systems."

—*United Nations Economic and Social Council (2008), UNICEF Child Protection Strategy, E/ICEF/2008/5/Rev.1, par. 12–13.*

Under Article 19 of the UN Convention on the Rights of the Child, a 'child protection system' provides for the protection of children in and out of the home. One of the ways this can be enabled is through the provision of quality education, the fourth of the United Nations Sustainable Development Goals, in addition to other child protection systems. Some literature argues that child protection begins at conception; even how the conception took place can affect the child's development.^[98]

Child abuse and child labor

[edit]


Protection of children from abuse is considered an important contemporary goal. This includes protecting children from exploitation such as child labor, child trafficking and child selling, child sexual abuse, including child prostitution and child pornography, military use of children, and child laundering in illegal adoptions. There exist several international instruments for these purposes, such as:

- Worst Forms of Child Labour Convention
- Minimum Age Convention, 1973
- Optional Protocol on the Sale of Children, Child Prostitution and Child Pornography
- Council of Europe Convention on the Protection of Children against Sexual Exploitation and Sexual Abuse
- Optional Protocol on the Involvement of Children in Armed Conflict
- Hague Adoption Convention

Climate change

[edit]

This section is an excerpt from Climate change and children.[edit]



A child at a climate demonstration in Juneau, Alaska

Children are more vulnerable to the effects of climate change than adults. The World Health Organization estimated that 88% of the existing global burden of disease caused by climate change affects children under five years of age.^[99] A *Lancet* review on health and climate change lists children as the worst-affected category by climate change.^[100] Children under 14 are 44 percent more likely to die from environmental factors,^[101] and those in urban areas are disproportionately impacted by lower air quality and overcrowding.^[102]

Children are physically more vulnerable to climate change in all its forms.^[103] Climate change affects the physical health of children and their well-being. Prevailing inequalities, between and within countries, determine how climate change impacts children.^[104] Children often have no voice in terms of global responses to climate change.^[103]

People living in low-income countries experience a higher burden of disease and are less capable of coping with climate change-related threats.^[105] Nearly every child in the world is at risk from climate change and pollution, while almost half are

at extreme risk.^[106]


Health

[edit]

Child mortality

[edit]

Main articles: Child mortality and Infant mortality



World infant mortality rates in 2012.^[107]

During the early 17th century in England, about two-thirds of all children died before the age of four.^[108] During the Industrial Revolution, the life expectancy of children increased dramatically.^[109] This has continued in England, and in the 21st century child mortality rates have fallen across the world. About 12.6 million under-five infants died worldwide in 1990, which declined to 6.6 million in 2012. The infant mortality rate dropped from 90 deaths per 1,000 live births in 1990, to 48 in 2012. The highest average infant mortality rates are in sub-Saharan Africa, at 98 deaths per 1,000 live births – over double the world's average.^[107]

See also

[edit]

Listen to this article (3 minutes)

2. ^ **a b c** O'Toole, MT (2013). *Mosby's Dictionary of Medicine, Nursing & Health Professions*. St. Louis MO: Elsevier Health Sciences. p. 345. ISBN 978-0-323-07403-2. OCLC 800721165. Wikidata Q19573070.
3. ^ **a b** Rathus SA (2013). *Childhood and Adolescence: Voyages in Development*. Cengage Learning. p. 48. ISBN 978-1-285-67759-0.
4. ^ "Child". OED.com. Retrieved 11 April 2023.
5. ^ "Child". Merriam-Webster.com. Retrieved 11 April 2023.
6. ^ "When Is It Legal For Minors To Drink?". Alcohol.org. Retrieved 31 May 2024.
7. ^ "Children and the law". NSPCC Learning. Retrieved 31 May 2024.
8. ^ "23.8: Adulthood". LibreTexts - Biology. 31 December 2018. "A person may be physically mature and a biological adult by age 16 or so, but not defined as an adult by law until older ages. For example, in the U.S., you cannot join the armed forces or vote until age 18, and you cannot take on many legal and financial responsibilities until age 21."
9. ^ "For example, the US Social Security department specifically defines an adult child as being over 18". Ssa.gov. Archived from the original on 1 October 2013. Retrieved 9 October 2013.
10. ^ "American Heritage Dictionary". 7 December 2007. Archived from the original on 29 December 2007.
11. ^ **a b** "Convention on the Rights of the Child" (PDF). General Assembly Resolution 44/25 of 20 November 1989. The Policy Press, Office of the United Nations High Commissioner for Human Rights. Archived from the original (PDF) on 31 October 2010.
12. ^ "Children and Young Persons Act". Singapore Statutes Online. Archived from the original on 3 February 2018. Retrieved 20 October 2017.
13. ^ "Proposal to lower the Age of Contractual Capacity from 21 years to 18 years, and the Civil Law (Amendment) Bill". Singapore: Ministry of Law. Archived from the original on 26 June 2018. Retrieved 21 October 2017.
14. ^ "8 U.S. Code § 1101 - Definitions". LII / Legal Information Institute.
15. ^ See Shorter *Oxford English Dictionary* 397 (6th ed. 2007), which's first definition is "A fetus; an infant;...". See also 'The Compact Edition of the *Oxford English Dictionary*. Complete Text Reproduced Micrographically', Vol. I (Oxford University Press, Oxford 1971): 396, which defines it as: 'The unborn or newly born human being; foetus, infant'.

16. ^ Alam, Gajanafar (2014). *Population and Society*. K.K. Publications. ISBN 978-8178441986.
17. ^ Purdy ER (18 January 2019). "Infant and toddler development". *Encyclopedia Britannica*. Retrieved 27 May 2020.
18. ^ "Development In Middle Childhood".
19. ^ Collins WA, et al. (National Research Council (US) Panel to Review the Status of Basic Research on School-Age Children) (1984). *Development during Middle Childhood*. Washington D.C.: National Academies Press (US). doi:10.17226/56. ISBN 978-0-309-03478-4. PMID 25032422.
20. ^ **a b c** Berger K (2017). *The Developing Person through the Lifespan*. Worth Publishers. ISBN 978-1-319-01587-9.
21. ^ Konner M (2010). *The Evolution of Childhood*. Cambridge, Massachusetts: The Belknap Press of Harvard University Press. pp. 512–513. ISBN 978-0-674-04566-8.
22. ^ "APA Dictionary of Psychology".
23. ^ Mavis Klein, *Okay Parenting* (1991) p. 13 and p. 78
24. ^ E. Fenwick/T. Smith, *Adolescence* (London 1993) p. 29
25. ^ Pollock LA (2000). *Forgotten children : parent-child relations from 1500 to 1900*. Cambridge University Press. ISBN 978-0-521-25009-2. OCLC 255923951.
26. ^ Ariès P (1960). *Centuries of Childhood*.
27. ^ Orme, Nicholas (2001). *Medieval Children*. Yale University Press. ISBN 0-300-08541-9.
28. ^ Fox VC (April 1996). "Poor Children's Rights in Early Modern England". *The Journal of Psychohistory*. **23** (3): 286–306.
29. ^ **a b c** Cohen D (1993). *The development of play* (2nd ed.). London: Routledge. p. 20. ISBN 978-1-134-86782-0.
30. ^ **a b c** Reeves M (2018). "'A Prospect of Flowers', Concepts of Childhood and Female Youth in Seventeenth-Century British Culture". In Cohen ES, Reeves M (eds.). *The Youth of Early Modern Women*. Amsterdam University Press. p. 40. doi:10.2307/j.ctv8pzd5z. ISBN 978-90-485-3498-2. JSTOR j.ctv8pzd5z. S2CID 189343394. Retrieved 11 February 2018.
31. ^ Postle, Martin. (2005) "The Age of Innocence" Child Portraiture in Georgian Art and Society", in *Pictures of Innocence: Portraits of Children from Hogarth to Lawrence*. Bath: Holburne Museum of Art, pp. 7–8. ISBN 0903679094
32. ^ Reeves (2018), pp. 41–42.

33. ^ **a b** Del Col L (September 1930). "The Life of the Industrial Worker in Ninteenth-Century [sic] England — Evidence Given Before the Sadler Committee (1831–1832)". In Scott JF, Baltzly A (eds.). *Readings in European History*. Appleton-Century-Crofts.
34. ^ Daniels B. "Poverty and Families in the Victorian Era". hiddenlives.org.
35. ^ Malkovich A (2013). *Charles Dickens and the Victorian child : romanticizing and socializing the imperfect child*. New York: Routledge. ISBN 978-1-135-07425-8.
36. ^ "The Factory and Workshop Act, 1901". *British Medical Journal*. **2** (2139): 1871–1872. December 1901. doi:10.1136/bmj.2.2139.1871. ISSN 0959-8138. PMC 2507680. PMID 20759953.
37. ^ Jordan TE (1998). *Victorian child savers and their culture : a thematic evaluation*. Lewiston, New York: Edwin Mellen Press. ISBN 978-0-7734-8289-0. OCLC 39465039.
38. ^ Sagarra, Eda. (1977). *A Social History of Germany 1648–1914*, pp. 275–84
39. ^ Weber, Eugen. (1976). *Peasants into Frenchmen: The Modernization of Rural France, 1870–1914*, pp. 303–38
40. ^ Chudacoff HP (2007). *Children at Play: An American History*. New York University Press. ISBN 978-0-8147-1665-6.
41. ^ Woolgar B, La Riviere S (2002). *Why Brownsea? The Beginnings of Scouting*. Brownsea Island Scout and Guide Management Committee.
42. ^ Hillcourt, William (1964). *Baden-Powell; the two lives of a hero*. New York: Putnam. ISBN 978-0839535942. OCLC 1338723.
43. ^ Boehmer E (2004). *Notes to 2004 edition of Scouting for Boys*. Oxford: Oxford University Press.
44. ^ Ulbricht J (November 2005). "J.C. Holz Revisited: From Modernism to Visual Culture". *Art Education*. **58** (6): 12–17. doi:10.1080/00043125.2005.11651564. ISSN 0004-3125. S2CID 190482412.
45. ^ Cunningham H (July 2016). "The Growth of Leisure in the Early Industrial Revolution, c. 1780–c. 1840". *Leisure in the Industrial Revolution*. Routledge. pp. 15–56. doi:10.4324/9781315637679-2. ISBN 978-1-315-63767-9.
46. ^ Bloom, Harold. "Major themes in Lord of the Flies" (PDF). Archived (PDF) from the original on 11 December 2019.
47. ^ Barrie, J. M. *Peter Pan*. Hodder & Stoughton, 1928, Act V, Scene 2.
48. ^ "Children's Health". *MedlinePlus*. U.S. National Library of Medicine, National Institutes of Health, U.S. Department of Health and Human Services.

49. ^ Caulfield LE, de Onis M, Blössner M, Black RE (July 2004). "Undernutrition as an underlying cause of child deaths associated with diarrhea, pneumonia, malaria, and measles". *The American Journal of Clinical Nutrition*. **80** (1): 193–198. doi:10.1093/ajcn/80.1.193. PMID 15213048.
50. ^ "What is child Protection?" (PDF). *The United Nations Children's Fund (UniCeF)*. May 2006. Archived from the original (PDF) on 17 April 2021. Retrieved 7 January 2021.
51. ^ **a b c d** Ginsburg KR (January 2007). "The importance of play in promoting healthy child development and maintaining strong parent-child bonds". *Pediatrics*. **119** (1): 182–191. doi:10.1542/peds.2006-2697. PMID 17200287. S2CID 54617427.
52. ^ Björk-Willén P, Cromdal J (2009). "When education seeps into 'free play': How preschool children accomplish multilingual education". *Journal of Pragmatics*. **41** (8): 1493–1518. doi:10.1016/j.pragma.2007.06.006.
53. ^ Cromdal J (2001). "Can I be with?: Negotiating play entry in a bilingual school". *Journal of Pragmatics*. **33** (4): 515–543. doi:10.1016/S0378-2166(99)00131-9.
54. ^ Butler CW (2008). *Talk and social interaction in the playground*. Aldershot: Ashgate Publishing, Ltd. ISBN 978-0-7546-7416-0.
55. ^ Cromdal J (2009). "Childhood and social interaction in everyday life: Introduction to the special issue". *Journal of Pragmatics*. **41** (8): 1473–76. doi:10.1016/j.pragma.2007.03.008.
56. ^ Walsh G, Sproule L, McGuinness C, Trew K (July 2011). "Playful structure: a novel image of early years pedagogy for primary school classrooms". *Early Years* . **31** (2): 107–119. doi:10.1080/09575146.2011.579070. S2CID 154926596.
57. ^ Evans GW (2004). "The environment of childhood poverty". *The American Psychologist*. **59** (2): 77–92. doi:10.1037/0003-066X.59.2.77. PMID 14992634.
58. ^ Disney, Tom (2018). *Geographies of Children and Childhood*. Oxford University Press. doi:10.1093/OBO/9780199874002-0193.
59. ^ Holloway SL (2004). Holloway SL, Valentine G (eds.). *Children's Geographies*. doi:10.4324/9780203017524. ISBN 978-0-203-01752-4.
60. ^ Gardner M (29 June 2006). "For more children, less time for outdoor play: Busy schedules, less open space, more safety fears, and lure of the Web keep kids inside". *The Christian Science Monitor*.
61. ^ Swanbrow D. "U.S. children and teens spend more time on academics". *The University Record Online*. The University of Michigan. Archived from the original on 2 July 2007. Retrieved 7 January 2021.

72. ^ "UK | Education | Barriers to getting an education". *BBC News*. 10 April 2006. Retrieved 3 August 2014.
73. ^ Melik J (11 October 2012). "Africa gold rush lures children out of school". *Bbc.com – BBC News*. Retrieved 3 August 2014.
74. ^ Jones RK, Brayfield A (June 1997). "Life's greatest joy?: European attitudes toward the centrality of children". *Social Forces*. **75** (4): 1239–1269. doi:10.1093/sf/75.4.1239.
75. ^ "Child brides around the world sold off like cattle". *USA Today*. Associated Press. 8 March 2013. Archived from the original on 8 March 2013.
76. ^ "Child marriage". *UNICEF DATA*. Retrieved 27 April 2020.
77. ^ Gastón CM, Misunas C, Cappa C (3 July 2019). "Child marriage among boys: a global overview of available data". *Vulnerable Children and Youth Studies*. **14** (3): 219–228. doi:10.1080/17450128.2019.1566584. ISSN 1745-0128.
78. ^ **a b c** Vollset SE, Goren E, Yuan CW, Cao J, Smith AE, Hsiao T, et al. (October 2020). "Fertility, mortality, migration, and population scenarios for 195 countries and territories from 2017 to 2100: a forecasting analysis for the Global Burden of Disease Study". *Lancet*. **396** (10258): 1285–1306. doi:10.1016/s0140-6736(20)30677-2. PMC 7561721. PMID 32679112.
79. ^ **a b** UNICEF (2010). *The State of the World's Children Report, Special Edition (PDF)*. New York: UNICEF. ISBN 978-92-806-4445-6.
80. ^ Shannon MP, Lonigan CJ, Finch AJ, Taylor CM (January 1994). "Children exposed to disaster: I. Epidemiology of post-traumatic symptoms and symptom profiles". *Journal of the American Academy of Child and Adolescent Psychiatry*. **33** (1): 80–93. doi:10.1097/00004583-199401000-00012. PMID 8138525.
81. ^ De Jong JT (2002). *Trauma, War, and Violence: Public Mental Health in Socio Cultural Context*. New York: Kluwer. ISBN 978-0-306-47675-4.
82. ^ Marope PT, Kaga Y (2015). *Investing against Evidence: The Global State of Early Childhood Care and Education (PDF)*. Paris: UNESCO. pp. 118–125. ISBN 978-92-3-100113-0.
83. ^ Katz, Ilan; Katz, Carmit; Andresen, Sabine; Bérubé, Annie; Collin-Vezina, Delphine; Fallon, Barbara; Fouché, Ansie; Haffejee, Sadiyya; Masrawa, Nadia; Muñoz, Pablo; Priolo Filho, Sidnei R.; Tarabulsky, George; Truter, Elmiën; Varela, Natalia; Wekerle, Christine (June 2021). "Child maltreatment reports and Child Protection Service responses during COVID-19: Knowledge exchange among Australia, Brazil, Canada, Colombia, Germany, Israel, and South Africa". *Child Abuse & Neglect*. **116** (Pt 2): 105078. doi:10.1016/j.chiabu.2021.105078. ISSN 0145-2134. PMC 8446926. PMID 33931238.

84. ^ Oates, Kim (July 2013). "Medical dimensions of child abuse and neglect". *Child Abuse & Neglect*. **37** (7): 427–429. doi:10.1016/j.chiabu.2013.05.004. ISSN 0145-2134. PMID 23790510.
85. ^ Southall, David; MacDonald, Rhona (1 November 2013). "Protecting children from abuse: a neglected but crucial priority for the international child health agenda". *Paediatrics and International Child Health*. **33** (4): 199–206. doi:10.1179/2046905513Y.0000000097. ISSN 2046-9047. PMID 24070186. S2CID 29250788.
86. ^ a b Barth, R.P. (October 1999). "After Safety, What is the Goal of Child Welfare Services: Permanency, Family Continuity or Social Benefit?". *International Journal of Social Welfare*. **8** (4): 244–252. doi:10.1111/1468-2397.00091. ISSN 1369-6866.
87. ^ *Child Custody & Domestic Violence: A Call for Safety and Accountability*. Thousand Oaks, California: SAGE Publications, Inc. 2003. doi:10.4135/9781452231730. ISBN 978-0-7619-1826-4.
88. ^ Editorial team, Collective (11 September 2008). "WHO Regional Office for Europe and UNAIDS report on progress since the Dublin Declaration". *Eurosurveillance*. **13** (37). doi:10.2807/ese.13.37.18981-en. ISSN 1560-7917. PMID 18801311.
89. ^ Nixon, Kendra L.; Tutty, Leslie M.; Weaver-Dunlop, Gillian; Walsh, Christine A. (December 2007). "Do good intentions beget good policy? A review of child protection policies to address intimate partner violence". *Children and Youth Services Review*. **29** (12): 1469–1486. doi:10.1016/j.childyouth.2007.09.007. ISSN 0190-7409.
90. ^ Holland, S. (1 January 2004). "Liberty and Respect in Child Protection". *British Journal of Social Work*. **34** (1): 21–36. doi:10.1093/bjsw/bch003. ISSN 0045-3102.
91. ^ Wulczyn, Fred; Daro, Deborah; Fluke, John; Gregson, Kendra (2010). "Adapting a Systems Approach to Child Protection in a Cultural Context: Key Concepts and Considerations". *PsycEXTRA Dataset*. doi:10.1037/e516652013-176.
92. ^ Léveillé, Sophie; Chamberland, Claire (1 July 2010). "Toward a general model for child welfare and protection services: A meta-evaluation of international experiences regarding the adoption of the Framework for the Assessment of Children in Need and Their Families (FACNF)". *Children and Youth Services Review*. **32** (7): 929–944. doi:10.1016/j.childyouth.2010.03.009. ISSN 0190-7409.
93. ^ Winkworth, Gail; White, Michael (March 2011). "Australia's Children 'Safe and Well'? 1 Collaborating with Purpose Across Commonwealth Family Relationship and State Child Protection Systems: Australia's Children 'Safe and Well'".

Australian Journal of Public Administration. **70** (1): 1–14. doi:10.1111/j.1467-8500.2010.00706.x.

94. ^ Wulczyn, Fred; Daro, Deborah; Fluke, John; Gregson, Kendra (2010). "Adapting a Systems Approach to Child Protection in a Cultural Context: Key Concepts and Considerations". *PsycEXTRA Dataset*. doi:10.1037/e516652013-176.
95. ^ Howe, R. Brian; Covell, Katherine (July 2010). "Miseducating children about their rights". *Education, Citizenship and Social Justice*. **5** (2): 91–102. doi:10.1177/1746197910370724. ISSN 1746-1979. S2CID 145540907.
96. ^ "Child protection". www.unicef.org. Archived from the original on 7 March 2023. Retrieved 18 March 2023.
97. ^ "Economic and Social Council" (PDF). UNICEF. Archived from the original (PDF) on 23 January 2018. Retrieved 23 January 2018.
98. ^ "Protecting Children from Violence: Historical Roots and Emerging Trends", *Protecting Children from Violence*, Psychology Press, pp. 21–32, 13 September 2010, doi:10.4324/9780203852927-8, ISBN 978-0-203-85292-7
99. ^ Anderko, Laura; Chalupka, Stephanie; Du, Maritha; Hauptman, Marissa (January 2020). "Climate changes reproductive and children's health: a review of risks, exposures, and impacts". *Pediatric Research*. **87** (2): 414–419. doi:10.1038/s41390-019-0654-7. ISSN 1530-0447. PMID 31731287.
100. ^ Watts, Nick; Amann, Markus; Arnell, Nigel; Ayeb-Karlsson, Sonja; Belesova, Kristine; Boykoff, Maxwell; Byass, Peter; Cai, Wenjia; Campbell-Lendrum, Diarmid; Capstick, Stuart; Chambers, Jonathan (16 November 2019). "The 2019 report of The Lancet Countdown on health and climate change: ensuring that the health of a child born today is not defined by a changing climate". *Lancet*. **394** (10211): 1836–1878. doi:10.1016/S0140-6736(19)32596-6. hdl:10871/40583. ISSN 1474-547X. PMID 31733928. S2CID 207976337. Archived from the original on 19 April 2021. Retrieved 17 April 2021.
101. ^ Bartlett, Sheridan (2008). "Climate change and urban children: Impacts and implications for adaptation in low- and middle-income countries". *Environment and Urbanization*. **20** (2): 501–519. Bibcode:2008EnUrb..20..501B. doi:10.1177/0956247808096125. S2CID 55860349.
102. ^ "WHO | The global burden of disease: 2004 update". WHO. Archived from the original on 24 March 2009.
103. ^ **a b** Currie, Janet; Deschênes, Olivier (2016). "Children and Climate Change: Introducing the Issue". *The Future of Children*. **26** (1): 3–9. doi:10.1353/foc.2016.0000. ISSN 1054-8289. JSTOR 43755227. S2CID 77559783. Archived from the original on 18 April 2021. Retrieved 16 April

2021.

104. ^ Helldén, Daniel; Andersson, Camilla; Nilsson, Maria; Ebi, Kristie L.; Friberg, Peter; Alfvén, Tobias (1 March 2021). "Climate change and child health: a scoping review and an expanded conceptual framework". *The Lancet Planetary Health*. **5** (3): e164 – e175. doi:10.1016/S2542-5196(20)30274-6. ISSN 2542-5196. PMID 33713617.
105. ^ "Unless we act now: The impact of climate change on children". www.unicef.org. Archived from the original on 18 April 2021. Retrieved 16 April 2021.
106. ^ Carrington, Damian (20 August 2021). "A billion children at 'extreme risk' from climate impacts – Unicef". *The Guardian*. Archived from the original on 28 August 2021. Retrieved 29 August 2021.
107. ^ **a b** "Infant Mortality Rates in 2012" (PDF). UNICEF. 2013. Archived from the original (PDF) on 14 July 2014.
108. ^ Rorabaugh WJ, Critchlow DT, Baker PC (2004). *America's promise: a concise history of the United States (Volume 1: To 1877)*. Rowman & Littlefield. p. 47. ISBN 978-0-7425-1189-7.[permanent dead link]
109. ^ Kumar K (29 October 2020). "Modernization – Population Change". *Encyclopædia Britannica*.

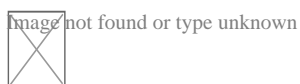
Further reading

[edit]

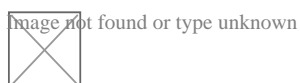
- Cook, Daniel Thomas. *The moral project of childhood: Motherhood, material life, and early children's consumer culture* (NYU Press, 2020). online book see also online review
- Fawcett, Barbara, Brid Featherstone, and Jim Goddard. *Contemporary child care policy and practice* (Bloomsbury Publishing, 2017) online
- Hutchison, Elizabeth D., and Leanne W. Charlesworth. "Securing the welfare of children: Policies past, present, and future." *Families in Society* 81.6 (2000): 576–585.
- Fass, Paula S. *The end of American childhood: A history of parenting from life on the frontier to the managed child* (Princeton University Press, 2016).
- Fass, Paula S. ed. *The Routledge History of Childhood in the Western World* (2012) online

- Klass, Perri. *The Best Medicine: How Science and Public Health Gave Children a Future* (WW Norton & Company, 2020) online
- Michail, Samia. "Understanding school responses to students' challenging behaviour: A review of literature." *Improving schools* 14.2 (2011): 156–171. online
- Sorin, Reesa. *Changing images of childhood: Reconceptualising early childhood practice* (Faculty of Education, University of Melbourne, 2005) online.
- Sorin, Reesa. "Childhood through the eyes of the child and parent." *Journal of Australian Research in Early Childhood Education* 14.1 (2007). online
- Vissing, Yvonne. "History of Children's Human Rights in the USA." in *Children's Human Rights in the USA: Challenges and Opportunities* (Cham: Springer International Publishing, 2023) pp. 181–212.
- Yuen, Francis K.O. *Social work practice with children and families: a family health approach* (Routledge, 2014) online.

Preceded by **Stages of human development** Succeeded by
Toddlerhood **Childhood** **Preadolescence**



Wikimedia Commons has media related to **Children**.



Wikisource has the text of the 1911 *Encyclopædia Britannica* article "**Child**".

- v
- t
- e

Family

- History
- Household
- Nuclear family
- Extended family
- Conjugal family
- Immediate family
- Matrifocal family

**First-degree
relatives**

- Parent
 - mother
 - father
- Child
 - son
 - daughter
- Sibling
 - brother
 - sister

**Second-
degree
relatives**

- Grandparent
- Grandchild
- Uncle/Aunt
- Niece and nephew
- Great-grandparent

**Third-degree
relatives**

- Great-grandchild
- Great-uncle/Great-aunt
- Cousin

Family-in-law

- Spouse
 - wife
 - husband
- Parent-in-law
- Sibling-in-law
- Child-in-law
 - daughter-in-law
 - son-in-law
- Stepparent
 - stepfather
 - stepmother

Stepfamily

- Stepchild
- Stepsibling

**Kinship
terminology**

- Kinship
- Australian Aboriginal kinship
- Adoption
- Affinity
- Consanguinity
- Disownment
- Divorce
- Estrangement
- Family of choice
- Fictive kinship
- Marriage
- Nurture kinship
- Chinese kinship
- Hawaiian kinship
- Sudanese kinship
- Eskimo kinship
- Iroquois kinship
- Crow kinship
- Omaha kinship

**Genealogy
and lineage**

- Bilateral descent
- Common ancestor
- Family name
- Heirloom
- Heredity
- Inheritance
- Lineal descendant
- collateral descent
- Matrilineality
- Patrilineality
- Progenitor
- Clan
- Royal descent

Family trees

- Pedigree chart
- Genogram
- Ahnentafel
- Genealogical numbering systems
- Seize quartiers
- Quarters of nobility

Relationships

- Agape (parental love)
- Eros (marital love)
- Philia (brotherly love)
- Storge (familial love)
- Filial piety
- Polyfidelity

Holidays

- Mother's Day
 - U.S.
- Father's Day
- Father–Daughter Day
- Siblings Day
- National Grandparents Day
- Parents' Day
- Children's Day
 - Japan
- Family Day
 - Canada
- American Family Day
- International Day of Families
- National Family Week
 - UK
- National Adoption Day

- Single parent
- Wedding anniversary
- Godparent
- Birth order
- Only child
- Middle child syndrome
- Sociology of the family
- Museum of Motherhood
- Astronaut family
- Dysfunctional family
- Domestic violence
- Incest
- Sibling abuse
- Sibling estrangement
- Sibling rivalry

Related

- v
- t
- e

Development of the human body

Before birth

- Development
- Zygote
- Embryo
- Fetus
- Gestational age

Birth and after

- Birth
- Child development
 - Stages
 - Early
 - Puberty
- Adult development
- Ageing
- Senescence
- Death
- Early years
 - Infant
 - Toddler
 - Early childhood
 - Childhood
 - Child

Phases

- Youth
 - Preadolescence
 - Adolescence
 - Emerging adulthood
- Adulthood
 - Young adult
 - Middle adult
 - Elder adult

Social and legal

- Dying
- Minor
- Age of majority

Authority control databases Image not found or type unknown
Edit this at Wikidata

National

- Germany
- United States
- France
- BnF data
- Czech Republic
- Spain
- Latvia
- Sweden
- Israel

Other

- NARA
- Encyclopedia of Modern Ukraine


About dental braces

This article **needs additional citations for verification**. Please help



Image not found or type unknown
improve this article by adding citations to reliable sources. Unsourced material may be challenged and removed.

Find sources: "Dental braces" – news · newspapers · books · scholar · JSTOR (August 2016) *(Learn how and when to remove this message)*



Dental braces

Dental braces (also known as **orthodontic braces**, or simply **braces**) are devices used in orthodontics that align and straighten teeth and help position them with

regard to a person's bite, while also aiming to improve dental health. They are often used to correct underbites, as well as malocclusions, overbites, open bites, gaps, deep bites, cross bites, crooked teeth, and various other flaws of the teeth and jaw. Braces can be either cosmetic or structural. Dental braces are often used in conjunction with other orthodontic appliances to help widen the palate or jaws and to otherwise assist in shaping the teeth and jaws.

Process


[edit]

The application of braces moves the teeth as a result of force and pressure on the teeth. Traditionally, four basic elements are used: brackets, bonding material, arch wire, and ligature elastic (also called an "O-ring"). The teeth move when the arch wire puts pressure on the brackets and teeth. Sometimes springs or rubber bands are used to put more force in a specific direction.^[1]


Braces apply constant pressure which, over time, moves teeth into the desired positions. The process loosens the tooth after which new bone grows to support the tooth in its new position. This is called bone remodelling. Bone remodelling is a biomechanical process responsible for making bones stronger in response to sustained load-bearing activity and weaker in the absence of carrying a load. Bones are made of cells called osteoclasts and osteoblasts. Two different kinds of bone resorption are possible: direct resorption, which starts from the lining cells of the alveolar bone, and indirect or retrograde resorption, which occurs when the periodontal ligament has been subjected to an excessive amount and duration of compressive stress.^[2] Another important factor associated with tooth movement is bone deposition. Bone deposition occurs in the distracted periodontal ligament. Without bone deposition, the tooth will loosen, and voids will occur distal to the direction of tooth movement.^[3]

Types

[edit]



"Clear" braces



Upper and Lower Jaw Functional Expanders


- **Traditional metal wired braces** (also known as "train track braces") are stainless-steel and are sometimes used in combination with titanium. Traditional metal braces are the most common type of braces.^[4] These braces have a metal bracket with elastic ties (also known as rubber bands) holding the wire onto the metal brackets. The second-most common type of braces is self-ligating braces, which have a built-in system to secure the archwire to the brackets and do not require elastic ties. Instead, the wire goes through the bracket. Often with this type of braces, treatment time is reduced, there is less pain on the teeth, and fewer adjustments are required than with traditional braces.
- **Gold-plated stainless steel** braces are often employed for patients allergic to nickel (a basic and important component of stainless steel), but may also be

chosen for aesthetic reasons.

- **Lingual braces** are a cosmetic alternative in which custom-made braces are bonded to the back of the teeth making them externally invisible.
- **Titanium braces** resemble stainless-steel braces but are lighter and just as strong. People with allergies to nickel in steel often choose titanium braces, but they are more expensive than stainless steel braces.
- **Customized orthodontic treatment systems** combine high technology including 3-D imaging, treatment planning software and a robot to custom bend the wire. Customized systems such as this offer faster treatment times and more efficient results.^[5]
- **Progressive, clear removable aligners** may be used to gradually move teeth into their final positions. Aligners are generally not used for complex orthodontic cases, such as when extractions, jaw surgery, or palate expansion are necessary.^[medical citation needed]^[6]

Fitting procedure

[edit]



A patient's teeth are prepared for the application of braces.

Orthodontic services may be provided by any licensed dentist trained in orthodontics. In North America, most orthodontic treatment is done by orthodontists, who are dentists in the diagnosis and treatment of *malocclusions*—malalignments of the teeth, jaws, or both. A dentist must complete 2–3 years of additional post-doctoral training to earn a specialty certificate in orthodontics.

There are many general practitioners who also provide orthodontic services.


The first step is to determine whether braces are suitable for the patient. The doctor consults with the patient and inspects the teeth visually. If braces are appropriate, a records appointment is set up where X-rays, moulds, and impressions are made. These records are analyzed to determine the problems and the proper course of action. The use of digital models is rapidly increasing in the orthodontic industry. Digital treatment starts with the creation of a three-dimensional digital model of the patient's arches. This model is produced by laser-scanning plaster models created using dental impressions. Computer-automated treatment simulation has the ability to automatically separate the gums and teeth from one another and can handle malocclusions well; this software enables clinicians to ensure, in a virtual setting, that the selected treatment will produce the optimal outcome, with minimal user input. ^[*medical citation needed*]

Typical treatment times vary from six months to two and a half years depending on the complexity and types of problems. Orthognathic surgery may be required in extreme cases. About 2 weeks before the braces are applied, orthodontic spacers may be required to spread apart back teeth in order to create enough space for the bands.

Teeth to be braced will have an adhesive applied to help the cement bond to the surface of the tooth. In most cases, the teeth will be banded and then brackets will be added. A bracket will be applied with dental cement, and then cured with light until hardened. This process usually takes a few seconds per tooth. If required, orthodontic spacers may be inserted between the molars to make room for molar bands to be placed at a later date. Molar bands are required to ensure brackets will stick. Bands are also utilized when dental fillings or other dental works make securing a bracket to a tooth infeasible. Orthodontic tubes (stainless steel tubes that allow wires to pass through them), also known as molar tubes, are directly bonded to molar teeth either by a chemical curing or a light curing adhesive.

Usually, molar tubes are directly welded to bands, which is a metal ring that fits onto the molar tooth. Directly bonded molar tubes are associated with a higher failure rate when compared to molar bands cemented with glass ionomer cement. Failure of orthodontic brackets, bonded tubes or bands will increase the overall treatment time for the patient. There is evidence suggesting that there is less enamel decalcification associated with molar bands cemented with glass ionomer cement compared with orthodontic tubes directly cemented to molars using a light cured adhesive. Further evidence is needed to withdraw a more robust conclusion due to limited data.^[7]

An archwire will be threaded between the brackets and affixed with elastic or metal ligatures. Ligatures are available in a wide variety of colours, and the patient can choose which colour they like. Arch wires are bent, shaped, and tightened frequently to achieve the desired results.



Dental braces, with a transparent power chain, removed after completion of treatment.

Modern orthodontics makes frequent use of nickel-titanium archwires and temperature-sensitive materials. When cold, the archwire is limp and flexible, easily threaded between brackets of any configuration. Once heated to body temperature, the arch wire will stiffen and seek to retain its shape, creating constant light force on the teeth.


Brackets with hooks can be placed, or hooks can be created and affixed to the arch wire to affix rubber bands. The placement and configuration of the rubber bands will depend on the course of treatment and the individual patient. Rubber

bands are made in different diameters, colours, sizes, and strengths. They are also typically available in two versions: Coloured or clear/opaque.

The fitting process can vary between different types of braces, though there are similarities such as the initial steps of moulding the teeth before application. For example, with clear braces, impressions of a patient's teeth are evaluated to create a series of trays, which fit to the patient's mouth almost like a protective mouthpiece. With some forms of braces, the brackets are placed in a special form that is customized to the patient's mouth, drastically reducing the application time.

In many cases, there is insufficient space in the mouth for all the teeth to fit properly. There are two main procedures to make room in these cases. One is extraction: teeth are removed to create more space. The second is expansion, in which the palate or arch is made larger by using a palatal expander. Expanders can be used with both children and adults. Since the bones of adults are already fused, expanding the palate is not possible without surgery to separate them. An expander can be used on an adult without surgery but would be used to expand the dental arch, and not the palate.

Sometimes children and teenage patients, and occasionally adults, are required to wear a headgear appliance as part of the primary treatment phase to keep certain teeth from moving (for more detail on headgear and facemask appliances see Orthodontic headgear). When braces put pressure on one's teeth, the periodontal membrane stretches on one side and is compressed on the other. This movement needs to be done slowly or otherwise, the patient risks losing their teeth. This is why braces are worn as long as they are and adjustments are only made every so often.



Young Colombian man during an adjustment visit for his orthodontics

Braces are typically adjusted every three to six weeks. This helps shift the teeth into the correct position. When they get adjusted, the orthodontist removes the coloured or metal ligatures keeping the arch wire in place. The arch wire is then removed and may be replaced or modified. When the archwire has been placed back into the mouth, the patient may choose a colour for the new elastic ligatures, which are then affixed to the metal brackets. The adjusting process may cause some discomfort to the patient, which is normal.

Post-treatment


[edit]

Patients may need post-orthodontic surgery, such as a fiberotomy or alternatively a gum lift, to prepare their teeth for retainer use and improve the gumline contours after the braces come off. After braces treatment, patients can use a transparent plate to keep the teeth in alignment for a certain period of time. After treatment, patients usually use transparent plates for 6 months. In patients with long and difficult treatment, a fixative wire is attached to the back of the teeth to prevent the teeth from returning to their original state.^[8]

Retainers

[edit]

Main article: Retainer (orthodontic device)



Hawley retainers are the most common type of retainers. This picture shows retainers for the top (right) and bottom (left) of the mouth.

In order to prevent the teeth from moving back to their original position, retainers are worn once the treatment is complete. Retainers help in maintaining and stabilizing the position of teeth long enough to permit the reorganization of the supporting structures after the active phase of orthodontic therapy. If the patient does not wear the retainer appropriately and/or for the right amount of time, the teeth may move towards their previous position. For regular braces, Hawley retainers are used. They are made of metal hooks that surround the teeth and are enclosed by an acrylic plate shaped to fit the patient's palate. For Clear Removable braces, an Essix retainer is used. This is similar to the original aligner; it is a clear plastic tray that is firmly fitted to the teeth and stays in place without a plate fitted to the palate. There is also a bonded retainer where a wire is permanently bonded to the lingual side of the teeth, usually the lower teeth only.


Headgear

[edit]

Main article: Orthodontic headgear

Headgear needs to be worn between 12 and 22 hours each day to be effective in correcting the overbite, typically for 12 to 18 months depending on the severity of the overbite, how much it is worn and what growth stage the patient is in. Typically the prescribed daily wear time will be between 14 and 16 hours a day and is frequently used as a post-primary treatment phase to maintain the position of the jaw and arch. Headgear can be used during the night while the patient sleeps.^[9] *better sou*

Orthodontic headgear usually consists of three major components:



Full orthodontic headgear with head cap, fitting straps, facebow and elastics

1. Facebow: the facebow (or J-Hooks) is fitted with a metal arch onto headgear tubes attached to the rear upper and lower molars. This facebow then extends out of the mouth and around the patient's face. J-Hooks are different in that they hook into the patient's mouth and attach directly to the brace (see photo for an example of J-Hooks).
2. Head cap: the head cap typically consists of one or a number of straps fitting around the patient's head. This is attached with elastic bands or springs to the facebow. Additional straps and attachments are used to ensure comfort and safety (see photo).

3. Attachment: typically consisting of rubber bands, elastics, or springs—joins the facebow or J-Hooks and the head cap together, providing the force to move the upper teeth, jaw backwards.

The headgear application is one of the most useful appliances available to the orthodontist when looking to correct a Class II malocclusion. See more details in the section Orthodontic headgear.

Pre-finisher

[edit]

The pre-finisher is moulded to the patient's teeth by use of extreme pressure on the appliance by the person's jaw. The product is then worn a certain amount of time with the user applying force to the appliance in their mouth for 10 to 15 seconds at a time. The goal of the process is to increase the exercise time in applying the force to the appliance. If a person's teeth are not ready for a proper retainer the orthodontist may prescribe the use of a preformed finishing appliance such as the pre-finisher. This appliance fixes gaps between the teeth, small spaces between the upper and lower jaw, and other minor problems.

Complications and risks

[edit]

A group of dental researchers, Fatma Boke, Cagri Gazioglu, Selvi Akkaya, and Murat Akkaya, conducted a study titled "Relationship between orthodontic treatment and gingival health." The results indicated that some orthodontist treatments result in gingivitis, also known as gum disease. The researchers concluded that functional appliances used to harness natural forces (such as improving the alignment of bites) do not usually have major effects on the gum after treatment.^[10] However, fixed appliances such as braces, which most people get, can result in visible

plaque, visible inflammation, and gum recession in a majority of the patients. The formation of plaques around the teeth of patients with braces is almost inevitable regardless of plaque control and can result in mild gingivitis. But if someone with braces does not clean their teeth carefully, plaques will form, leading to more severe gingivitis and gum recession.

Experiencing some pain following fitting and activation of fixed orthodontic braces is very common and several methods have been suggested to tackle this.^{[11][12]}

Pain associated with orthodontic treatment increases in proportion to the amount of force that is applied to the teeth. When a force is applied to a tooth via a brace, there is a reduction in the blood supply to the fibres that attach the tooth to the surrounding bone. This reduction in blood supply results in inflammation and the release of several chemical factors, which stimulate the pain response.

Orthodontic pain can be managed using pharmacological interventions, which involve the use of analgesics applied locally or systemically. These analgesics are divided into four main categories, including opioids, non-steroidal anti-inflammatory drugs (NSAIDs), paracetamol and local anesthesia. The first three of these analgesics are commonly taken systemically to reduce orthodontic pain.^[13]

A Cochrane Review in 2017 evaluated the pharmacological interventions for pain relief during orthodontic treatment. The study concluded that there was moderate-quality evidence that analgesics reduce the pain associated with orthodontic treatment. However, due to a lack of evidence, it was unclear whether systemic NSAIDs were more effective than paracetamol, and whether topical NSAIDs were more effective than local anaesthesia in the reduction of pain associated with orthodontic treatment. More high-quality research is required to investigate these particular comparisons.^[13]

The dental displacement obtained with the orthodontic appliance determines in most cases some degree of root resorption. Only in a few cases is this side effect large enough to be considered real clinical damage to the tooth. In rare cases, the


teeth may fall out or have to be extracted due to root resorption.^{[14][15]}

History

[edit]

Ancient

[edit]



Old Braces at a museum in Jbeil, Lebanon


According to scholars and historians, braces date back to ancient times. Around 400–300 BC, Hippocrates and Aristotle contemplated ways to straighten teeth and fix various dental conditions. Archaeologists have discovered numerous mummified ancient individuals with what appear to be metal bands wrapped around their teeth. Catgut, a type of cord made from the natural fibres of an animal's intestines, performed a similar role to today's orthodontic wire in closing gaps in the teeth and mouth.^[16]

The Etruscans buried their dead with dental appliances in place to maintain space and prevent the collapse of the teeth during the afterlife. A Roman tomb was found with a number of teeth bound with gold wire documented as a ligature wire, a small elastic wire that is used to affix the arch wire to the bracket. Even Cleopatra wore a pair. Roman philosopher and physician Aulus Cornelius Celsus first recorded the treatment of teeth by finger pressure. Unfortunately, due to a lack of evidence, poor preservation of bodies, and primitive technology, little research was carried

out on dental braces until around the 17th century, although dentistry was making great advancements as a profession by then.^[citation needed]

18th century

[edit]



Portrait of Fauchard from his 1728 edition of *"The Surgical Dentist"*.

Orthodontics truly began developing in the 18th and 19th centuries. In 1669, French dentist Pierre Fauchard, who is often credited with inventing modern orthodontics, published a book entitled *"The Surgeon Dentist"* on methods of straightening teeth. Fauchard, in his practice, used a device called a "Bandeau", a horseshoe-shaped piece of iron that helped expand the palate. In 1754, another French dentist, Louis Bourdet, dentist to the King of France, followed Fauchard's book with *The Dentist's Art*, which also dedicated a chapter to tooth alignment and application. He perfected the "Bandeau" and was the first dentist on record to recommend extraction of the premolar teeth to alleviate crowding and improve jaw growth.

19th century

[edit]

Although teeth and palate straightening and/or pulling were used to improve the alignment of remaining teeth and had been practised since early times, orthodontics, as a science of its own, did not really exist until the mid-19th century. Several important dentists helped to advance dental braces with specific instruments and tools that allowed braces to be improved.

In 1819, Christophe François Delabarre introduced the wire crib, which marked the birth of contemporary orthodontics, and gum elastics were first employed by Maynard in 1843. Tucker was the first to cut rubber bands from rubber tubing in 1850. Dentist, writer, artist, and sculptor Norman William Kingsley in 1858 wrote the first article on orthodontics and in 1880, his book, *Treatise on Oral Deformities*, was published. A dentist named John Nutting Farrar is credited for writing two volumes entitled, *A Treatise on the Irregularities of the Teeth and Their Corrections* and was the first to suggest the use of mild force at timed intervals to move teeth.

20th century

[edit]


In the early 20th century, Edward Angle devised the first simple classification system for malocclusions, such as Class I, Class II, and so on. His classification system is still used today as a way for dentists to describe how crooked teeth are, what way teeth are pointing, and how teeth fit together. Angle contributed greatly to the design of orthodontic and dental appliances, making many simplifications. He founded the first school and college of orthodontics, organized the American Society of Orthodontia in 1901 which became the American Association of Orthodontists (AAO) in the 1930s, and founded the first orthodontic journal in

1907. Other innovations in orthodontics in the late 19th and early 20th centuries included the first textbook on orthodontics for children, published by J.J. Guilford in 1889, and the use of rubber elastics, pioneered by Calvin S. Case, along with Henry Albert Baker.

Today, space age wires (also known as dental arch wires) are used to tighten braces. In 1959, the Naval Ordnance Laboratory created an alloy of nickel and titanium called Nitinol. NASA further studied the material's physical properties.^[17] In 1979, Dr. George Andreasen developed a new method of fixing braces with the use of the Nitinol wires based on their superelasticity. Andreasen used the wire on some patients and later found out that he could use it for the entire treatment. Andreasen then began using the nitinol wires for all his treatments and as a result, dental doctor visits were reduced, the cost of dental treatment was reduced, and patients reported less discomfort.

See also

[edit]

-  [Medicine portal](#) Image file cannot be displayed. Your computer may not have enough memory to open the image, or the image may have been deleted. Restart your computer and try again. If the red x still appears, you may have to delete the image and then insert it again.
- Mandibular advancement splint
- Oral and maxillofacial surgery
- Orthognathic surgery
- Prosthodontics
- Trismus
- Dental implant

References

[edit]

- [^] *"Dental Braces and Retainers". WebMD. Retrieved 2020-10-30.*
- [^] *Robling, Alexander G.; Castillo, Alesha B.; Turner, Charles H. (2006). "Biomechanical and Molecular Regulation of Bone Remodeling". Annual Review of Biomedical Engineering. 8: 455–498.*

doi:10.1146/annurev.bioeng.8.061505.095721. PMID 16834564.


3. ^ Toledo SR, Oliveira ID, Okamoto OK, Zago MA, de Seixas Alves MT, Filho RJ, et al. (September 2010). "Bone deposition, bone resorption, and osteosarcoma". *Journal of Orthopaedic Research*. **28** (9): 1142–1148. doi:10.1002/jor.21120. PMID 20225287. S2CID 22660771.
4. ^ "Metal Braces for Teeth: Braces Types, Treatment, Cost in India". Clove Dental . Retrieved 2025-02-06.
5. ^ Saxe, Alana K.; Louie, Lenore J.; Mah, James (2010). "Efficiency and effectiveness of SureSmile". *World Journal of Orthodontics*. **11** (1): 16–22. PMID 20209172.
6. ^ Tamer, Ąfâ€žĄ°pek (December 2019). "Orthodontic Treatment with Clear Aligners and The Scientific Reality Behind Their Marketing: A Literature Review". *Turkish Journal of Orthodontics*. **32** (4): 241–246. doi:10.5152/TurkJOrthod.2019.18083. PMC 7018497. PMID 32110470.
7. ^ Millett DT, Mandall NA, Mattick RC, Hickman J, Glenny AM (February 2017). "Adhesives for bonded molar tubes during fixed brace treatment". *The Cochrane Database of Systematic Reviews*. **2** (3): CD008236. doi:10.1002/14651858.cd008236.pub3. PMC 6464028. PMID 28230910.
8. ^ Rubie J Patrick (2017). "What About Teeth After Braces?" 2017 – "Health Journal Article" Toothcost Archived 2021-10-18 at the Wayback Machine
9. ^ Naten, Joshua. "Braces Headgear (Treatments)". *toothcost.com*. Archived from the original on 19 October 2021.
10. ^ Boke, Fatma; Gazioglu, Cagri; Akkaya, Sevil; Akkaya, Murat (2014). "Relationship between orthodontic treatment and gingival health: A retrospective study". *European Journal of Dentistry*. **8** (3): 373–380. doi:10.4103/1305-7456.137651. ISSN 1305-7456. PMC 4144137. PMID 25202219.
11. ^ Eslamian L, Borzabadi-Farahani A, Hassanzadeh-Azhiri A, Badiee MR, Fekrazad R (March 2014). "The effect of 810-nm low-level laser therapy on pain caused by orthodontic elastomeric separators". *Lasers in Medical Science*. **29** (2): 559–64. doi:10.1007/s10103-012-1258-1. PMID 23334785. S2CID 25416518.
12. ^ Eslamian L, Borzabadi-Farahani A, Edini HZ, Badiee MR, Lynch E, Mortazavi A (September 2013). "The analgesic effect of benzocaine mucoadhesive patches on orthodontic pain caused by elastomeric separators, a preliminary study". *Acta Odontologica Scandinavica*. **71** (5): 1168–73. doi:10.3109/00016357.2012.757358. PMID 23301559. S2CID 22561192.
13. ^ a b Monk AB, Harrison JE, Worthington HV, Teague A (November 2017). "Pharmacological interventions for pain relief during orthodontic treatment". *The*

Cochrane Database of Systematic Reviews. **11** (12): CD003976.
doi:10.1002/14651858.cd003976.pub2. PMC 6486038. PMID 29182798.

14. ^ Artun J, Smale I, Behbehani F, Doppel D, Van't Hof M, Kuijpers-Jagtman AM (November 2005). "Apical root resorption six and 12 months after initiation of fixed orthodontic appliance therapy". *The Angle Orthodontist*. **75** (6): 919–26. PMID 16448232.
15. ^ Mavragani M, Vergari A, Selliseth NJ, Bøe OE, Wisth PL (December 2000). "A radiographic comparison of apical root resorption after orthodontic treatment with a standard edgewise and a straight-wire edgewise technique". *European Journal of Orthodontics*. **22** (6): 665–74. doi:10.1093/ejo/22.6.665. PMID 11212602.
16. ^ Wahl N (February 2005). "Orthodontics in 3 millennia. Chapter 1: Antiquity to the mid-19th century". *American Journal of Orthodontics and Dentofacial Orthopedics*. **127** (2): 255–9. doi:10.1016/j.ajodo.2004.11.013. PMID 15750547.
17. ^ "NASA Technical Reports Server (NTRS)". Spinoff 1979. February 1979. Retrieved 2021-03-02.

External links

[edit]

- Useful Resources: FAQ and Downloadable eBooks at Orthodontics Australia
- Orthos Explain: Treatment Options at Orthodontics Australia
-  Media related to Dental braces at Wikimedia Commons
- v
- t
- e

Orthodontics

Diagnosis

- Bolton analysis
- Cephalometric analysis
- Cephalometry
- Dentition analysis
- Failure of eruption of teeth
- Little's Irregularity Index
- Malocclusion
- Scissor bite
- Standard anatomical position
- Tooth ankylosis
- Tongue thrust
- Overbite
- Overjet
- Open bite
- Crossbite
- Dental crowding
- Dental spacing

Conditions

- Bimaxillary Protrusion
- Prognathism
- Retrognathism
- Maxillary hypoplasia
- Condylar hyperplasia
- Overeruption
- Mouth breathing
- Temporomandibular dysfunction

- ACCO appliance
- Archwire
- Activator appliance
- Braces
- Damon system
- Elastics
- Frankel appliance
- Invisalign
- Lingual arch
- Lip bumper
- Herbst Appliance
- List of orthodontic functional appliances
- List of palatal expanders
- Lingual braces
- Headgear
- Orthodontic technology
- Orthodontic spacer
- Palatal lift prosthesis
- Palatal expander
- Quad helix
- Retainer
- SureSmile
- Self-ligating braces
- Splint activator
- Twin Block Appliance

Appliances

Procedures

- Anchorage (orthodontics)
- Cantilever mechanics
- Fiberotomy
- Interproximal reduction
- Intrusion (orthodontics)
- Molar distalization
- SARPE
- Serial extraction

Materials

- Beta-titanium
- Nickel titanium
- Stainless steel
- TiMolium
- Elgiloy
- Ceramic
- Composite
- Dental elastics

- Edward Angle
- Spencer Atkinson
- Clifford Ballard
- Raymond Begg
- Hans Peter Bimler
- Samir Bishara
- Arne Björk
- Charles B. Bolton
- Holly Broadbent Sr.
- Allan G. Brodie
- Charles J. Burstone
- Peter Buschang
- Calvin Case
- Harold Chapman (Orthodontist)
- David Di Biase
- Jean Delaire
- Terry Dischinger
- William B. Downs
- John Nutting Farrar
- Rolf Frankel
- Sheldon Friel
- Thomas M. Graber
- Charles A. Hawley
- Reed Holdaway
- John Hooper (Orthodontist)
- Joseph Jarabak
- Harold Kesling
- Albert Ketcham
- Juri Kurol
- Craven Kurz
- Benno Lischer
- James A. McNamara
- Birte Melsen
- Robert Moyers

**Notable
contributors**

- American Association of Orthodontists
- American Board of Orthodontics
- British Orthodontic Society
- Organizations**
 - Canadian Association of Orthodontists
 - Indian Orthodontic Society
 - Italian Academy of Orthodontic Technology
 - Society for Orthodontic Dental Technology (Germany)
 - American Journal of Orthodontics and Dentofacial Orthopedics
- Journals**
 - The Angle Orthodontist
 - Journal of Orthodontics
- Institution**
 - Angle School of Orthodontia


- Germany
- United States
- Authority control databases: National**
 - France
 - BnF data
 - Israel

[Image not found. Type unknown](#)
[Edit this at Wikidata](#)

About tooth

This article is about teeth in general. For specifically human teeth, see Human tooth. For other uses, see Tooth (disambiguation).

Tooth



A chimpanzee displaying his teeth

Details	
Identifiers	
Latin	<i>dens</i>
MeSH	D014070
FMA	12516

Anatomical terminology

[\[edit on Wikidata\]](#)

A **tooth** (pl.: **teeth**) is a hard, calcified structure found in the jaws (or mouths) of many vertebrates and used to break down food. Some animals, particularly carnivores and omnivores, also use teeth to help with capturing or wounding prey, tearing food, for defensive purposes, to intimidate other animals often including their own, or to carry prey or their young. The roots of teeth are covered by gums. Teeth are not made of bone, but rather of multiple tissues of varying density and hardness that originate from the outermost embryonic germ layer, the ectoderm.

The general structure of teeth is similar across the vertebrates, although there is considerable variation in their form and position. The teeth of mammals have deep roots, and this pattern is also found in some fish, and in crocodilians. In most teleost fish, however, the teeth are attached to the outer surface of the bone, while in lizards they are attached to the inner surface of the jaw by one side. In

cartilaginous fish, such as sharks, the teeth are attached by tough ligaments to the hoops of cartilage that form the jaw.[¹]

Monophyodonts are animals that develop only one set of teeth, while diphyodonts grow an early set of deciduous teeth and a later set of permanent or "adult" teeth. Polyphyodonts grow many sets of teeth. For example, sharks, grow a new set of teeth every two weeks to replace worn teeth. Most extant mammals including humans are diphyodonts, but there are exceptions including elephants, kangaroos, and manatees, all of which are polyphyodonts.

Rodent incisors grow and wear away continually through gnawing, which helps maintain relatively constant length. The industry of the beaver is due in part to this qualification. Some rodents, such as voles and guinea pigs (but not mice), as well as lagomorpha (rabbits, hares and pikas), have continuously growing molars in addition to incisors.[²][³] Also, tusks (in tusked mammals) grow almost throughout life.[⁴]

Teeth are not always attached to the jaw, as they are in mammals. In many reptiles and fish, teeth are attached to the palate or to the floor of the mouth, forming additional rows inside those on the jaws proper. Some teleosts even have teeth in the pharynx. While not true teeth in the usual sense, the dermal denticles of sharks are almost identical in structure and are likely to have the same evolutionary origin. Indeed, teeth appear to have first evolved in sharks, and are not found in the more primitive jawless fish – while lampreys do have tooth-like structures on the tongue, these are in fact, composed of keratin, not of dentine or enamel, and bear no relationship to true teeth.[¹] Though "modern" teeth-like structures with dentine and enamel have been found in late conodonts, they are now supposed to have evolved independently of later vertebrates' teeth.[⁵][⁶]

Living amphibians typically have small teeth, or none at all, since they commonly feed only on soft foods. In reptiles, teeth are generally simple and conical in shape, although there is some variation between species, most notably the venom-

injecting fangs of snakes. The pattern of incisors, canines, premolars and molars is found only in mammals, and to varying extents, in their evolutionary ancestors. The numbers of these types of teeth vary greatly between species; zoologists use a standardised dental formula to describe the precise pattern in any given group.^[1]

Etymology

[edit]

The word *tooth* comes from Proto-Germanic **tanþs*, derived from the Proto-Indo-European **h₂nt-*, which was composed of the root **h₂nt-* 'to eat' plus the active participle suffix **-nt-*, therefore literally meaning 'that which eats'.^[7]

The irregular plural form *teeth* is the result of Germanic umlaut whereby vowels immediately preceding a high vocalic in the following syllable were raised. As the nominative plural ending of the Proto-Germanic consonant stems (to which **tanþs* belonged) was **-iz*, the root vowel in the plural form **tanþiz* (changed by this point to **t^{ai}ntiz* via unrelated phonological processes) was raised to */e^{ai}ntiz/*, and later unrounded to */e^{ai}ntiz/*, resulting in the *t^{ai}ntiz* alternation attested from Old English. Cf. also Old English *b^{ai}nc/b^ænc* 'book/books' and *m^{ai}se/m^æse* 'mouse/mice', from Proto-Germanic **b^{ai}ns/m^{ai}ns* and **m^{ai}ks/m^{ai}ks* respectively.

Cognate with Latin *d^{ai}ns*, Greek *δ^{ai}ς* (*dois*) and Sanskrit *dāt*.

Origin

[edit]

Teeth are assumed to have evolved either from ectoderm denticles (scales, much like those on the skin of sharks) that folded and integrated into the mouth (called the "outside-in" theory), or from endoderm pharyngeal teeth (primarily formed in the pharynx of jawless vertebrates) (the "inside-out" theory). In addition, there is another theory stating that neural crest gene regulatory network, and neural crest-derived ectomesenchyme are the key to generate teeth (with any epithelium, either ectoderm or endoderm).^{[4][8]}

The genes governing tooth development in mammals are homologous to those involved in the development of fish scales.^[9] Study of a tooth plate of a fossil of the extinct fish *Romundina stellina* showed that the teeth and scales were made of the same tissues, also found in mammal teeth, lending support to the theory that teeth evolved as a modification of scales.^[10]

Mammals

[edit]

Main article: Mammal tooth

Teeth are among the most distinctive (and long-lasting) features of mammal species. Paleontologists use teeth to identify fossil species and determine their relationships. The shape of the animal's teeth are related to its diet. For example, plant matter is hard to digest, so herbivores have many molars for chewing and grinding. Carnivores, on the other hand, have canine teeth to kill prey and to tear meat.

Mammals, in general, are diphyodont, meaning that they develop two sets of teeth. In humans, the first set (the "baby", "milk", "primary" or "deciduous" set) normally starts to appear at about six months of age, although some babies are born with one or more visible teeth, known as neonatal teeth. Normal tooth eruption at about six months is known as teething and can be painful. Kangaroos, elephants, and manatees are unusual among mammals because they are polyphyodonts.

Aardvark

[edit]

In aardvarks, teeth lack enamel and have many pulp tubules, hence the name of the order Tubulidentata.^[11]

Canines

[edit]

In dogs, the teeth are less likely than humans to form dental cavities because of the very high pH of dog saliva, which prevents enamel from demineralizing.^[12] Sometimes called cuspids, these teeth are shaped like points (cusps) and are used for tearing and grasping food.^[13]

Cetaceans

[edit]

Main article: Baleen

Like human teeth, whale teeth have polyp-like protrusions located on the root surface of the tooth. These polyps are made of cementum in both species, but in human teeth, the protrusions are located on the outside of the root, while in whales the nodule is located on the inside of the pulp chamber. While the roots of human teeth are made of cementum on the outer surface, whales have cementum on the entire surface of the tooth with a very small layer of enamel at the tip. This small enamel layer is only seen in older whales where the cementum has been worn away to show the underlying enamel.^[14]

The toothed whale is a parvorder of the cetaceans characterized by having teeth. The teeth differ considerably among the species. They may be numerous, with

some dolphins bearing over 100 teeth in their jaws. On the other hand, the narwhals have a giant unicorn-like tusk, which is a tooth containing millions of sensory pathways and used for sensing during feeding, navigation, and mating. It is the most neurologically complex tooth known. Beaked whales are almost toothless, with only bizarre teeth found in males. These teeth may be used for feeding but also for demonstrating aggression and showmanship.

Primates

[edit]

Main articles: Human tooth and Dental anatomy

In humans (and most other primates), there are usually 20 primary (also "baby" or "milk") teeth, and later up to 32 permanent teeth. Four of these 32 may be third molars or wisdom teeth, although these are not present in all adults, and may be removed surgically later in life.^[15]

Among primary teeth, 10 of them are usually found in the maxilla (i.e. upper jaw) and the other 10 in the mandible (i.e. lower jaw). Among permanent teeth, 16 are found in the maxilla and the other 16 in the mandible. Most of the teeth have uniquely distinguishing features.

Horse

[edit]

Main article: Horse teeth

An adult horse has between 36 and 44 teeth. The enamel and dentin layers of horse teeth are intertwined.^[16] All horses have 12 premolars, 12 molars, and 12 incisors.^[17] Generally, all male equines also have four canine teeth (called tushes) between the molars and incisors. However, few female horses (less than 28%) have canines, and those that do usually have only one or two, which many times are only


partially erupted.^[18] A few horses have one to four wolf teeth, which are vestigial premolars, with most of those having only one or two. They are equally common in male and female horses and much more likely to be on the upper jaw. If present these can cause problems as they can interfere with the horse's bit contact. Therefore, wolf teeth are commonly removed.^[17]

Horse teeth can be used to estimate the animal's age. Between birth and five years, age can be closely estimated by observing the eruption pattern on milk teeth and then permanent teeth. By age five, all permanent teeth have usually erupted. The horse is then said to have a "full" mouth. After the age of five, age can only be conjectured by studying the wear patterns on the incisors, shape, the angle at which the incisors meet, and other factors. The wear of teeth may also be affected by diet, natural abnormalities, and cribbing. Two horses of the same age may have different wear patterns.

A horse's incisors, premolars, and molars, once fully developed, continue to erupt as the grinding surface is worn down through chewing. A young adult horse will have teeth, which are 110–130 mm (4.5–5 inches) long, with the majority of the crown remaining below the gumline in the dental socket. The rest of the tooth will slowly emerge from the jaw, erupting about 3 mm (1/8 in) each year, as the horse ages. When the animal reaches old age, the crowns of the teeth are very short and the teeth are often lost altogether. Very old horses, if lacking molars, may need to have their fodder ground up and soaked in water to create a soft mush for them to eat in order to obtain adequate nutrition.

Proboscideans

[edit]



Section through the ivory tusk of a mammoth

Main article: Elephant ivory

Elephants' tusks are specialized incisors for digging food up and fighting. Some elephant teeth are similar to those in manatees, and elephants are believed to have undergone an aquatic phase in their evolution.

At birth, elephants have a total of 28 molar plate-like grinding teeth not including the tusks. These are organized into four sets of seven successively larger teeth which the elephant will slowly wear through during its lifetime of chewing rough plant material. Only four teeth are used for chewing at a given time, and as each tooth wears out, another tooth moves forward to take its place in a process similar to a conveyor belt. The last and largest of these teeth usually becomes exposed when the animal is around 40 years of age, and will often last for an additional 20 years. When the last of these teeth has fallen out, regardless of the elephant's age, the animal will no longer be able to chew food and will die of starvation.^[19]^[20]

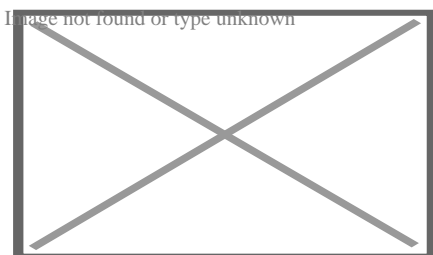
Rabbit

[edit]

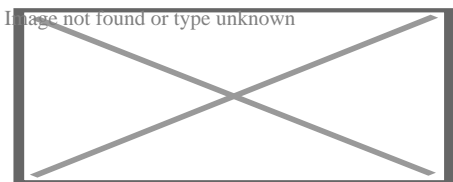
Rabbits and other lagomorphs usually shed their deciduous teeth before (or very shortly after) their birth, and are usually born with their permanent teeth.^[21] The

teeth of rabbits complement their diet, which consists of a wide range of vegetation. Since many of the foods are abrasive enough to cause attrition, rabbit teeth grow continuously throughout life.^[22] Rabbits have a total of six incisors, three upper premolars, three upper molars, two lower premolars, and two lower molars on each side. There are no canines. Dental formula is $\frac{2.0.3.3}{1.0.2.3} = 28$. Three to four millimeters of the tooth is worn away by incisors every week, whereas the cheek teeth require a month to wear away the same amount.^[23]

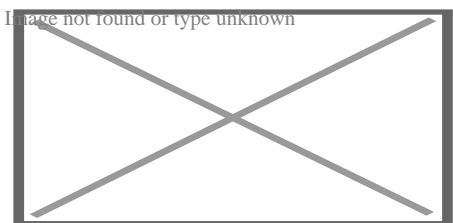
The incisors and cheek teeth of rabbits are called aradicular hypsodont teeth. This is sometimes referred to as an elodont dentition. These teeth grow or erupt continuously. The growth or eruption is held in balance by dental abrasion from chewing a diet high in fiber.



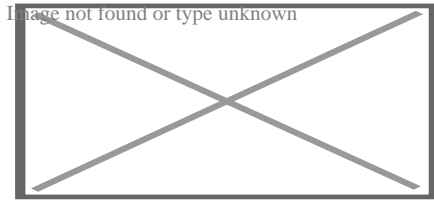
Buccal view of top incisor from *Rattus rattus*. Top incisor outlined in yellow. Molars circled in blue.



Buccal view of the lower incisor from the right dentary of a *Rattus rattus*



Lingual view of the lower incisor from the right dentary of a *Rattus rattus*




Midsagittal view of top incisor from *Rattus rattus*. Top incisor outlined in yellow. Molars circled in blue.

Rodents

[edit]

Rodents have upper and lower hypselodont incisors that can continuously grow enamel throughout its life without having properly formed roots.^[24] These teeth are also known as aradicular teeth, and unlike humans whose ameloblasts die after tooth development, rodents continually produce enamel, they must wear down their teeth by gnawing on various materials.^[25] Enamel and dentin are produced by the enamel organ, and growth is dependent on the presence of stem cells, cellular amplification, and cellular maturation structures in the odontogenic region.^[26] Rodent incisors are used for cutting wood, biting through the skin of fruit, or for defense. This allows for the rate of wear and tooth growth to be at equilibrium.^[24] The microstructure of rodent incisor enamel has shown to be useful in studying the phylogeny and systematics of rodents because of its independent evolution from the other dental traits. The enamel on rodent incisors are composed of two layers: the inner portio interna (PI) with Hunter–Schreger bands (HSB) and an outer portio externa (PE) with radial enamel (RE).^[27] It usually involves the differential regulation of the epithelial stem cell niche in the tooth of two rodent species, such as guinea pigs.^[28]^[29]



Lingual view of top incisor from *Rattus rattus*. Top incisor outlined in yellow. Molars circled in blue.

The teeth have enamel on the outside and exposed dentin on the inside, so they self-sharpen during gnawing. On the other hand, continually growing molars are found in some rodent species, such as the sibling vole and the guinea pig.^[28]^[29] There is variation in the dentition of the rodents, but generally, rodents lack canines and premolars, and have a space between their incisors and molars, called the diastema region.

Manatee

[edit]

Manatees are polyphyodont with mandibular molars developing separately from the jaw and are encased in a bony shell separated by soft tissue.^[30]^[31]

Walrus


[edit]

Main article: Walrus ivory

Walrus tusks are canine teeth that grow continuously throughout life.^[32]

Fish

[edit]



Teeth of a great white shark

See also: Pharyngeal teeth and Shark tooth

Fish, such as sharks, may go through many teeth in their lifetime. The replacement of multiple teeth is known as polyphyodontia.

A class of prehistoric shark are called cladodonts for their strange forked teeth.

Unlike the continuous shedding of functional teeth seen in modern sharks,^{[33][34]} the majority of stem chondrichthyan lineages retained all tooth generations developed throughout the life of the animal.^[35] This replacement mechanism is exemplified by the tooth whorl-based dentitions of acanthodians,^[36] which include the oldest known toothed vertebrate, *Qianodus duplicis*^[37].

Amphibians

[edit]

All amphibians have pedicellate teeth, which are modified to be flexible due to connective tissue and uncalcified dentine that separates the crown from the base of the tooth.^[38]

Most amphibians exhibit teeth that have a slight attachment to the jaw or acrodont teeth. Acrodont teeth exhibit limited connection to the dentary and have little enervation.^[39] This is ideal for organisms who mostly use their teeth for

grasping, but not for crushing and allows for rapid regeneration of teeth at a low energy cost. Teeth are usually lost in the course of feeding if the prey is struggling. Additionally, amphibians that undergo a metamorphosis develop bicuspid shaped teeth.^[40]

Reptiles

[edit]

The teeth of reptiles are replaced constantly throughout their lives. Crocodilian juveniles replace teeth with larger ones at a rate as high as one new tooth per socket every month. Once mature, tooth replacement rates can slow to two years and even longer. Overall, crocodilians may use 3,000 teeth from birth to death. New teeth are created within old teeth.^[41]

Birds


[edit]

Main article: Ichthyornis

A skull of Ichthyornis discovered in 2014 suggests that the beak of birds may have evolved from teeth to allow chicks to escape their shells earlier, and thus avoid predators and also to penetrate protective covers such as hard earth to access underlying food.^[42]^[43]

Invertebrates

[edit]




The European medicinal leech has three jaws with numerous sharp teeth which function like little saws for incising a host.

True teeth are unique to vertebrates,^[44] although many invertebrates have analogous structures often referred to as teeth. The organisms with the simplest genome bearing such tooth-like structures are perhaps the parasitic worms of the family Ancylostomatidae.^[45] For example, the hookworm *Necator americanus* has two dorsal and two ventral cutting plates or teeth around the anterior margin of the buccal capsule. It also has a pair of subdorsal and a pair of subventral teeth located close to the rear.^[46]

Historically, the European medicinal leech, another invertebrate parasite, has been used in medicine to remove blood from patients.^[47] They have three jaws (tripartite) that resemble saws in both appearance and function, and on them are about 100 sharp teeth used to incise the host. The incision leaves a mark that is an inverted Y inside of a circle. After piercing the skin and injecting anticoagulants (hirudin) and anaesthetics, they suck out blood, consuming up to ten times their body weight in a single meal.^[48]

In some species of Bryozoa, the first part of the stomach forms a muscular gizzard lined with chitinous teeth that crush armoured prey such as diatoms. Wave-like peristaltic contractions then move the food through the stomach for digestion.^[49]



The limpet rasps algae from rocks using teeth with the strongest known tensile strength of any biological material.

Molluscs have a structure called a radula, which bears a ribbon of chitinous teeth. However, these teeth are histologically and developmentally different from vertebrate teeth and are unlikely to be homologous. For example, vertebrate teeth develop from a neural crest mesenchyme-derived dental papilla, and the neural crest is specific to vertebrates, as are tissues such as enamel.^[44]

The radula is used by molluscs for feeding and is sometimes compared rather inaccurately to a tongue. It is a minutely toothed, chitinous ribbon, typically used for scraping or cutting food before the food enters the oesophagus. The radula is unique to molluscs, and is found in every class of mollusc apart from bivalves.

Within the gastropods, the radula is used in feeding by both herbivorous and carnivorous snails and slugs. The arrangement of teeth (also known as denticles) on the radula ribbon varies considerably from one group to another as shown in the diagram on the left.

Predatory marine snails such as the Naticidae use the radula plus an acidic secretion to bore through the shell of other molluscs. Other predatory marine snails, such as the Conidae, use a specialized radula tooth as a poisoned harpoon. Predatory pulmonate land slugs, such as the ghost slug, use elongated razor-sharp teeth on the radula to seize and devour earthworms. Predatory cephalopods, such

as squid, use the radula for cutting prey.

In most of the more ancient lineages of gastropods, the radula is used to graze by scraping diatoms and other microscopic algae off rock surfaces and other substrates. Limpets scrape algae from rocks using radula equipped with exceptionally hard rasping teeth.^[50] These teeth have the strongest known tensile strength of any biological material, outperforming spider silk.^[50] The mineral protein of the limpet teeth can withstand a tensile stress of 4.9 GPa, compared to 4 GPa of spider silk and 0.5 GPa of human teeth.^[51]

Fossilization and taphonomy

[edit]

Because teeth are very resistant, often preserved when bones are not,^[52] and reflect the diet of the host organism, they are very valuable to archaeologists and palaeontologists.^[53] Early fish such as the thelodonts had scales composed of dentine and an enamel-like compound, suggesting that the origin of teeth was from scales which were retained in the mouth. Fish as early as the late Cambrian had dentine in their exoskeletons, which may have functioned in defense or for sensing their environments.^[54] Dentine can be as hard as the rest of teeth and is composed of collagen fibres, reinforced with hydroxyapatite.^[54]


Though teeth are very resistant, they also can be brittle and highly susceptible to cracking.^[55] However, cracking of the tooth can be used as a diagnostic tool for predicting bite force. Additionally, enamel fractures can also give valuable insight into the diet and behaviour of archaeological and fossil samples.

Decalcification removes the enamel from teeth and leaves only the organic interior intact, which comprises dentine and cementine.^[56] Enamel is quickly decalcified in acids,^[57] perhaps by dissolution by plant acids or via diagenetic solutions, or in

the stomachs of vertebrate predators.^[56] Enamel can be lost by abrasion or spalling,^[56] and is lost before dentine or bone are destroyed by the fossilisation process.^[57] In such a case, the 'skeleton' of the teeth would consist of the dentine, with a hollow pulp cavity.^[56] The organic part of dentine, conversely, is destroyed by alkalis.^[57]

See also

[edit]

-  [Medicine portal](#)
- Animal tooth development
- Dragon's teeth (mythology)

References

[edit]

- ↑ **a b c** Romer, Alfred Sherwood; Parsons, Thomas S. (1977). *The Vertebrate Body*. Philadelphia, PA: Holt-Saunders International. pp. 300–310. ISBN 978-0-03-910284-5.
- ↑ Tummers M, Thesleff I (March 2003). "Root or crown: a developmental choice orchestrated by the differential regulation of the epithelial stem cell niche in the tooth of two rodent species". *Development*. **130** (6): 1049–57. doi:10.1242/dev.00332. PMID 12571097.
- ↑ Hunt AM (1959). "A description of the molar teeth and investing tissues of normal guinea pigs". *J. Dent. Res.* **38** (2): 216–31. doi:10.1177/00220345590380020301. PMID 13641521. S2CID 45097018.
- ↑ **a b** Nasoori, Alireza (2020). "Tusks, the extra-oral teeth". *Archives of Oral Biology*. **117**: 104835. doi:10.1016/j.archoralbio.2020.104835. PMID 32668361. S2CID 220585014.
- ↑ McCOLLUM, MELANIE; SHARPE, PAUL T. (July 2001). "Evolution and development of teeth". *Journal of Anatomy*. **199** (1–2): 153–159. doi:10.1046/j.1469-7580.2001.19910153.x. PMC 1594990. PMID 11523817.
- ↑ Kaplan, Matt (October 16, 2013). "Fossil scans reveal origins of teeth". *Nature*. doi:10.1038/nature.2013.13964 – via www.nature.com.

7. ^ Harper, Douglas (2001–2021). "tooth | Origin and meaning of tooth". *Online Etymology Dictionary*.
8. ^ Jheon, Andrew H (2012). "From molecules to mastication: the development and evolution of teeth". *Wiley Interdiscip Rev Dev Biol.* **2** (2): 165–182. doi:10.1002/wdev.63. PMC 3632217. PMID 24009032.
9. ^ Sharpe, P. T. (2001). "Fish scale development: Hair today, teeth and scales yesterday?". *Current Biology.* **11** (18): R751 – R752. Bibcode:2001CBio...11.R751S. doi:10.1016/S0960-9822(01)00438-9. PMID 11566120. S2CID 18868124.
10. ^ Jennifer Viegas (June 24, 2015). "First-known teeth belonged to fierce fish". *ABC Science*. Retrieved June 28, 2015.
11. ^ Shoshani 2002, p. 619
12. ^ Hale, FA (2009). "Dental caries in the dog". *Can. Vet. J.* **50** (12): 1301–4. PMC 2777300. PMID 20190984.
13. ^ "Types of Teeth, Dental Anatomy & Tooth Anatomy | Colgate®". *www.colgate.com*. Archived from the original on 2017-11-19. Retrieved 2017-11-19.
14. ^ "Common Characteristics Of Whale Teeth". Archived from the original on 4 September 2011. Retrieved 18 July 2014.
15. ^ "Everything you need to know about teeth". *NHS Scotland*. Retrieved 5 May 2020.
16. ^ "Gummed Out: Young Horses Lose Many Teeth, Vet Says". Archived from the original on 8 July 2014. Retrieved 6 July 2014.
17. ^ **a b** Patricia Pence (2002). *Equine Dentistry: A Practical Guide*. Baltimore: Lippincott Williams & Wilkins. ISBN 978-0-683-30403-9.
18. ^ Al Cirelli. "Equine Dentition" (PDF). *University of Nevada Reno*. SP-00-08. Retrieved 7 June 2010.
19. ^ Maurice Burton; Robert Burton (2002). *International Wildlife Encyclopedia*. Marshall Cavendish. p. 769. ISBN 978-0-7614-7266-7.
20. ^ Bram, L. et al. MCMLXXXIII. *Elephants*. Funk & Wagnalls New Encyclopedia, Volume 9, p. 183. ISBN 0-8343-0051-6
21. ^ "Dental Anatomy & Care for Rabbits and Rodents".
22. ^ Brown, Susan. Rabbit Dental Diseases Archived 2007-10-14 at the Wayback Machine, hosted on the San Diego Chapter of the House Rabbit Society Archived 2007-10-13 at the Wayback Machine. Page accessed April 9, 2007.

23. ^ Rydavy, Robin. Hay & Dental Health, hosted by the Missouri House Rabbit Society–Kansas City. Page accessed January 2, 2024.
24. ^ **a b** Cox, Philip; Hautier, Lionel (2015). *Evolution of the Rodents: Advances in Phylogeny, Functional Morphology and Development*. Cambridge University Press. p. 482. ISBN 9781107044333.
25. ^ Caceci, Thomas. *Veterinary Histology* with subtitle "Digestive System: Oral Cavity" found here Archived 2006-04-30 at the Wayback Machine.
26. ^ Gomes, J.r.; Omar, N.f.; Do Carmo, E.r.; Neves, J.s.; Soares, M.a.m.; Narvaes, E.a.; Novaes, P.d. (30 April 2013). "Relationship Between Cell Proliferation and Eruption Rate in the Rat Incisor". *The Anatomical Record*. **296** (7): 1096–1101. doi:10.1002/ar.22712. ISSN 1932-8494. PMID 23629828. S2CID 13197331.
27. ^ Martin, Thomas (September 1999). "Evolution of Incisor Enamel Microstructure in Theridomyidae (Rodentia)". *Journal of Vertebrate Paleontology*. **19** (3): 550. Bibcode:1999JVPal..19..550M. doi:10.1080/02724634.1999.10011164.
28. ^ **a b** Tummers M and Thesleff I. Root or crown: a developmental choice orchestrated by the differential regulation of the epithelial stem cell niche in the tooth of two rodent species. *Development* (2003). 130(6):1049–57.
29. ^ **a b** AM Hunt. A description of the molar teeth and investing tissues of normal guinea pigs. *J Dent Res*. (1959) 38(2):216–31.
30. ^ Shoshani, J., ed. (2000). *Elephants: Majestic Creatures of the Wild*. Checkmark Books. ISBN 0-87596-143-6.
31. ^ Best, Robin (1984). Macdonald, D. (ed.). *The Encyclopedia of Mammals*. New York: Facts on File. pp. 292–298. ISBN 0-87196-871-1.
32. ^ The Permanent Canine Teeth, hosted on the University of Illinois at Chicago website. Page accessed February 5, 2007.
33. ^ Underwood, Charlie; Johanson, Zerina; Smith, Moya Meredith (November 2016). "Cutting blade dentitions in squaliform sharks form by modification of inherited alternate tooth ordering patterns". *Royal Society Open Science*. **3** (11): 160385. Bibcode:2016RSOS....360385U. doi:10.1098/rsos.160385. ISSN 2054-5703. PMC 5180115. PMID 28018617. S2CID 12821592.
34. ^ Fraser, Gareth J.; Thiery, Alex P. (2019), Underwood, Charlie; Richter, Martha; Johanson, Zerina (eds.), "Evolution, Development and Regeneration of Fish Dentitions", *Evolution and Development of Fishes*, Cambridge: Cambridge University Press, pp. 160–171, doi:10.1017/9781316832172.010, ISBN 978-1-107-17944-8, S2CID 92225621, retrieved 2022-10-22

35. ^ Rücklin, Martin; King, Benedict; Cunningham, John A.; Johanson, Zerina; Marone, Federica; Donoghue, Philip C. J. (2021-05-06). "Acanthodian dental development and the origin of gnathostome dentitions". *Nature Ecology & Evolution*. **5** (7): 919–926. Bibcode:2021NatEE...5..919R. doi:10.1038/s41559-021-01458-4. hdl:1983/27f9a13a-1441-410e-b9a7-116b42cd40f7. ISSN 2397-334X. PMID 33958756. S2CID 233985000.
36. ^ Burrow, Carole (2021). *Acanthodii, Stem Chondrichthyes*. Verlag Dr. Friedrich Pfeil. ISBN 978-3-89937-271-7. OCLC 1335983356.
37. ^ Andreev, Plamen S.; Sansom, Ivan J.; Li, Qiang; Zhao, Wenjin; Wang, Jianhua; Wang, Chun-Chieh; Peng, Lijian; Jia, Liantao; Qiao, Tuo; Zhu, Min (September 2022). "The oldest gnathostome teeth". *Nature*. **609** (7929): 964–968. Bibcode:2022Natur.609..964A. doi:10.1038/s41586-022-05166-2. ISSN 1476-4687. PMID 36171375. S2CID 252569771.
38. ^ Pough, Harvey. *Vertebrate Life*. 9th Ed. Boston: Pearson Education, Inc., 2013. 211–252. Print.
39. ^ Kardong, Kenneth (1995). *Vertebrate: Comparative Anatomy, Function, Evolution*. New York: McGraw-Hill. pp. 215–225. ISBN 9780078023026.
40. ^ Xiong, Jianli (2014). "Comparison of vomerine tooth rows in juvenile and adult *Hynobius guabangshanensis*". *Vertebrate Zoology*. **64**: 215–220.
41. ^ Poole, D. F. G. (January 1961). "Notes on Tooth Replacement in the Nile Crocodile *Crocodilus niloticus*". *Proceedings of the Zoological Society of London*. **136** (1): 131–140. doi:10.1111/j.1469-7998.1961.tb06083.x.
42. ^ Hersher, Rebecca (May 2, 2018). "How Did Birds Lose Their Teeth And Get Their Beaks? Study Offers Clues". NPR.
43. ^ Field, Daniel J.; Hanson, Michael; Burnham, David; Wilson, Laura E.; Super, Kristopher; Ehret, Dana; Ebersole, Jun A.; Bhullar, Bhart-Anjan S. (May 31, 2018). "Complete Ichthyornis skull illuminates mosaic assembly of the avian head". *Nature* Vol 557, pp 96 – 100.
44. ^ **a b** Kardong, Kenneth V. (1995). *Vertebrates: comparative anatomy, function, evolution*. McGraw-Hill. pp. 55, 57. ISBN 978-0-697-21991-6.
45. ^ "Ancylostoma duodenale". *Nematode.net Genome Sequencing Center*. Archived from the original on 2008-05-16. Retrieved 2009-10-27.
46. ^ Roberts, Larry S., and John Janovy, Jr. *Foundations of Parasitology*. Seventh ed. Singapore: McGraw-Hill, 2006.

47. ^ Brian Payton (1981). Kenneth Muller; John Nicholls; Gunther Stent (eds.). *Neurobiology of the Leech*. New York: Cold Spring Harbor Laboratory. pp. 27–34. ISBN 978-0-87969-146-2.
48. ^ Wells MD, Manktelow RT, Boyd JB, Bowen V (1993). "The medical leech: an old treatment revisited". *Microsurgery*. **14** (3): 183–6. doi:10.1002/micr.1920140309. PMID 8479316. S2CID 27891377.
49. ^ Ruppert, E.E.; Fox, R.S.; Barnes, R.D. (2004). "Lophoporata". *Invertebrate Zoology* (7 ed.). Brooks / Cole. pp. 829–845. ISBN 978-0-03-025982-1.
50. ^ a b Asa H. Barber; Dun Lu; Nicola M. Pugno (18 February 2015), "Extreme strength observed in limpet teeth", *Journal of the Royal Society Interface*, **12** (105): 20141326, doi:10.1098/rsif.2014.1326, PMC 4387522, PMID 25694539
51. ^ Zachary Davies Boren (18 February 2015). "The strongest materials in the world: Limpet teeth beats record resistance of spider silk". *The Independent*. Retrieved 20 February 2015.
52. ^ *Taphonomy: A Process Approach*. Ronald E. Martin. Illustrated edition. Cambridge University Press, 1999. ISBN 978-0-521-59833-0
53. ^ Towle, Ian; Irish, Joel D.; De Groot, Isabelle (2017). "Behavioral inferences from the high levels of dental chipping in *Homo naledi*". *American Journal of Physical Anthropology*. **164** (1): 184–192. doi:10.1002/ajpa.23250. PMID 28542710. S2CID 24296825. Retrieved 2019-01-09.
54. ^ a b Teaford, Mark F and Smith, Moya Meredith, 2007. *Development, Function and Evolution of Teeth*, Cambridge University Press. ISBN 978-0-521-03372-5, Chapter 5.
55. ^ Lee, James J.-W.; Constantino, Paul J.; Lucas, Peter W.; Lawn, Brian R. (2011-11-01). "Fracture in teeth—a diagnostic for inferring bite force and tooth function". *Biological Reviews*. **86** (4): 959–974. doi:10.1111/j.1469-185x.2011.00181.x. ISSN 1469-185X. PMID 21507194. S2CID 205599560.
56. ^ a b c d Fisher, Daniel C (1981). "Taphonomic Interpretation of Enamel-Less Teeth in the Shotgun Local Fauna (Paleocene, Wyoming)". *Museum of Paleontology Contributions, the University of Michigan*. **25** (13): 259–275. hdl:2027.42/48503.
57. ^ a b c Fernandez-Jalvo, Y.; Sanchez-Chillon, B.; Andrews, P.; Fernandez-Lopez, S.; Alcalá Martínez, L. (2002). "Morphological taphonomic transformations of fossil bones in continental environments, and repercussions on their chemical composition" (PDF). *Archaeometry*. **44** (3): 353–361. doi:10.1111/1475-4754.t01-1-00068.

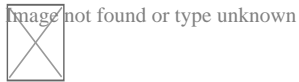
Sources

[edit]

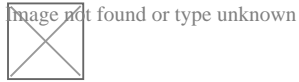
- *Shoshani, Jeheskel (2002). "Tubulidentata". In Robertson, Sarah (ed.). Encyclopedia of Life Sciences. Vol. 18: Svedberg, Theodor to Two-hybrid and Related Systems. London, UK: Nature Publishing Group. ISBN 978-1-56159-274-6.*

External links

[edit]



Wikimedia Commons has media related to ***tooth***.



Look up ***tooth*** in Wiktionary, the free dictionary.

- *Beach, Chandler B., ed. (1914). "Teeth" . The New Student's Reference Work . Chicago: F. E. Compton and Co.*

- Germany
- United States
- France

Authority control databases: National

Image not found or type unknown
Edit this at Wikidata

- BnF data
- Japan
- Czech Republic
- Israel

Check our other pages :

- [Comparing Ceramic Brackets With Other Invisible Options](#)
- [Social Changes That Encourage Adult Orthodontics](#)
- [Overcoming Hesitations About Braces Later in Life](#)

- [Integrating Prosthodontics for Full Mouth Rehabilitation](#)
- [Coordinating Orthodontic Work With Restorative Dentistry](#)

IQDENT – Ortodontska Klinika

Phone : +385953817015

City : Zagreb

State : Hrvatska

Zip : 10000

Address : IQDENT – Ortodontska Klinika

Company Website : <https://iqdent.hr/>

USEFUL LINKS

[Orthodontic treatment can help improve your child's smile](#)

[Orthodontic treatment for children](#)

[Sitemap](#)

[Privacy Policy](#)

[About Us](#)

Follow us